

# Prof. Giovanni Zucchelli's technique for the treatment of gingival recession

## TECHNICAL INFORMATION

Straumann® Emdogain® and mucoderm®

Surgical Guide

soft tissue

education

hard tissue

"The adjunctive use of Emdogain® and mucoderma® with the Coronally Advanced Flap can improve the quality of attachment between the soft tissue and the root and increase soft tissue thickness.

Both these factors are critical for the long-term stability of root coverage outcome."

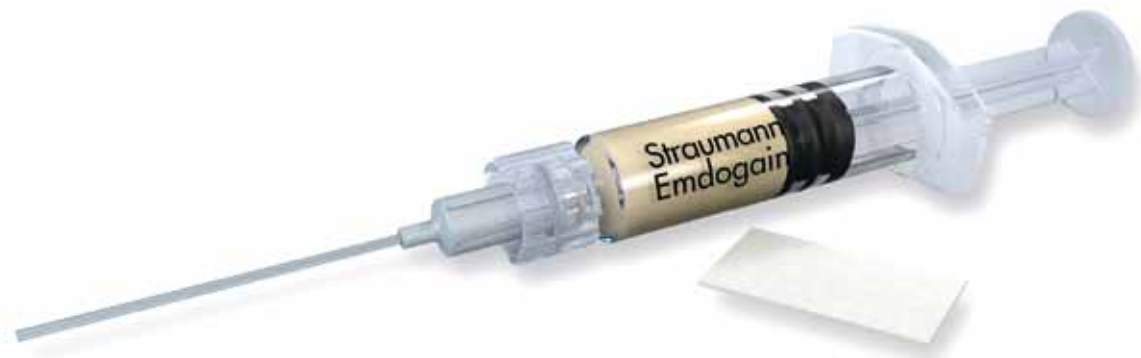**Prof. Dr. Giovanni Zucchelli**

Prof. Dr. Giovanni Zucchelli

- Professor in Periodontology at the University of Bologna, Italy.
- PhD in Medical Biotechnology applied to Dentistry.
- Active member of the European Academy of Esthetic Dentistry, Italian Society of Periodontology, Italian Society of Osseointegration, the European Federation of Periodontology and the American Academy of Periodontology.
- Associate editor and member of the editorial board of the International Journal of Esthetic Dentistry and member of the Editorial Board of the International Journal of Periodontics and Restorative Dentistry.
- Winner of scientific prizes for research in periodontology in Italy, USA and Europe.
- Author of more than 100 scientific publications in the field of periodontology.
- Co-author of two illustrated textbooks on periodontal plastic surgery (Ed. Martina) and of the chapter "Mucogingival Therapy-Periodontal Plastic Surgery" in Jan Lindhe's textbook on "Clinical Periodontology and Implant Dentistry" (Ed. Wiley-Blackwell).
- Author of the book "Mucogingival esthetic surgery" (Ed. Quintessence).

## Straumann® Emdogain® and mucoderm®:

Making root coverage procedures  
more tolerable for your patients



Gingival recession around teeth and soft tissue dehiscence around dental implants are common grounds for dissatisfaction among patients. Exposure during smiling or function of portions of the root or implant surface are the main indications for surgical coverage procedures. Generally, only the most coronal millimeter(s) of the recession is/are exposed during smiling or function, therefore the presence and/or the persistence of a shallow recession after therapy may be a problem for the patient. Thus, the goal is complete root or implant coverage when patients are dissatisfied with the aesthetic appearance of their teeth or implant(s).

Prof. Zucchelli's technique for the treatment of single and multiple recession defects affecting adjacent teeth in patients with aesthetic demands has been shown to achieve complete root coverage in most patients, irrespective of the number of recessions treated in each intervention.

## Prof. Giovanni Zucchelli's technique – the rationale

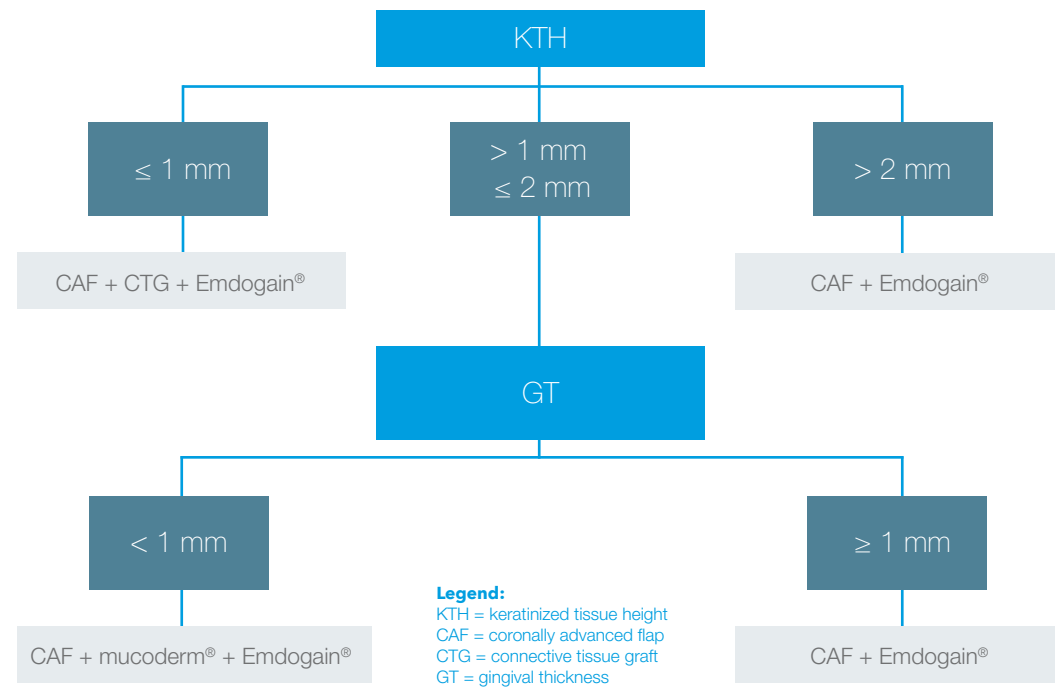
The coronally advanced flap (CAF) is the most documented root coverage procedure for single<sup>1</sup> and multiple<sup>2</sup> recession defects. It is safe and can achieve coverage of the root exposure with soft tissue that does not differ from the adjacent soft tissue in terms of color, texture or surface characteristics. Thus it is also the most aesthetic root coverage surgical procedure. Recently the CAF has been also applied to the treatment of gingival recession located in areas with more complex mucogingival situations like lower incisors<sup>3</sup> and molars<sup>4</sup>.

The quality of attachment between the soft tissue and the root surface has always been a matter of debate among researchers and clinicians because of the limited availability of human histological data. Certain clinical aspects related to the surgical procedure may influence the quality of attachment<sup>5</sup>:

- The tight adaptation of the keratinized tissue of the flap to the convexity of the clinical crown may prevent blood from seeping out of the wound area at the end of the surgery. This is critical for blood clot formation and stabilization between the coronally advanced soft tissue and the root surface.
- The application of Straumann® PrefGel® to the root surface removes the smear layer inside the dentinal tubules, thereby exposing the collagen fibrils of the dentinal tubules and facilitating their interaction with the fibrin net. This is called blood clot adhesion, which is the first step in blocking apical downgrowth of epithelium.
- The use of Straumann® Emdogain® (Enamel matrix derivative) on the root surface allows cells of the blood clot to differentiate into cementoblasts and fibroblasts and thus improve the connective tissue attachment between the root and the soft tissue.

The root coverage efficacy and long-term stability of the CAF are primarily influenced by the height of keratinized tissue (KTH) remaining apical to the root exposure and secondarily by gingival thickness (GT).

# Decision-making process in the treatment of gingival recession



When the KTH is greater than 2 mm the CAF in combination with Emdogain® is the technique of choice. Emdogain® improves root coverage<sup>6,7</sup>, increases KTH with respect to CAF alone<sup>7</sup> and improves the quality of attachment<sup>8</sup> (connective tissue attachment with respect to junctional epithelium).

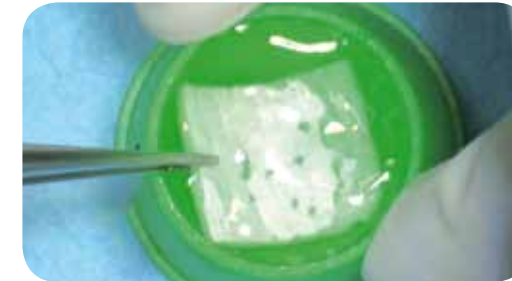
When the KTH is greater than 1 mm but less than or equal to 2 mm, it is critical to measure GT. If GT is equal to or greater than 1 mm CAF + Emdogain® is still indicated. When GT is less than 1 mm it is necessary to increase the thickness of the soft tissue. This can be achieved by adding a collagen matrix, botiss mucoderm®, to the CAF. mucoderm® will support blood clot stabilization by serving as a scaffold for ingrowing blood vessels and fibroblasts. Within a few months the matrix will be completely degraded and the blood clot will be transformed into new connective tissue, which will be responsible for the increase in soft tissue thickness. This is critical for the long-term success of root coverage.

When the KTH is 1 mm or less we need to improve the stability of the CAF at the time of the surgery. Thus a connective tissue graft (CTG) applied at the level of the cemento-enamel junction (CEJ) has to be added to prevent shrinkage of the coronally advanced flap. The recent improvement in the surgical management of the CAF procedure has helped reduce both the apical coronal dimension and the thickness of the CTG<sup>9</sup>. This reduces patient discomfort and improves the post-operative outcome<sup>10</sup>.

The use of Emdogain® with the CAF + mucoderm® and CAF + CTG remains indicated to improve the quality of attachment between the soft tissue and the root<sup>8</sup> – this is especially indicated in the presence of large root exposure and buccally dislocated root<sup>5</sup> – and to improve the wound healing and post-operative comfort of the patient.

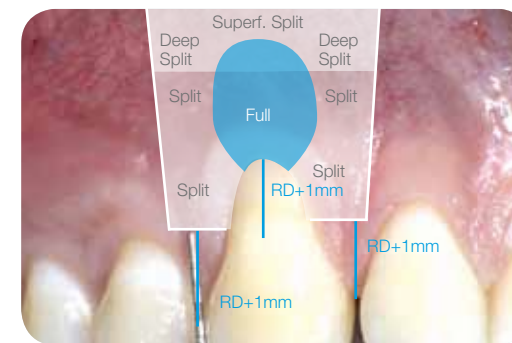
## STEP BY STEP PROCEDURE

Treatment of a Class I gingival recession with Prof. Zucchelli's coronally advanced flap technique in combination with Straumann® Emdogain® and mucoderm®



### Step 1 - Soak mucoderm®

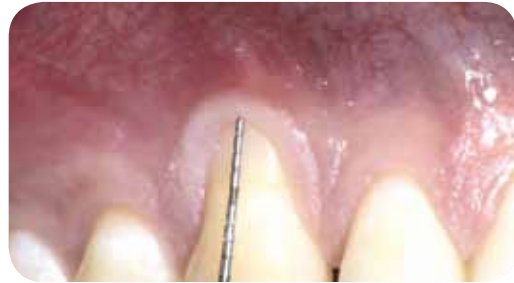Place mucoderm® in sterile saline solution and set it aside to soak until you need it (10-20 minutes).



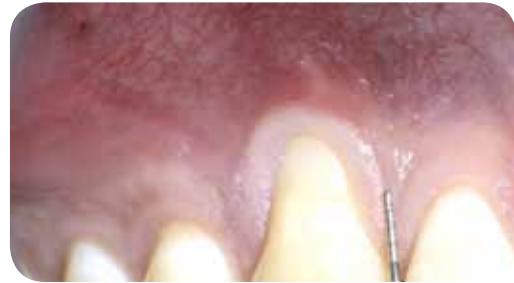
### Step 2 - Plan the incisions of the trapezoidal flap

RD = recession depth  
 Split = split thickness flap  
 Full = full thickness flap  
 Superf. Split = superficial split thickness flap  
 Deep Split = deep split thickness flap

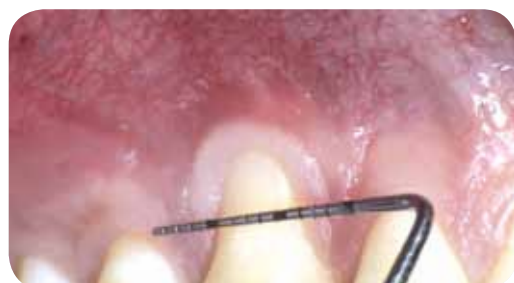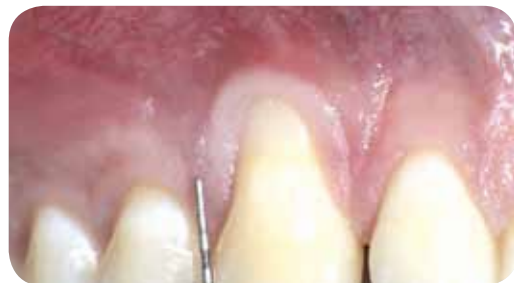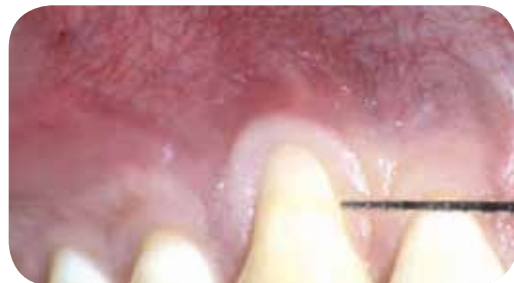## STEP BY STEP PROCEDURE



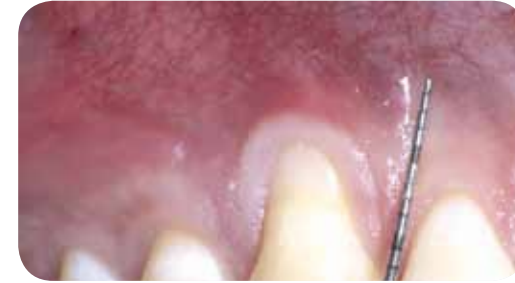
Measure the recession defect (RD), i.e. the distance from the most apical aspect of the recession to the cemento-enamel junction.



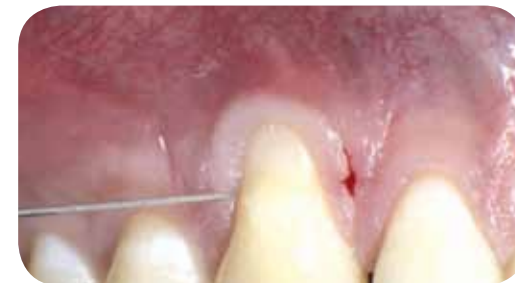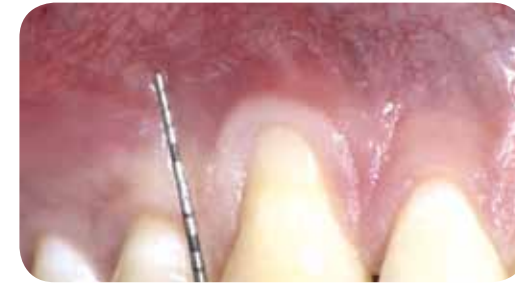Measure RD+1 mm from the tip of both papillae: this is the level where the horizontal incisions will be made. Both horizontal incisions are imaginary lines which extend 3 mm from the soft tissue margin and connect the soft tissue margin to the vertical releasing incision. Use a probe to visualize the horizontal incisions.



## STEP BY STEP PROCEDURE

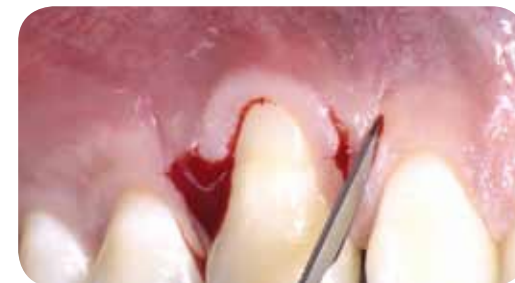

Use a probe to visualize where the vertical releasing incisions will be made.

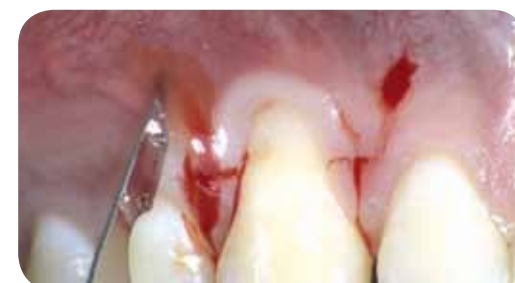

### Step 3 - Elevate the flap

Make the horizontal incisions, mesially and distally to the affected tooth.

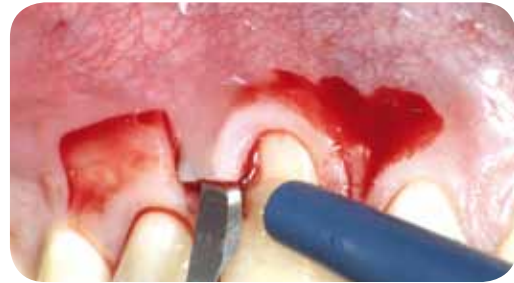

Extend the vertical releasing incisions in the alveolar mucosa. These incisions should be as short as possible to avoid scar formation. To this end, start from the intersection with the horizontal incision and extend vertically until the type of bleeding changes (which happens when you reach the submucosal tissue), then stop.

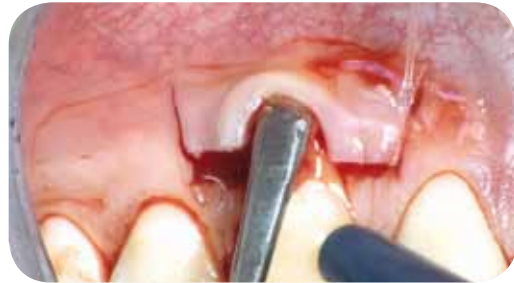



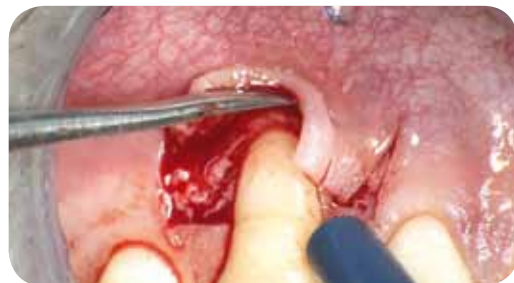**STEP BY STEP PROCEDURE**



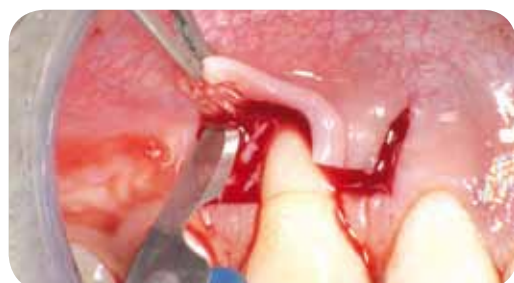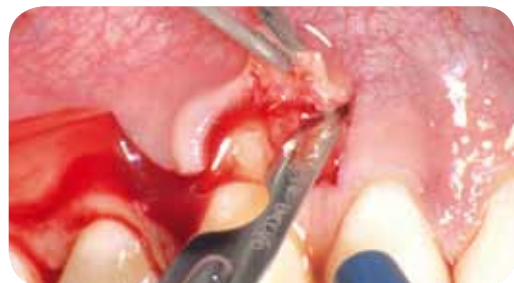Elevate the surgical papillae with split thickness. They should have a uniform thickness, which is the thickness of the epithelium and the connective tissue. To do this, use a blade to elevate the mesial corner of a given papilla and then its distal corner, and then go with the blade from one corner of the surgical papilla to the other.



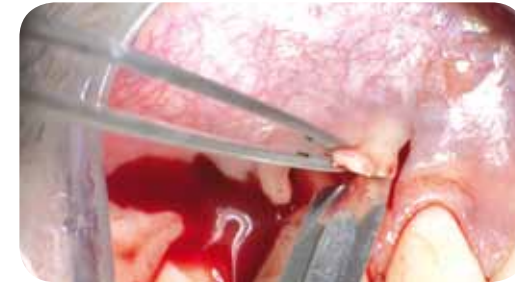
The soft tissue apical to the root exposure is elevated full thickness inserting a small periosteal elevator into the probeable sulcus and proceeding in the apical direction up to exposing 2-3 mm of bone apical to the bone dehiscence. This is done in order to include the periosteum in the thickness of that central portion of the flap covering the avascular root exposure.



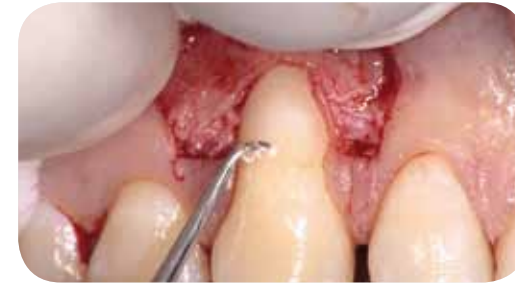The vertical releasing incisions should be elevated split thickness keeping the blade parallel to the bone, thus leaving the periosteum to protect the underlying bone in the lateral areas of the flap.



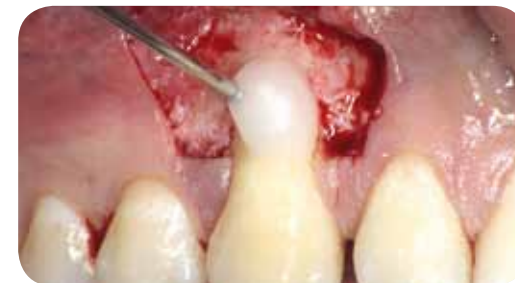**STEP BY STEP PROCEDURE**



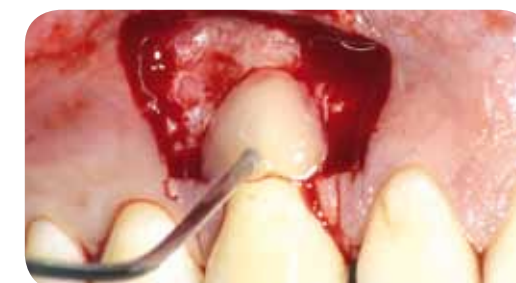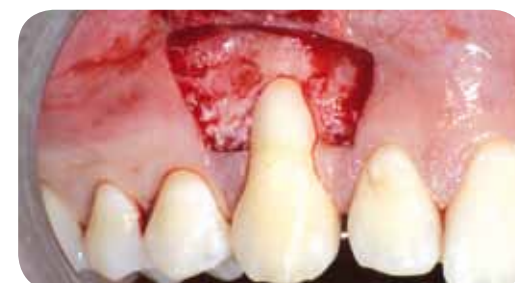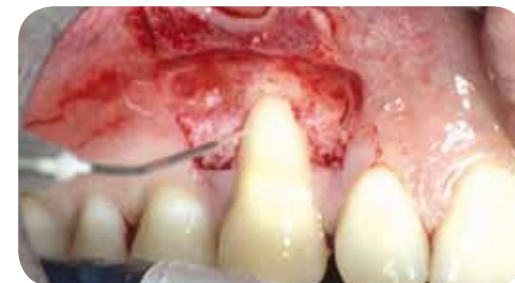Mobilize the flap with superficial incisions, holding the blade parallel to the mucosal surface. The goal is to cut all muscular structures and remove them from the lying mucosa of the lip.



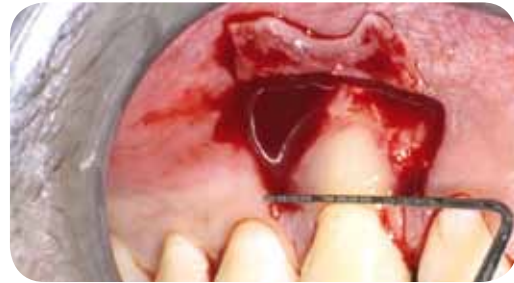**Step 4**  
Perform root planing only on the areas corresponding to pre-operative probing pocket depth and gingival recession.



**Step 5 - Apply PrefGel® and Emdogain®**  
- Apply Straumann® PrefGel® to the entire root surface and leave for 2 minutes.  
- Rinse abundantly for 1 minute.  
- Apply Straumann® Emdogain® to the entire blood-free root surface.

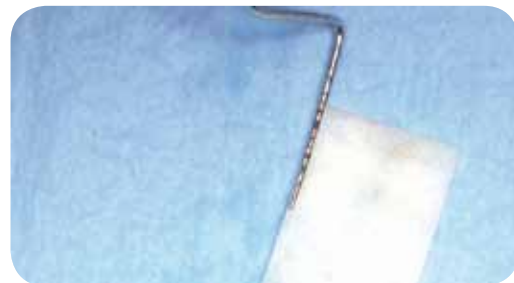
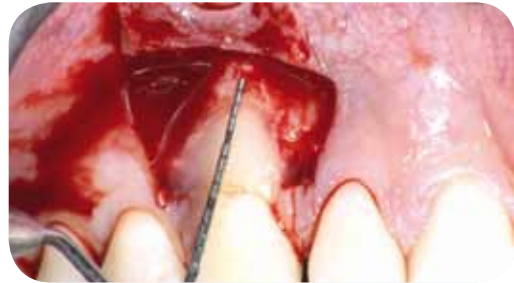
## STEP BY STEP PROCEDURE



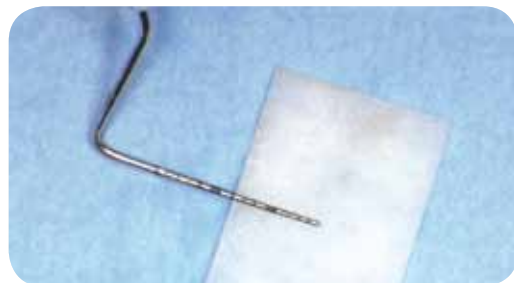
### Step 6 - Trim mucoderm®

Take measurements to establish the dimensions of the required collagen matrix. The width of the matrix should be 6 mm more than the recession width measured at the cemento-enamel junction (CEJ). The height should be 3 mm more than the depth of the root exposure.

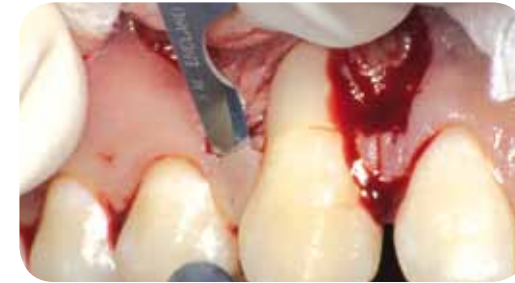

Trim the rehydrated mucoderm® using a blade or scissors.

**Remark:** the edges of mucoderm® may also be smoothed to prevent possible damage of the gingival tissue during flap closure.

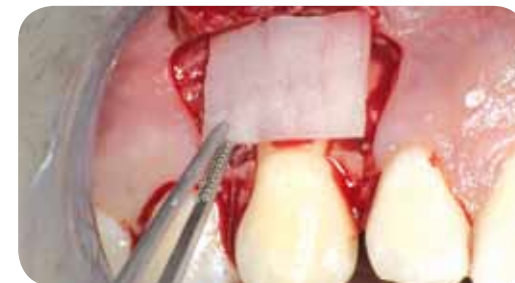
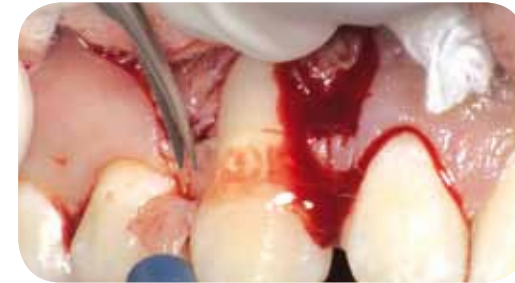
## STEP BY STEP PROCEDURE



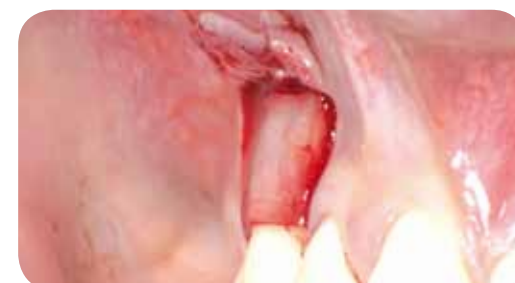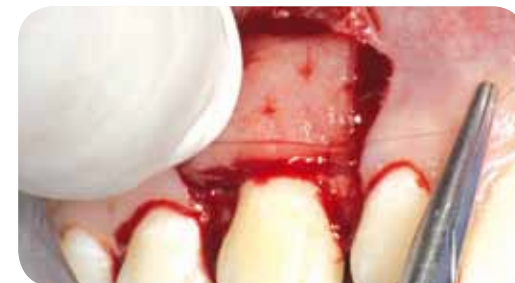### Step 7 - De-epithelialize the anatomic papillae to create a connective tissue bed where the surgical papillae will be anchored with the sling sutures

- Create a regular connective tissue surface at the base of the papilla using a blade to cut away the epithelium.
- Use microsurgical scissors, following the surface that was previously prepared by the blade, to cut away the epithelium from the tip of the papilla.
- Repeat on the other side.



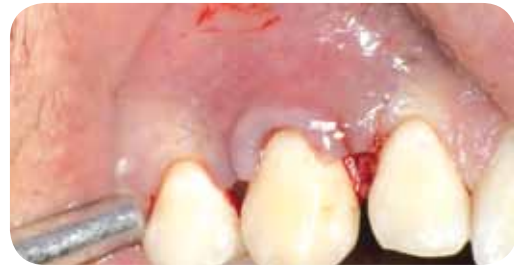### Step 8 - Apply and suture mucoderm® in place

- Apply mucoderm® in situ. The matrix should be positioned 1 mm coronal to the CEJ and 2 mm apically with respect to the buccal bone crest.
- Suture the mucoderm® in place with 2 interrupted sutures (PGA 7-0) at the base of the de-epithelialized anatomic papillae. mucoderm® should always be stabilized to avoid micromovement and to ensure undisturbed revitalization.



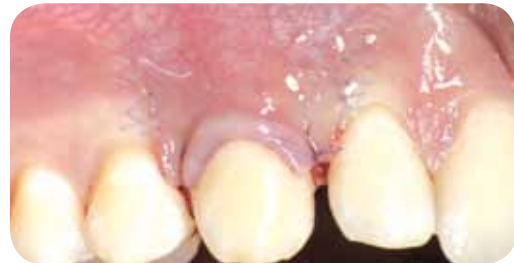

## STEP BY STEP PROCEDURE



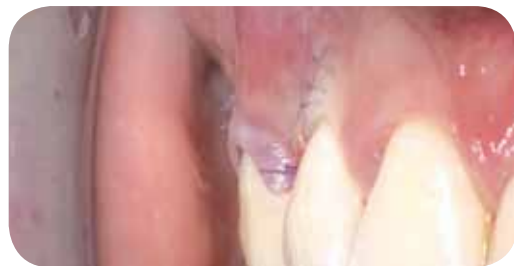### Step 9 - Suture the flap

- Hold the surgical papilla in place above the anatomic papilla with anatomical tweezers and make a series of single interrupted sutures along the vertical releasing incisions with 7-0 PGA sutures, starting at the most apical point and making sure the knots are placed along the vertical releasing incisions to ensure tight adaptation. Start placing the sutures on the mesial side of the flap, then proceed to suture the distal side of the flap.



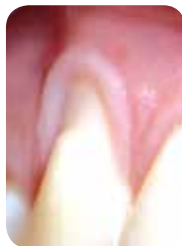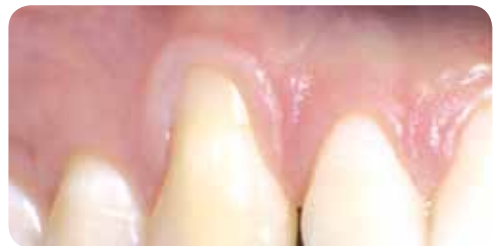- Suture the papillae in place using a sling suture, with the knot on the mesial papilla.

- Make sure no blood is seeping out of the flap. Check the patient again about 40 minutes after the end of the surgery. If blood is seeping out, perform an additional sling suture, this time placing the knot on the distal papilla.

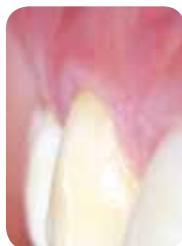
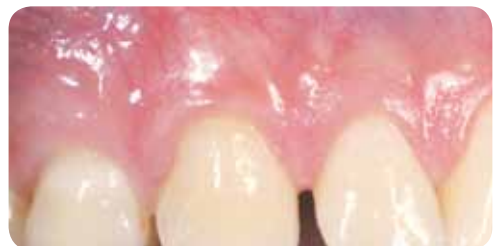
A complete flap reposition over mucoderm® is of utmost importance in order to ensure its revitalization.

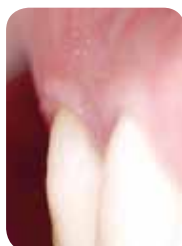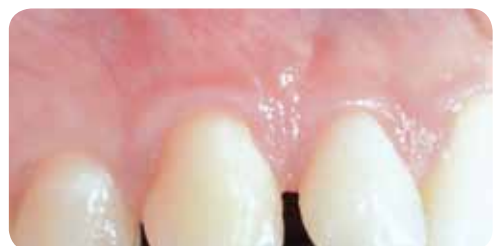## BEFORE AND AFTER



Before the surgery



1 year after the surgery

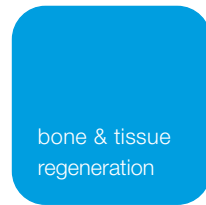

3 years after the surgery

## References

- 1 De Sanctis M, Zucchelli G. (2007). Coronally advanced flap: a modified surgical approach for isolated recession-type defects: three-year results. *J Clin Periodontol*. 2007 vol. 34, p. 262-268
- 2 Zucchelli G, De Sanctis M (2000). Treatment of multiple recession type defects in patients with aesthetic demands. *J Periodontol*, 2000 vol. 71, p. 1506-1514
- 3 Zucchelli G, Marzadori M, Mounssif I, Mazzotti C, Stefanini M (2014). Coronally advanced flap + connective tissue graft techniques for the treatment of deep gingival recession in the lower incisors. A controlled randomized clinical trial. *J Clin Periodontol*, 2014 vol. 41, p. 806-813
- 4 Zucchelli G, Marzadori M, Mele M, Stefanini M, Montebugnoli L (2012). Root coverage in molar teeth: a comparative controlled randomized clinical trial. *J Clin Periodontol*, 2012 vol. 39, p. 1082-1088
- 5 Zucchelli G (2011) *Mucogingival esthetic surgery*. Quintessence ed.
- 6 Tonetti MS, Jepsen S. (2014) Working Group 2 of the European Workshop on Periodontology. Clinical efficacy of periodontal plastic surgery procedures: consensus report of Group 2 of the 10th European Workshop on Periodontology. *J Clin Periodontol*. 2014 Apr;41 Suppl 15:S36-43
- 7 Pilloni A, Paolantonio M, Camargo PM. (2006) Root coverage with a coronally positioned flap used in combination with enamel matrix derivative: 18-month clinical evaluation. *J Periodontol*. 2006 Dec;77(12):2031-9.
- 8 McGuire MK, Scheyer ET, Schupbach p. (2016) A Prospective, Case-Controlled Study Evaluating the Use of Enamel Matrix Derivative on Human Buccal Recession Defects: A Human Histologic Examination. *J Periodontol*. 2016 Jun;87(6):645-53.
- 9 Zucchelli G, Mounssif I, Mazzotti C, Montebugnoli L, Sangiorgi M, Mele M, Stefanini M (2014). Does the dimension of the graft influence patient morbidity and root coverage outcomes? A randomized controlled clinical trial. *J Clin Periodontol*, 2014 vol. 41, p. 708-716
- 10 Zucchelli G, Mele M, Stefanini M, Mazzotti C, Marzadori M, Montebugnoli L (2010). Patient morbidity and root coverage outcome after subepithelial connective tissue and de-epithelialized grafts: a comparative randomized-controlled clinical trial. *J Clin Periodontol* 2010, vol. 37, p. 728-738





# Innovation. Regeneration. Aesthetics.

soft tissue

education

hard tissue

International Headquarters  
Institut Straumann AG  
Peter Merian-Weg 12  
CH-4002 Basel  
Switzerland

Phone +41 (0)61 965 11 11  
Fax +41 (0)61 965 11 01

[www.straumann.com](http://www.straumann.com)

botiss biomaterials GmbH  
Hauptstr. 28  
15806 Zossen  
Germany

Tel.: +49 33769 / 88 41 985  
Fax: +49 33769 / 88 41 986

[www.botiss.com](http://www.botiss.com)  
[www.botiss-dental.com](http://www.botiss-dental.com)  
facebook: [botissdental](https://www.facebook.com/botissdental)