



maxgraft[®] bonebuilder

Patient-customized allogenic bone block

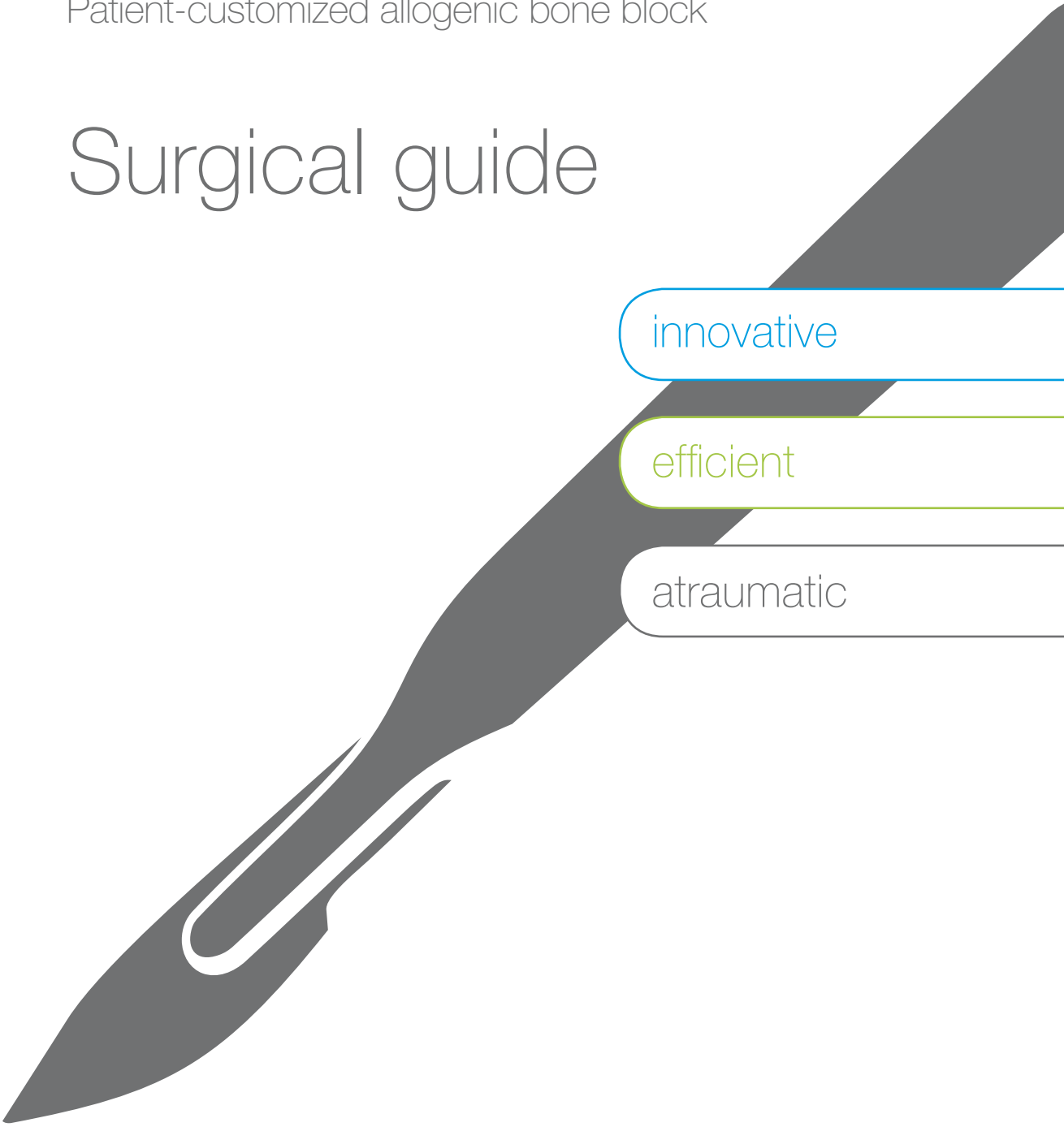
Surgical guide

innovative

efficient

atraumatic

hard tissue



About this guide

This surgical guide provides clinically based information for the correct handling and application of **maxgraft® bonebuilder**. It was created with the support of renowned clinical experts to assist you in achieving the best possible results.

On the following pages, you will find detailed information about the planning process and the surgical procedure, including tips for proper soft tissue management. Clinical cases from experienced surgeons highlight the main indications and individual surgical steps.

In every clinical situation, proper handling (according to the Instructions For Use) and application of **maxgraft® bonebuilder** are the responsibilities of the treating clinician(s).

Patient-customized allogenic bone block

maxgraft® bonebuilder is a patient-customized allogenic bone block for two-stage alveolar ridge augmentation. Based on CT/CBCT scans of the patient, the bone block is virtually designed using the latest 3D-CAD/CAM (computer-aided design/computer-aided manufacturing) technology. The final product is then milled from processed cancellous bone blocks originating from living human donors (explantation of femoral heads during hip endoprosthesis surgery).

In clinical practice, the application of allogenic blocks has been established as a reliable alternative to autogenous bone blocks for alveolar ridge augmentation,^{1,2,3} to avoid donor site morbidity and limitations in material quantity.⁴

maxgraft® bonebuilder offers greater precision and accuracy of fit compared to classical block augmentation. Manual adjustment of the block during the operation becomes unnecessary as **maxgraft® bonebuilder** may be applied directly onto the defect, reducing surgery time as well as risk of infection.⁵ The individual design provides a precise fit between local bone and the allogenic bone block, enabling rapid revascularization and fast graft incorporation.

Indications

Implantology — Oral surgery — CMF surgery

maxgraft® bonebuilder is implanted to replace missing or inadequate bone tissue, or for filling or stabilizing bone defects.

Main indications include:

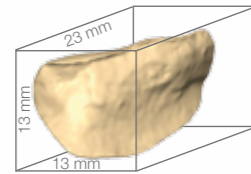
- Three dimensional (horizontal and/or vertical) alveolar ridge augmentation (block augmentation)
- Sinus augmentation

Contraindications

Bacterial infection of the oral cavity

Product properties and specifications

- Patient-customized, processed allograft (from selected living donors)
- Mineralized human collagen for excellent biocompatibility and flexibility
- Stable trabecular structure of the cancellous bone enables rapid revascularization
- Osteoconductive properties support natural and controlled bone remodeling
- Max. dimensions 23 x 13 x 13 mm



In cases with multiple or larger defects, several blocks can be designed and used.

Art.-No.	Content
PM1a	Individual planning and production of a bone block max. dimensions 23 x 13 x 13 mm
PM1a2	additional block(s) for the same patient

bonebuilder dummy

An individual 3D-model of the patient's defect, including the planned maxgraft® bonebuilder block(s) printed in synthetic filament, can be ordered together with the maxgraft® bonebuilder and delivered beforehand. The user-friendly demo material helps to inform the patient and supports preoperative planning (e.g., orientation and positioning of the block, placement of screws).

Art.-No.	Content
32100	Individual 3D printed model of the patient's defect including the planned maxgraft® bonebuilder block(s) for demonstration purposes, material: food-safe synthetic filament



Use of maxgraft® bonebuilder in conjunction with other bone substitute materials and biomaterials

For Guided Bone Regeneration (GBR) procedures a variety of different bone substitute materials are available. Allogenic particulated material (e.g., maxgraft® granules) with its preserved human collagen provides excellent osteoconductive properties, enabling complete bone remodeling. It is recommended in cases where residual volume needs to be filled during the augmentation procedure with maxgraft® bonebuilder. However, other materials or mixtures of different materials (e.g., bovine or synthetic biomaterials) can also be used for defect contouring. The final decision depends on the defect morphology and preferences of the patient and surgeon.

For GBR procedures, the use of barrier membranes is of utmost importance.⁶ Resorbable collagen membranes act as temporary barriers against ingrowth of fast proliferating fibroblasts and epithelium into the defect, maintaining the space for controlled bone regeneration. In combination with maxgraft® bonebuilder, the use of Jason® membrane – a pericardium membrane that provides a naturally long barrier function – is recommended.

PRF processing

The use of platelet-rich-fibrin (PRF) matrices – derived preoperatively from patient's blood – are recommended as they may enhance soft tissue healing, maturation of bone grafts and aesthetic results of soft tissues.⁷



Individual planning and ordering

maxgraft® bonebuilder is planned in close interaction between clinical users and botiss CAD-designers with multiple feedback loops to ensure a perfect fit. Communication is mainly done via email using the comment section on the specific order web page.

How do I order maxgraft® bonebuilder?

1. Register (create a new account) on www.botiss-bonebuilder.com

Log In – Create a new account – Enter a username, email address and postal address

Click on the button 'Log In' – 'Create a new account' and enter a username and a frequently used email address, as all communication with the botiss CAD-designers regarding the individual planning and notifications for your specific order will be done through this channel.

2. Create a new order and upload the patient data

After registration and creating a user account, you can upload the patient CT/CBCT data on the botiss server by clicking on the button 'New Order'. All radiological data must be unlinked from single-frame data images. The only file type suitable for 3D planning is DICOM (.dcm).

DICOM DATA EXPORT

If you are exporting your own data, you can find examples on how to export from a variety of different scanner software in the 'Help' – 'Downloads' section on www.botiss-bonebuilder.com.

There you can also find detailed information about the correct scan quality and format in case you refer your patient to external radiologists.

Please check the successful export by using a free DICOM-Viewer software (e.g. XNView/xnview.de) before uploading to avoid any delays in planning caused by defective data.

DATA COMPRESSION

All patient data must be uploaded as a .zip or .rar file.

Save the CT/CBCT data in one folder on your local computer and compress this folder (for Windows: right click – send to zip file, for Mac: right click – compress) before uploading.

IMPORTANT: Please provide a short comment with your order, e.g., intended location of maxgraft® bonebuilder (designated teeth, implant type, implant length/diameter etc.) in the comment section. You can also upload screenshots of your implant planning for more detailed information on your treatment plan, helping our CAD-designers with planning.

Please confirm your upload by clicking on the 'Save' button at the end of the page.

Data requirements:

- Recommended layer thickness 0.3 mm
- Removable, metalliferous dentures must be removed – artefacts can lead to inaccurate planning
- Unlinked, single-frame data images in output format DICOM (.dcm)

Addenda for CT data: Only axial images, no sagittal images

Timing of CT/CBCT scans

For 3D planning, the most current patient scan needs to be used to achieve the best possible outcome. In patients with fresh extraction sites we recommend waiting for wound healing (at least two to three months) before generating a new scan due to tissue dynamics.

More information and instructions can be found in the 'Help' section on www.botiss-bonebuilder.com. The botiss CAD-designers support the upload via telephone: + 49 (0)30 20 60 73 98 -35 / -26 or via email: bonebuilder@botiss.com.

3. Reconstruction of the patient's bone defect and block design

botiss virtually designs the patient-customized allogenic bone block based on the CT/CBCT scan using a 3D-planning software in interaction with the clinician. The designed bone block is matched to fit precisely onto the defect, creating sufficient bone volume for stable implant placement.

Technical limitations

Technical limitations may be based on poor data quality (e.g., artefacts which undermine a precise planning) or inaccurate transition between hard and soft tissue. The milling machine cannot create undercuts. Additionally, a minimum wall thickness of 3 mm in the middle of the block and 1 mm on edges and ridges is necessary to ensure a stable graft.

4. Design check of the 3D planning

The design of maxgraft® bonebuilder needs to be checked thoroughly before production. Only the responsible surgeon knows the clinical situation of the patient (hard/soft tissue situation) and can estimate the right dimensions of the final bone block. The clinician receives a 3D PDF file containing the virtually constructed maxgraft® bonebuilder block to review the block design and measure its dimensions. The surgeon may request modifications until the design meets all expectations.

For final design approval, please log in on www.botiss-bonebuilder.com, click on the button 'My orders', select your specific order, and click on the button 'Confirm 3D model'.

5. Order of maxgraft® bonebuilder

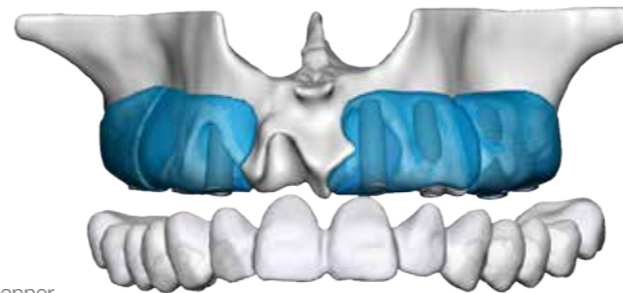
The individual production can only start after final design approval and written order. After confirming the 3D model, please download the order form on the specific order page, fill in the written order form and send it to botiss via fax or email (bonebuilder@botiss.com).

Delivery time and surgery planning

Delivery time is approximately four to five weeks after botiss receives your written order. Therefore, plan your surgery accordingly, allowing for individual block milling. You will receive all further notifications regarding production and shipment of your order via email.

6. Production of maxgraft® bonebuilder

The design data is transmitted to the Cells+Tissuebank Austria, the responsible tissue bank located in Krems, Austria. Each individual maxgraft® bonebuilder is milled from a processed allogenic cancellous block under cleanroom conditions, double-packaged and sterilized using gamma irradiation.



Preoperative assessment and precautions

The outcome of block augmentation procedures depends on many factors and is not 100% predictable. Key elements for a successful surgical procedure and the long-term success of the treatment include:

Careful patient selection

- Thorough review of the patient's medical and dental history
- Clinical and radiographic examination of the anatomy and residual bone height and quality to determine the appropriate bone volume needed
- Site-specific assessment should include treatment planning for the ideal implant type, diameter, length, number and position
- Consideration of patient-related factors that may affect bone healing (e.g., patients with uncontrolled diabetes and heavy smokers)
- Patient compliance and oral hygiene status

Soft tissue quality

- Careful consideration of soft tissue situation
- Preoperative soft tissue management, if necessary
- Intraoperative soft tissue mobilization to ensure a tension-free, saliva-proof wound closure
- Avoiding any soft tissue perforations (countersink screws, remove sharp edges, contouring with particulated bone substitute material)
- Avoiding any pressure on the healing site from temporary prosthesis (renounce on any temporary provision in the first three weeks)

CT/CBCT data quality

- Optimal settings of image devices (e.g., contrast etc.)
- Accurate patient positioning
- Avoiding any artefacts by removing any metallic items

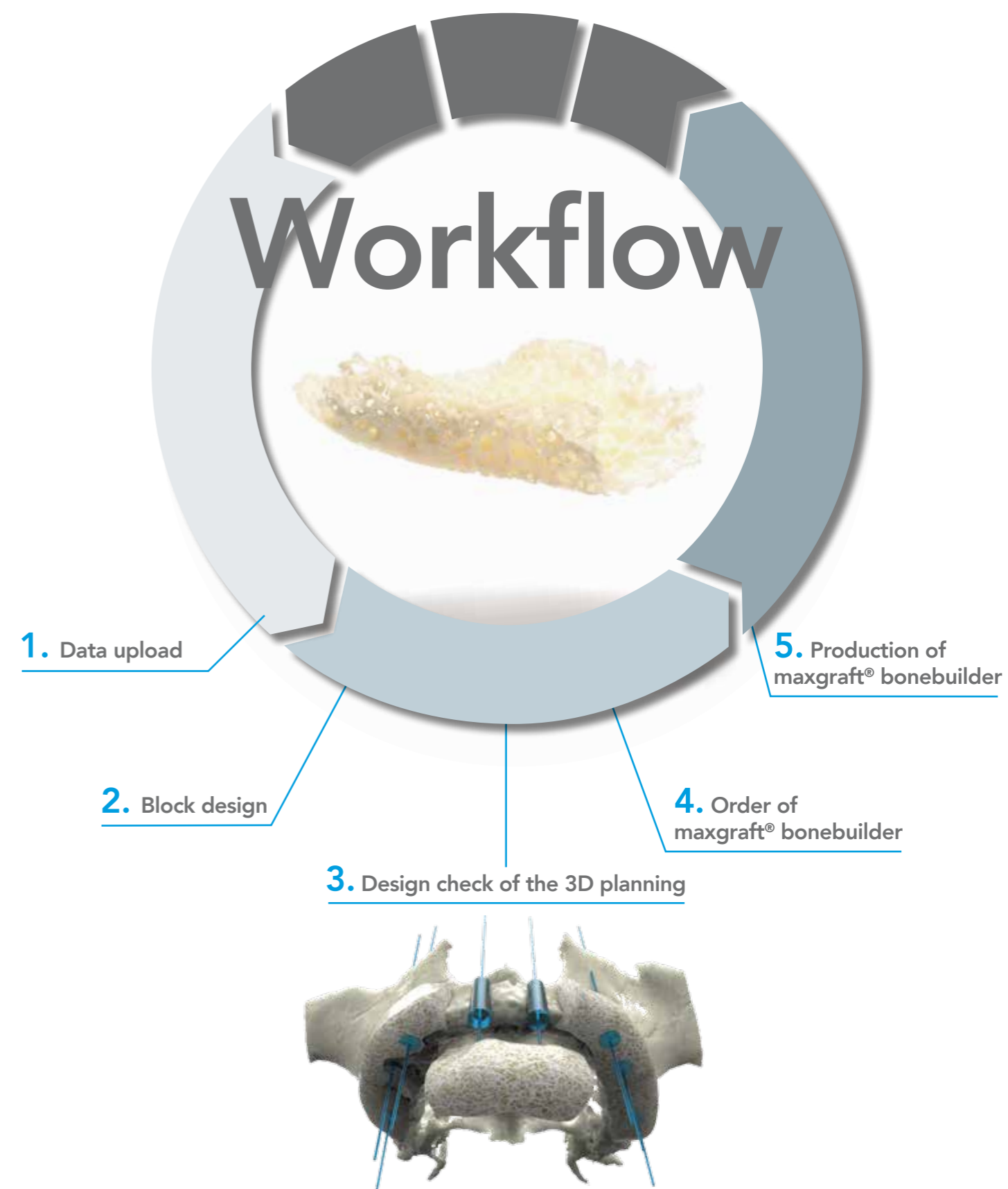Correct use

- Product application according to Instructions For Use
- Preparation of recipient bed
- Correct fixation to ensure optimal contact between allograft and local bone



Patient information and consent

Thorough patient information regarding the treatment plan and the origin of the used bone graft material, including potential surgery associated risks, need to be documented for patient safety.



www.botiss-bonebuilder.com

Surgical procedure

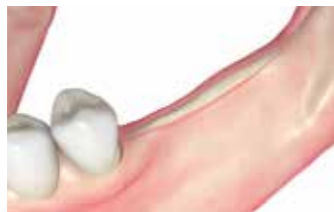Surgical procedure learning curve

Like every other surgical procedure, augmentation with maxgraft® bonebuilder includes a learning curve. The difficulty increases in augmentations in the mandible up to and including complex augmentations using several maxgraft® bonebuilder in the same patient. Soft tissue mobilization (if applicable, prior soft tissue augmentation), and a precise incision and suture technique are determining factors for success of the procedure.

Prior to the first application, lectures and/or hands-on workshops should be attended. Preferable, surgeons intending to perform the procedure should have previous experience with allogenic block augmentation.

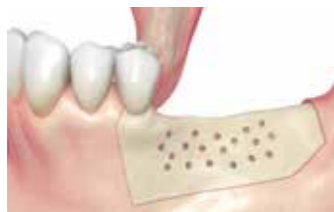Depending on the scope of the procedure and patient profile the augmentation procedure with maxgraft® bonebuilder is performed under local or general anesthesia. A perioperative antibiotic prophylaxis is recommended.

Surgical procedure based on a clinical case of alveolar ridge augmentation in the mandible by Dr. Isser, Frankfurt, Germany:



Step 1 Incision

The used incision technique should allow good access to the entire defect, here shown is a midcrestal incision.

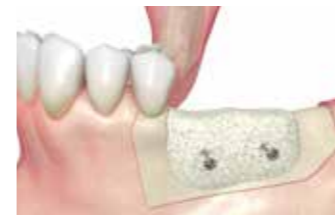

Step 2

Perforation of the cortical layer of the recipient bed In the mandible, perforation of the cortical layer might prove beneficial. Perforation induces translocation of blood, subsequently allowing cells and growth factors into the augmentation site, which can support healing. However, available literature supporting perforation is inconclusive.

Rehydration

maxgraft® bonebuilder should be rehydrated briefly before fixation by creating a vacuum in a disposable syringe filled with sterile saline solution. If possible, mix the saline solution with the exudate serum obtained from preparing autologous platelet-rich fibrin (PRF) matrices. maxgraft® bonebuilder consists of a mineralized collagen matrix with a residual moisture content of <5%. Rehydration may be useful especially for blocks of bigger and complex dimensions to enhance the adaptability of the material to the specific defect site.



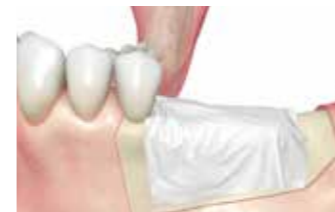Step 3 Fixation

The allogenic bone block is fixed with screws – preferably with flat-head screws to avoid perforation of the surrounding soft tissue – for osteosynthesis.

maxgraft® bonebuilder needs to be immobile for optimal contact between local bone and allograft.

For most defects screws with a diameter of 1.5 mm and a length of 8-11 mm are suitable. The clinical user can measure the right size needed in the 3D PDF file.

Countersinking the bold head of the screw in the bone is recommended, because the head may otherwise irritate the soft tissue. A diamond bur can be used to create the countersink. Sharp edges need to be removed in order to prevent perforations of the soft tissue. Again, a diamond bur can be used for this process. It is essential to avoid any contact to saliva while handling the bone block to reduce the risk of contamination. Potential residual volume can be filled with particulate bone graft material.



Step 4 Covering with a barrier membrane

For guided bone regeneration, the augmented site needs to be covered entirely with a barrier membrane, preventing the ingrowth of soft tissue into the bone block.

Fixating the membrane with titanium pins prevents micro-movements of both the membrane and the particulated allograft material.

PRF matrices covering the membrane, or Straumann® Emdogain®, can be used to support wound healing.

Step 5 Wound closure

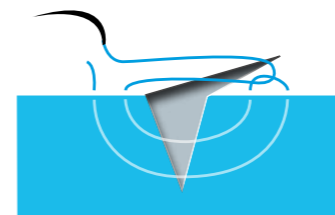
Suturing needs to be totally tension free and saliva-proof.

Proper soft tissue management is crucial for the surgical success.

Tension-free wound closure and sufficient soft tissue quality significantly reduce the risk of complications such as dehiscences.

An overlapping soft tissue mobilization should be possible prior to wound closure.

For primary closure a 'loop' or 'pulley' vertical mattress suture⁸ and/or a continuous locking suture are recommended.



Tension-free suture technique

'loop' or 'pulley' vertical mattress suture

The loop functions as a pulley, directing tension away from the other strands to reduce the possibility of tissue strangulation. This technique promotes eversion of the wound edges and supports a tension-free and saliva-proof wound closure.

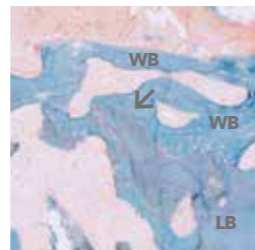
Postoperative care

- The patient should be instructed not to irritate the surgical site mechanically, such as tooth brushing or chewing hard food.
- The patient should immediately report any suspicious issues such as soft tissue perforations and wound dehiscence. A post-operative CBCT or X-ray should be considered.
- Further follow-up visits to control early wound healing should be arranged. Close supervision (e.g. follow-up visits three days, one week/two weeks postoperatively) is highly recommended.
- No pressure should be exerted on the healing site from temporary prostheses. In the first three weeks, it is recommendable to renounce on any temporary provision.

Healing, bone remodeling and graft incorporation

maxgraft® is a natural mineralized collagen matrix and its osteoconductive properties allow rapid revascularization and migration of osteoblasts. The physiologic remodeling of the allogenic bone graft leads to a subsequent replacement of the graft material by patient's own vital bone, due to the balance of resorption and synthesis. Postoperatively, maxgraft® bonebuilder achieves primary osseointegration within six months.

Histological examination of integrated maxgraft® allograft material after six months of healing with Masson-Goldner staining. Newly formed bone (woven bone [WB]) in blue surrounded by a seam of osteoid cells and connective tissue (red). Lamellar bone (LB) and newly formed bone (WB) are in close contact (arrow) and resemble the ongoing remodeling process and osseointegration of the allograft material. Biopsy provided by med. dent. Sören Atrup Nielsen (Muttentz, Switzerland) processed by Prof. Wenisch (Gießen, Germany).



Re-entry and implant placement

Depending on the location, type and extent of the defect, healing times are approximately six months. The appropriate time for re-entry needs to be estimated individually, by the surgeon. Prior to re-entry a radiological scan is recommended. Upon re-entry, screws are removed. The implant must be anchored securely in the cancellous bone. The minimum available bone width should be such that >1 mm of bone should be present on either side of the implant faciolingually to keep the soft tissue levels stable.⁹

Complication management

Close supervision to control early wound healing (see previous page) and proper soft tissue management during surgery, including a precise incision and suture technique, are determining factors for minimizing risk of complications.

In case of early wound dehiscence, a revision of the wound and suture is recommended. If the wound dehiscence occurs during or closely following suture removal, the exposed surface of the bone graft should be carefully removed, wound edges refreshed, and sutures renewed.

In case of late wound dehiscence (e.g., soft tissue perforation due to temporary restoration), any exposed bone should be reduced below the soft tissue level and wound healing should be monitored following a 'wait-and-see' strategy.

Rinsing of the wound area with antiseptic solutions can support the treatment.

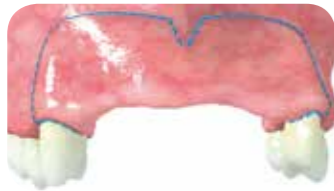
Remote incision technique

The remote incision techniques (according to Dr. Dr. Dr. Blume, Munich, Germany) shown here facilitate proper soft tissue mobilization for achieving complete tension-free primary closure and minimizing the rate of wound dehiscence.

Advantages of this remote technique are:

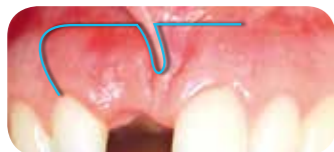- Prevention of block exposure in case of dehiscence, because the incision is placed distant from the bone block
- Prevention of dehiscence due to mechanically induced irritations, because the keratinized mucosa on the alveolar ridge and near papillae are not injured
- Prevention of dehiscence, because the mobilized flap has a good adaptation to the adjacent teeth
- Excellent aesthetic result, because the incision is placed in the flexible mucosa in the vestibular fold and almost no visible scars are left after wound healing

Variants of the remote incision technique in the maxilla according to Dr. Dr. Dr. Blume, Munich, Germany:



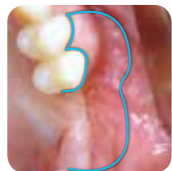
Pillar incision in the aesthetic zone

Preparation of a full-thickness flap with distal relief incisions, originating in the distal third of the adjacent teeth. The horizontal part of the incision is placed high in the flexible mucosa in the vestibular fold, the buccal tissue is carefully dissected protecting the neurovascular structures and then mobilized in palatinal direction for proper soft tissue management.



Semi-pillar incision in a single tooth gap

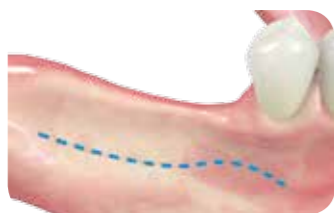Like the procedure as above, but the pillar incision is only executed halfway. The full-thickness flap in form of a semi-pillar is then mobilized in palatinal direction, uncovering the bone defect.



Lateral incision in a free-end situation in the posterior maxilla

Preparation of a full-thickness flap with marginal incisions on the mesial adjacent teeth. The lateral incision is placed high in the flexible mucosa in the mucobuccal fold. The buccal tissue is carefully dissected and then mobilized in palatinal direction for proper soft tissue management.

Variant of the remote incision technique in the mandible according to Dr. Dr. Dr. Blume, Munich, Germany:



The lateral remote incision shown here is a soft-tissue preserving alternative to the midcrestal incision, which does not injure the soft tissue on the alveolar ridge.

Important Information

Material origin

maxgraft® bonebuilder is produced at the Cells+Tissuebank Austria (C+TBA), a non-profit organization aiming to provide allogenic transplants for orthopedic and dental regeneration situated in Krems/Austria. maxgraft® bonebuilder is 100% human donor bone and originates from femoral heads (taken during hip endoprosthesis surgery) of living donors from certified procurement centers in Europe. C+TBA is certified and audited by the Austrian Ministry of Health in accordance with the European Directives regarding donation, procurement, testing, processing, storage and distribution of human tissues and cells (2004/23EC, 2006/17EC, 2006/86EC) and regulated by the Austrian Tissue Safety Act (GSG 2009).



Safety

maxgraft® products are safe for use without a single reported case of disease transmission.

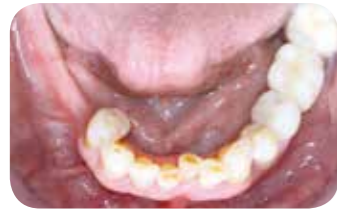All tissue donors are routinely screened for infections according to established tissue banking standards. Only tissue that has been tested negative for HIV, Hepatitis B and C, and syphilis enters the Allotec® process of the C+TBA, which has been validated to be effective in removing potential contaminants (viruses, bacteria, fungi, spores) and thus provides additional safety.

Every step of the production, from explantation in the operation room to final gamma irradiation is performed either in an aseptic or cleanroom environment at pharmaceutical standards within the framework of a GMP-compliant quality management system. During the Allotec® process all non-collagenic proteins are either removed or denatured to eliminate potential antigenicity.

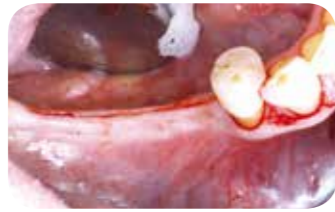CLINICAL CASE BY

Dr. Anke Isser, Frankfurt, Germany

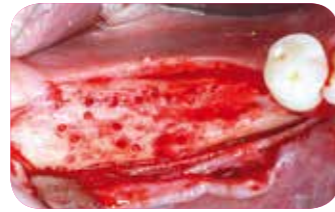
RIDGE AUGMENTATION IN THE POSTERIOR MANDIBLE



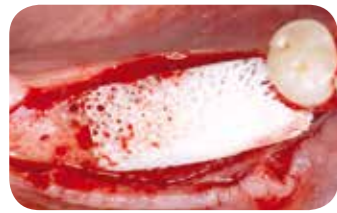Clinical situation preoperative



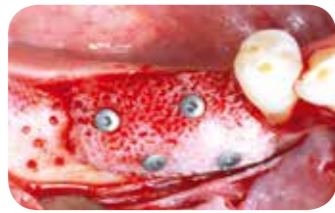Midcrestal incision line



Lingual mobilization and cortical perforation



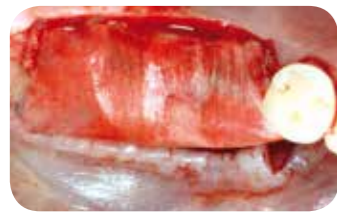Perfect fit of maxgraft® bonebuilder



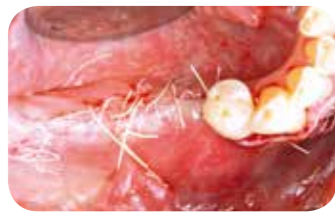Fixation of the block with screws for osteosynthesis



Contouring with cerabone®



Covering of the block with Jason® membrane



Horizontal mattress suture and tension-free wound closure

Wound closure

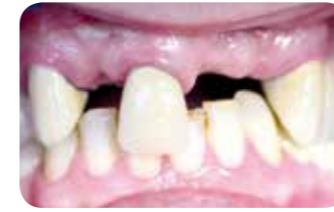

Suturing needs to be totally tension free and saliva-proof. Proper soft tissue management is crucial for the surgical success. Tension-free wound closure and sufficient soft tissue quality significantly reduce the risk of complications such as dehiscences. An overlapping soft tissue mobilization should be possible prior to wound closure.

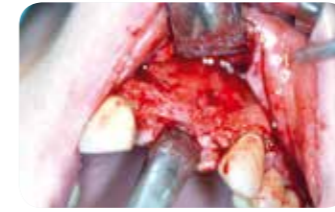CLINICAL CASE BY

Dr. Dr. Frank Kloss, Lienz, Austria

RIDGE AUGMENTATION IN THE AESTHETIC ZONE



Clinical situation before augmentation



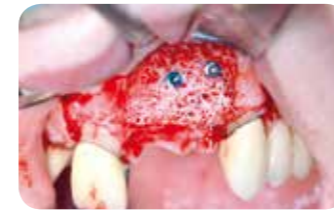Complex bone defect of the buccal wall



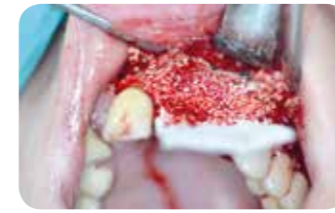3D reconstruction of the bone defect and planned maxgraft® bonebuilder



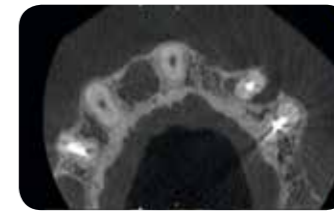
maxgraft® bonebuilder



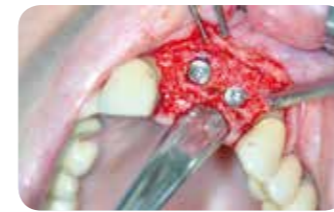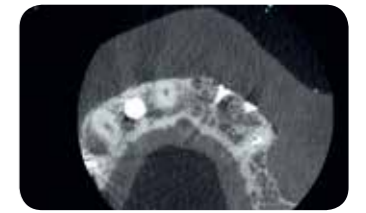
Perfect fit and fixation



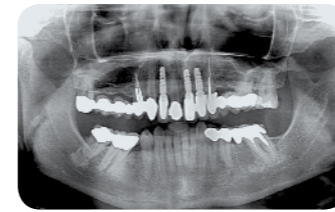
Contouring with cerabone® and covering with Jason® membrane



Preoperative CBCT scan and five months postoperative outcome



Osseointegrated implants at re-entry



Three-year follow-up: stable situation

Continuing education

Visit us on: botiss-academy.com

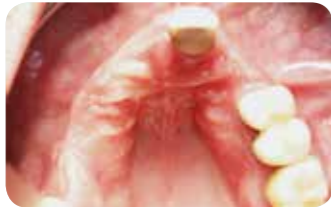For more clinical cases, videos and handling tips visit:

INDICATION-MATRIX.COM

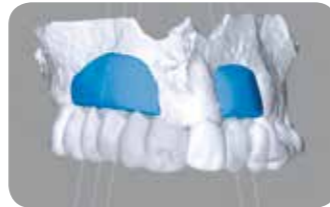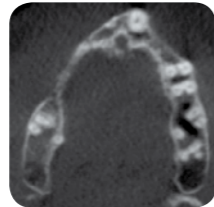
CLINICAL CASE BY

Dr. Dr. Dr. Oliver Blume, Munich, Germany

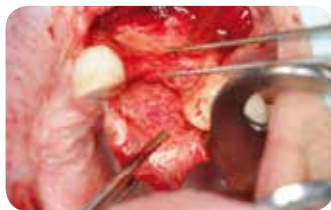RIDGE AUGMENTATION IN THE MAXILLA



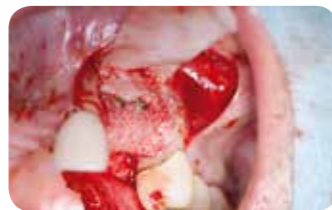Preoperative clinical and radiological situation before augmentation



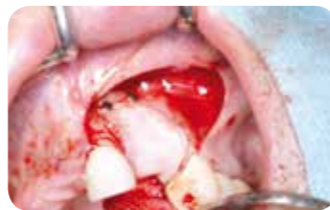3D reconstruction of the bone defect and planned maxgraft® bonebuilder blocks



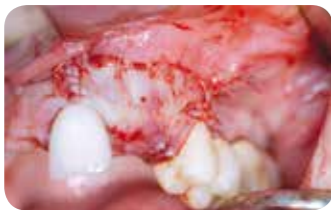Severe ridge atrophy



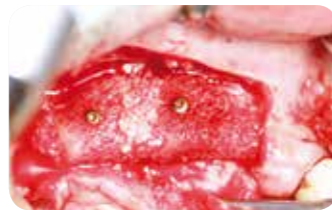Fixation and contouring with allogenic particles



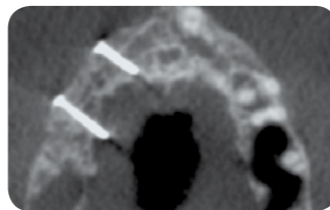
Covering with a barrier membrane and one layer of PRF matrices



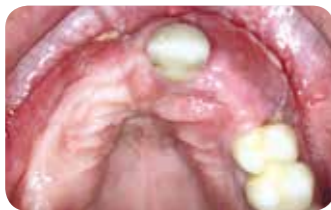Tension-free wound closure



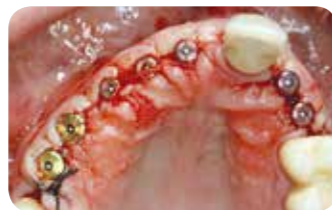Perfect fit and fixation on right side



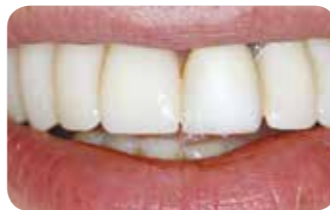CBCT six months postoperative



Six months postoperative clinical situation



Extended alveolar ridge width for stable implant placement



Temporary restoration

REFERENCES

1. Monje, A. et al. On the feasibility of utilizing allogeneic bone blocks for atrophic maxillary augmentation. *Biomed Res. Int.* 2014, 814578 (2014).
2. Novell, J. et al. Five-year results of implants inserted into freeze-dried block allografts. *Implant Dent.* 21, 129–35 (2012).
3. Nissan, J., Mardinger, O., Calderon, S., Romanos, G. E. & Chaushu, G. Cancellous bone block allografts for the augmentation of the anterior atrophic maxilla. *Clin. Implant Dent. Relat. Res.* 13, 104–111 (2011).
4. Jacotti, M., Wang, H.-L., Fu, J.-H., Zamboni, G. & Bernardello, F. Ridge augmentation with mineralized block allografts: clinical and histological evaluation of 8 cases treated with the 3-dimensional block technique. *Implant Dent.* 21, 444–8 (2012).
5. Jacotti, M., Barausse, C. & Felice, P. Posterior atrophic mandible rehabilitation with onlay allograft created with CAD-CAM procedure: a case report. *Implant Dent.* 23, 22–8 (2014).
6. Farzad, M. & Mohammadi, M. Guided bone regeneration: A literature review. *J. ORAL Heal. ORAL Epidemiol.* 83, 111–122 (2012).
7. Toffler, M. et al. Introducing Choukroun's Platelet Rich Fibrin (PRF) to the Reconstructive Surgery Milieu. *Jouranl Implant. Clin. Dent.* 21–32 (2009).
8. Gault, D. T., Brain, A., Sommerlad, B. C. & Ferguson, D. J. P. Loop mattress suture. *Br. J. Surg.* 74, 820–821 (1987).
9. Shenoy, V. Single tooth implants: Pretreatment considerations and pretreatment evaluation. *J. Interdiscip. Dent.* 2, 149 (2012).

LITERATURE

maxgraft® bonebuilder:

Jacotti et al. 2014. Posterior atrophic mandible rehabilitation with onlay allograft created with CAD-CAM procedure: a case report. *Implant Dent.* 23(1):22–8.

Otto, S. et al. 2017. Custom-milled individual allogeneic bone grafts for alveolar cleft osteoplasty - a technical note. *J. Cranio-Maxillofacial Surg.* 45(12):1955-1961. doi: 10.1016/j.jcms.2017.09.011. Epub 2017 Sep 20.

Blume, O. et al. 2017. Treatment of Severely Resorbed Maxilla Due to Peri-Implantitis by Guided Bone Regeneration Using a Customized Allogenic Bone Block: A Case Report. *Materials* 10(10): 1213.

Clinical case reports:

Stavar et al. 2013. Individuell-gefräster Knochenblock als Alternative zu Knochenersatzmaterialien. *Dental Barometer* 06/2013.

Grandoch et al. 2013. Resultatorientierte 3D-Implantations- und Augmentationsplanung. *BDIZ EDI konkret* 02/2013.

Schlee et al. 2013. Augmentation mit einem individuell gefrästen Knochentransplantat. *DIGITAL_DENTAL_NEWS* 03/2013.

Beuer et al. 2012. Eine schonende Methode im atrophierten Kieferkamm (Augmentation mit allogenen, gefrästen Knochen). *J. CONT DENT EDUC* 05/2012.

Hildebrandt et al. 2012. Augmentation ausgedehnter horizontaler und vertikaler Defekte des Kieferkammes (Methoden und Fallbeispiele). *Praktische Implantologie und Implantatprothetik (pip)* 03/2012.

Block augmentation with allografts:

Chaushu et al. 2010. Histomorphometric Analysis After Maxillary Sinus Floor Augmentation Using Cancellous Bone-Block Allograft. *The Journal of Periodontology* 2010;81(8):1147-1152.

Monje et al. 2014. On the feasibility of utilizing allogeneic bone blocks for atrophic maxillary augmentation. *Biomed Res Int [Internet]*. 2014:814578.

Nissan et al. 2012. Histomorphometric Analysis Following Augmentation of the Anterior Atrophic Maxilla with Cancellous Bone Block Allograft. *The International Journal of Oral & Maxillofacial Implants* 27 (1) (January): 84–9.

Nissan et al. 2011. Histomorphometric Analysis Following Augmentation of the Posterior Mandible Using Cancellous Bone-Block Allograft. *Journal of Biomedical Materials Research. Part A* 97 (4) (June 15): 509–13.

Nissan et al. 2011. Efficacy of Cancellous Block Allograft Augmentation prior to Implant Placement in the Posterior Atrophic Mandible. *Clinical Implant Dentistry and Related Research* 13 (4) (December): 279–85. doi:10.1111/j.1708-8208.2009.00219.x.

Allograft safety:

Salvucci. 2011. Bone tissue, lyophilized and stored at room temperature for 15 days or more, is not capable of transmitting HIV, HCV or HBV. *Cell Tissue Bank.* 2011;12:99–104.

Hinsenkamp, M., Muylle, L., Eastlund, T., Fehily, D., Noël, L., & Strong, D. M. (2012). Adverse reactions and events related to musculoskeletal allografts: reviewed by the World Health Organisation Project NOTIFY. *International Orthopaedics*, 36(3), 633–41.

Allografts in comparison with other augmentation methods:

Motamedian et al. 2016. Success rate of implants placed in autogenous bone blocks versus allogenic bone blocks: A systematic literature review. *Ann Maxillofac Surg.* 6(1):78-90.

Sbordone et al. 2014. Volumetric changes after sinus augmentation using blocks of autogenous iliac bone or freeze-dried allogeneic bone. A non-randomized study. *J. Craniomaxillofac Surg.* 42(2):113-8.

bone & tissue
regeneration

botiss
biomaterials

Innovation.
Regeneration.
Aesthetics.

soft tissue

education

hard tissue

botiss biomaterials GmbH
Hauptstr. 28
15806 Zossen
Germany

Tel.: +49 33769 / 88 41 985
Fax: +49 33769 / 88 41 986

www.botiss.com
www.botiss-dental.com
facebook: botissdental