

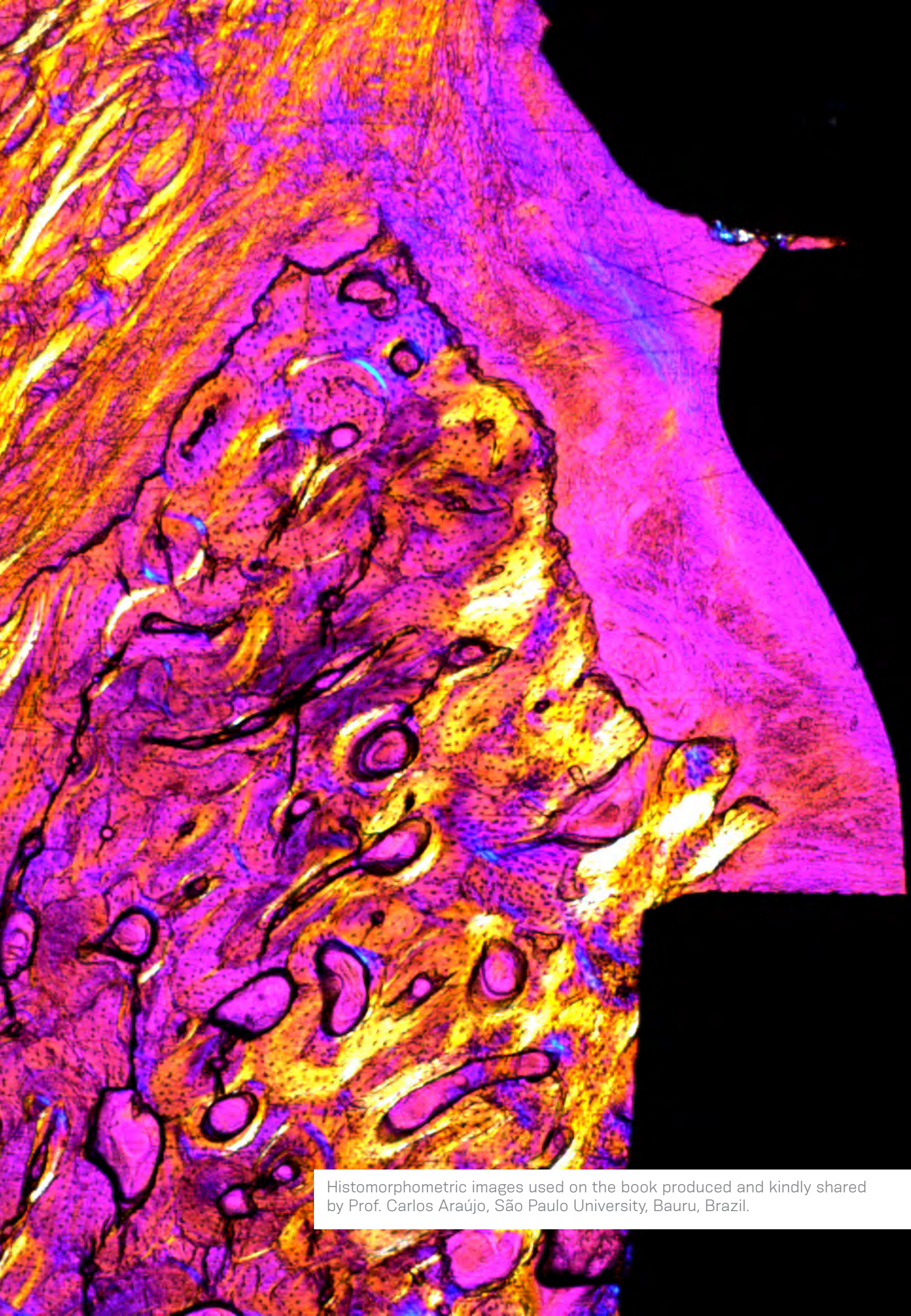
NEODENT ***REFERENCE BOOK***

 **NEODENT®**
A Straumann Group Brand

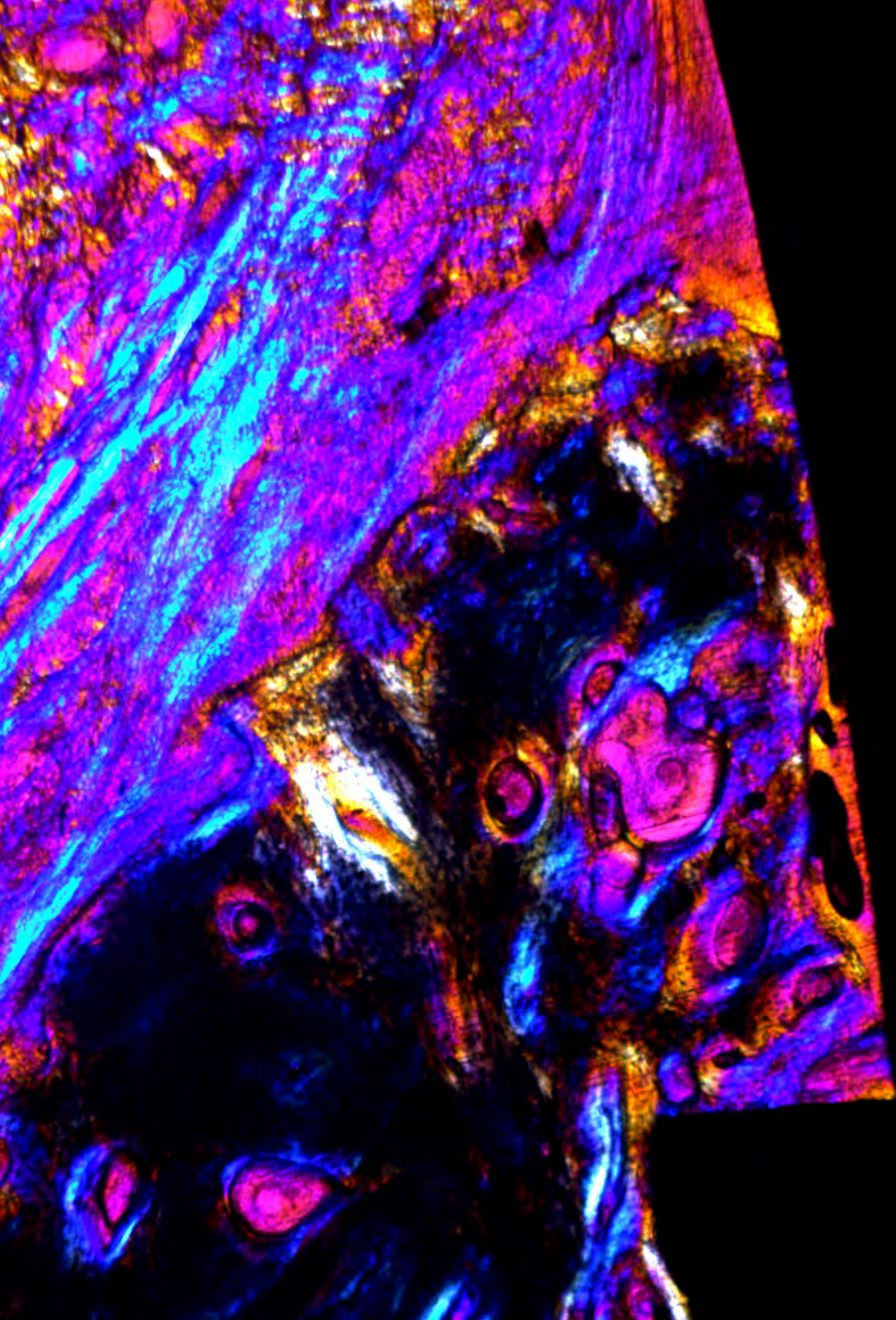
Introduction

Neodent® is the 2nd largest dental implant company worldwide offering outstanding product performance with a proven track record of clinical success as well as professional and patient satisfaction. Neodent's solutions focus on progressive treatment concepts, such as immediacy, to enable advancement in dentistry and affordability for creating new smiles every day.

The reference book aims to highlight neodent key scientific proven facts focusing on essential clinical requirements supporting your daily practice for achieving successful results.



Histomorphometric images used on the book produced and kindly shared by Prof. Carlos Araújo, São Paulo University, Bauru, Brazil.



Summary

<i>A.</i>	Morse Taper connection related to bone maintenance	Page 01
<i>B.</i>	Morse Taper connection related to bacteria sealing	Page 11
<i>C.</i>	Morse Taper connection related to mechanical stability	Page 15
<i>D.</i>	Neodent implant surface	Page 23
<i>E.</i>	Immediate protocols and primary stability	Page 37
<i>F.</i>	Case reports about clinical success	Page 47

A.

**Morse Taper connection
related to bone maintenance**



Clinical Oral Implants Research

01. de Siqueira RAC, Fontão FNGK, Sartori IAM, Santos PGF, Bernardes SR, Tiossi R. Effect of different implant placement depths on crestal bone levels and soft tissue behavior: a randomized clinical trial. Clin Oral Implants Res. 2017;28(10):1227-1233.

Abstract

This randomized clinical trial analyzed crestal bone changes and soft tissue dimensions surrounding implants with an internal tapered connection placed in the mandible anterior region at different depths (equicrestal and subcrestal).

Materials and Methods

Eleven edentulous patients (five implants per patient) were randomly divided in a split-mouth design: G1, 28 equicrestal implants; and G2, 27 subcrestal implants. All implants were immediately loaded. Correlation between keratinized tissue width (KTW) and vertical mucosa thickness (MT) with soft tissue recession was analyzed. Intraoral radiographs were used to evaluate crestal bone changes. Patients were assessed immediately, 4-, and 8-months after implant placement. Rank-based ANOVA-type statistical test was used for comparison between groups ($\alpha = 0.05$).

Results

Fifty-five implants (G1 = 28 and G2 = 27) were assessed in 11 patients. Implant survival rate was 100% for both groups. Both tested implant placement depths presented similar crestal bone loss ($P > 0.05$). Significant crestal bone loss for each group was found in the different measurement times (T4 and T8) ($P < 0.05$). Implant placement depths, KTW, and vertical MT had no effect on soft tissue recession ($P > 0.05$).

Conclusion

Different implant placement depths do not influence crestal bone changes. Soft tissue behavior is not influenced by different implant placement depths or by the amount of keratinized tissue.

Crestal bone loss for both groups in the different evaluation times

Evaluation times	G1 (28 equicrestal implants)		G2 (27 subcrestal implants)		P-value (equicrestal x subcrestal)
	Mean ± SD	Median (min-max)	Mean ± SD	Median (min-max)	
T4	0.86 ± 0.55	0.85 (0.23-1.86)	0.50 ± 0.35	0.47 (0.15-1.38)	0.086
T8	1.03 ± 0.60	1.03 (0.19-1.90)	0.66 ± 0.38	0.61 (0.19-1.52)	
P-value* (T4xT8)	<0.001				

SD, standard derivation, P-value for the interaction between implant type and time: 0.454.

* Rank-based ANOVA tests, $P < 0.05$.



02. Sumiyassu, S et al. Tissue response around morse taper and external hexagon implants: preliminary results of a randomeized split- mouth design. SALUSVITA. 2013; 32(1):09-24.

Introduction

The aim of this study was to histomorphometrically evaluate the influence of interimplant distances (ID) and implant placement depth on bone remodeling around contiguous Morse cone connection implants with 'platform-shifting' in a dog model.

Objectives

The aim of this study was to compare tissue response around immediately loaded mandibular dental implants with two different prosthetic connections.

Materials and Methods

A total of 48 implants were inserted in the anterior region of the mandible of 12 edentulous patients following a randomized split-mouth design. Morse Taper and External Hexagon implants (Neodent) were equally divided into each patient. Distal implants were tilted and central implants axially positioned in relation to the alveolar crest. Standardized intraoral radiographs were taken immediately after implant placement and after 6 months. Periodontal parameters (probing depth and keratinized tissue width and height) were recorded at the same times. Wilcoxon test was used. Results and Discussion: It was observed stability of the gingival margin and decrease in probing depth around Morse taper implants and increase in external hexagon implants. There was marginal bone increase in the mesial face (0.27 mm) and decrease at the distal face (-0.87 mm) of Morse taper and at both proximal faces of external hexagon implants (-1.06 mm and -0.80 mm, respectively). Morse taper tilted implants showed maintenance of bone height (0.03 mm and -0.02mm, mesial and distal) while external hexagon implants showed resorption (-1.82 mm and -0.75 mm, mesial and distal). Axially positioned implants showed bone loss, either Morse taper (-0.72 and -0.67mm, mesial and distal) or external hexagon (-0.69 and -0.83 mm). There was no correlation between availability of keratinized tissue and bone behaviour.

Conclusion

These findings suggest that Morse taper implants showed better results than external hexagon ones, nevertheless it should be emphasized that these are preliminary results and longer evaluations are suggested.

Mesial Face

Design	Bone level	Mean (mm)	Median (mm)	SD (mm)	P value
Tilted Morse Taper	T0 (baseline)	0.33	0.39	0.928	0.959
	T1 (6 months)	0.36	0.76	0.868	
	Difference	0.03	0.00	0.486	
Axial Morse Taper	T0 (baseline)	1.49	1.86	1.20	0.026*
	T1 (6 months)	0.77	1.56	1.47	
	Difference	-0.72	-0.74	0.86	
Tilted External Hexagon	T0 (baseline)	0.72	-1.36	1.42	0.005*
	T1 (6 months)	-1.10	-1.05	1.16	
	Difference	-1.82	-0.23	1.52	
Axial External Hexagon	T0 (baseline)	0.43	0.20	1.00	0.007*
	T1 (6 months)	-0.26	-0.39	1.32	
	Difference	-0.69	-0.50	0.50	

Face

Design	Bone level	Mean (mm)	Median (mm)	SD (mm)	P value
Tilted Morse Taper	T0 (baseline)	1.51	1.86	1.317	0.959
	T1 (6 months)	1.49	1.20	1.004	
	Difference	-0.02	-0.11	1.372	
Axial Morse Taper	T0 (baseline)	1.51	1.35	0.98	0.041*
	T1 (6 months)	0.84	0.63	1.29	
	Difference	-0.67	-0.60	0.93	
Tilted External Hexagon	T0 (baseline)	-0.22	0.58	0.75	0.285*
	T1 (6 months)	-0.97	-0.84	1.76	
	Difference	-0.75	-1.12	1.95	
Axial External Hexagon	T0 (baseline)	0.41	0.55	1.25	0.007*
	T1 (6 months)	-0.43	-0.67	1.42	
	Difference	-0.83	-0.57	0.75	

Peri-implant bone response after 6 months at the mesial and distal faces.



Implant Dentistry

03. Castro DS, Araujo MA, Benfatti CA, Araujo C dos R, Piattelli A, Perrotti V, Iezzi G. Comparative histological and histomorphometrical evaluation of marginal bone resorption around external hexagon and Morse cone implants: an experimental study in dogs. *Implant Dent.* 2014;23(3):270-6

Purpose

Aim of this study was to evaluate the histological and histomorphometrical differences at the marginal bone level with the use of 2 different implant-abutment assembly designs (the traditional External Hexagon and the Morse Cone tapered connections).

Materials and Methods

Nine Morse Cone and 9 External Hexagon implants (Neodent) were inserted in 6 mongrel dogs. The Morse Cone implants were installed 2 mm below the crestal bone level, whereas the External Hexagon flush. The implants were retrieved after 2 months. Mean distance between the original level of coronal bone to the top of the implant and the mean distance between the top of the implant and the first bone-to-implant contact (fBIC) were recorded.

Results

No significant differences were found when the mean distance between the original level of coronal bone to the top of the implant was evaluated; however, there were statistically significant differences in the mean distances between the top of the implants and fBIC, suggesting a smaller amount of bone loss or remodeling in the Morse Cone compared to the External Hexagon group.

Conclusion

Subcrestal placement had a positive impact on crestal bone remodeling in Morse Cone implants.

Mean \pm SD Values of Bone Loss From Bone Crest to Implant Platform

External Hexagon Buccal Side (Mean + SD)	External Hexagon Lingual Side (Mean + SD)	Morse Cone Buccal Side (Mean + SD)	Morse Cone Lingual Side (Mean + SD)
1.23 \pm 0.49	0.79 \pm 0.32	0.03 \pm 0.08	0 \pm 0

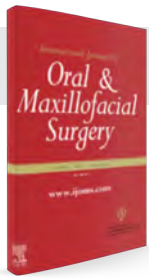Dunn's multiple comparison test.
No statistically significant differences.

Mean \pm SD Values of Crestal Bone Loss From Implant Platform to First Bone to Implant Contact

External Hexagon Buccal Side (Mean + SD)	External Hexagon Lingual Side (Mean + SD)	Morse Cone Buccal Side (Mean + SD)	Morse Cone Lingual Side (Mean + SD)
1.69 \pm 0.44	1.40 \pm 0.63	0.03 \pm 0.08	0 \pm 0

Dunn's multiple comparison test.

External Hexagon buccal side versus External Hexagon lingual side	ns P > 0.05.
External Hexagon buccal side versus Morse Cone buccal side	**P < 0.01.
External Hexagon buccal side versus Morse Cone lingual side	***P < 0.001.
External Hexagon lingual side versus Morse Cone buccal side	*P < 0.05.
External Hexagon lingual side versus Morse Cone lingual side	**P < 0.01.
Morse Cone buccal side versus Morse Cone lingual side	ns P > 0.05.
External Hexagon buccal side versus Morse Cone buccal side	**P < 0.01.



04. Martin C, Thomé G, Melo AC, Fontão FN. Peri-implant bone response following immediate implants placed in the esthetic zone and with immediate provisionalization-a case series study. *Oral Maxillofac Surg.* 2015;19(2):157-63.

Purpose

The aim of this case series was to evaluate success and peri-implant bone response around Morse taper immediate implants with an immediate provisionalization.

Materials and Methods

Twelve immediate implants (Neodent CM) were inserted in the maxilla of nine consecutively treated patients. Proximal bone response was evaluated with digital periapical radiographs, and the buccal wall height and width were evaluated with computed tomography

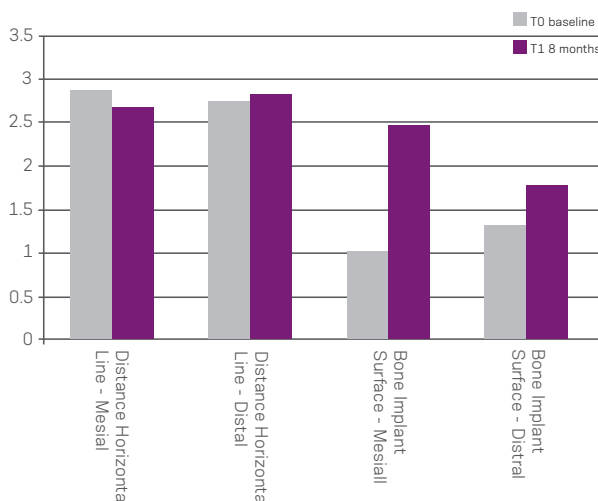
Results

A slight decrease in the marginal bone crest (0.14 ± 0.41 mm) at the mesial face and an increase (0.07 ± 1.58 mm) at the distal face were observed. Considering the point where bone tissue meets the implant surface, there was a statistically significant increase at the mesial face (0.92 ± 1.29 mm) and a not significant increase at the distal face (0.43 ± 1.63 mm). Buccal bone wall width showed a statistically significant bone loss at the level of the implant/abutment junction (0.77 ± 0.75 mm) and at 3 mm (0.59 ± 0.76 mm) and 6 mm (0.46 ± 0.81 mm) apically to the implant/abutment junction. The height of the buccal wall showed a not statistically significant resorption (0.20 ± 0.51 mm).

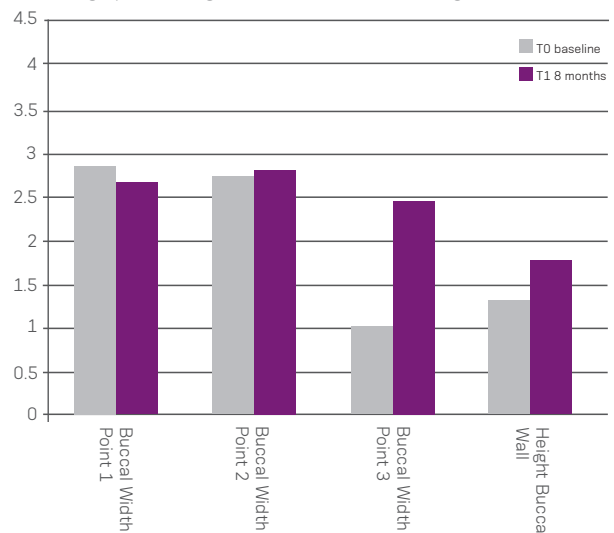
Conclusion

Based on the preliminary results (8 months) of this case series study, it can be concluded that there was bone loss on the mesial bone crest level and on the buccal face and bone increases on the mesial and distal faces in the area where the bone meets the implant surface. Nevertheless, this is just a case series study, and long-term controlled clinical trials are essential for a definitive conclusion.

Column graph showing proximal level data at T0 and T1.



Column graph showing buccal bone width and height at T0 and T1.



05. Novaes AB Jr, Barros RR, Muglia VA, Borges GJ. Influence of interimplant distances and placement depth on papilla formation and crestal resorption: a clinical and radiographic study in dogs. *J Oral Implantol.* 2009;35(1):18-27

Abstract

Among the factors that contribute to the papilla formation and crestal bone preservation between contiguous implants, this animal study clinically and radiographically evaluated the interimplant distances (IDs) of 2 and 3 mm and the placement depths of Morse cone connection implants (Neodent CM) restored with platform switch. Bilateral mandibular premolars of 6 dogs were extracted, and after 12 weeks, the implants were placed. Four experimental groups were constituted: subcrestally with ID of 2 mm (2 SCL) and 3 mm (3 SCL) and crestally with ID of 2 mm (2 CL) and 3 mm (3 CL). Metallic crowns were immediately installed with a distance of 3 mm between the contact point and the bone crest. Eight weeks later, clinical measurements were performed to evaluate papilla formation, and radiographic images were taken to analyze the crestal bone remodeling. The subcrestal groups achieved better levels of papillae formation when compared with the crestal groups, with a significant difference between the 3 SCL and 3 CL groups ($P = .026$). Radiographically, the crestal bone preservation was also better in the subcrestal groups, with statistically significant differences between the 2SCL and 2CL groups ($P = .002$) and between the 3SCL and 3CL groups ($P = .008$). With the present conditions, it could be concluded that subcrestal implant placement had a positive impact on papilla formation and crestal bone preservation, which could favor the esthetic of anterior regions. However, the IDs of 2 and 3 mm did not show significantly different results.

Clinical analysis: distance from the contact point to the tip of the papila (CP-P)

Dog	Crestally		Subcrestally	
	2mm	3mm	2mm	3mm
1	3.04	3.28	0.85	1.85
2	1.24	4.35	1.32	0.41
3	0.91	1.67	0.63	1.13
4	1.38	1.40	0.64	0.86
5	1.37	1.36	0.80	0.97
6	0.57	1.39	0.90	0.85
Mean \pm SD	1.42 \pm 0.85	2.24 \pm 1.27*	0.86 \pm 0.25	1.01 \pm 0.48*

* Significance level pf $p < .05$.

Radiographic analysis: distance from the contact point to the the bone crest (CP-BC)

Dog	Crestally		Subcrestally	
	2mm	3mm	2mm	3mm
1	3.04	3.28	0.85	1.85
2	1.24	4.35	1.32	0.41
3	0.91	1.67	0.63	1.13
4	1.38	1.40	0.64	0.86
5	1.37	1.36	0.80	0.97
6	0.57	1.39	0.90	0.85
Mean \pm SD	3.36 \pm 0.27* ****	3.63 \pm 0.50* **	2.94 \pm 0.21***	2.99 \pm 0.29**

* ** * **** Significance level pf $p < .05$ between groups.



Clinical Oral Implants Research

06. Barros RRM, Novaes AB Jr, Muglia VA, Iezzi G, Piattelli A. Influence of interimplant distances and placement depth on peri-implant bone remodeling of adjacent and immediately loaded Morse cone connection implants: a histomorphometric study in dogs. Clin Oral Implants Res. 2010;21(4):371-8.

Abstract

The aim of this study was to histomorphometrically evaluate the influence of interimplant distances (ID) and implant placement depth on bone remodeling around contiguous Morse cone connection implants with 'platform-shifting' in a dog model.

Materials and Methods

Bilateral mandibular premolars of six dogs were extracted, and after 12 weeks, each dog received 8 implants (Neodent CM), four placed 1.5 mm subcrestally (SCL) on one side of the mandible and four placed equicrestally (ECL) on the other side, alternating the ID of 2 and 3 mm. The experimental groups were SCL with IDs of 2 mm (2 SCL) and 3 mm (3 SCL) and ECL with IDs of 2 mm (2 ECL) and 3 mm (3 ECL). Metallic crowns were immediately installed. After 8 weeks, the animals were euthanized and histomorphometric analyses were performed to compare bone remodeling in the groups

Results

The SCL groups indices of crestal bone resorption were significantly lower than those of ECL groups. In addition, the vertical bone resorption around the implants was also numerically inferior in the SCL groups, but without statistical significance. No differences were obtained between the different IDs. All the groups presented similar good levels of bone-to-implant contact and histological bone density.

Conclusion

The subcrestal placement of contiguous Morse cone connection implants with 'platform shifting' was more efficient in preserving the interimplant crestal bone. The IDs of 2 and 3 mm did not affect the bone remodeling significantly under the present conditions:

Crestal bone resorption between the implants and vertical bone resorption around implants at the interimplants areas and at the free ends of the bridges for the four experimental groups (mean + standard deviation in mm)

Crestal bone resorption		Vertical bone resorption around implants	
		Interimplant area	Free ends area
2 ECL	0.58 ± 0.63	0.92 ± 0.61	0.91 ± 0.60
3 ECL	0.46 ± 0.36*	0.68 ± 0.57	0.92 ± 0.56
2 SCL	(-) 0.14 ± 0.77**	0.49 ± 0.38#	0.79 ± 0.31#
3 SCL	(-) 0.47 ± 0.61	0.37 ± 0.29¥	0.79 ± 0.46
Crestal bone resorption			
Wilcoxon matched-pairs signed-ranks test			
Comparisons	P value	Significance	
2 ECL X 3 ECL	0.8438	P>0.05	
2 ECL X 2 SCL	0.0313	P<0.05*	
2 ECL X 3 SCL	0.0313	P<0.05*	
3 ECL X 2 SCL	0.0938	P>0.05	
3 ECL X 3 SCL	0.0313	P<0.05*	
2 SCL X 3 SCL	0.4375	P>0.05	
Friedman` test (non-parametric repeated measures analysis of variance)			
Parameter	P value	Significance	
Crestal bone resorption	0.0015	P<0.05	
Bone level - interimplant area	0.3715	P>0.05	
Bone level - free ends area	0.8740	P>0.05	
Wilcoxon` matched-pairs signed-ranks test			
Comparisons	P value	Significance	
2 ECL interimplant x free ends areas	0.8438	P>0.05	
3 ECL interimplant x free ends areas	0.0938	P>0.05	
2 SCL interimplant x free ends areas	0.0313	P<0.05#	
3 SCL interimplant x free ends areas	0.0313	P<0.05	
Symbols used evidence the comparisons between the lines that achieved statistical significance.			

07. Melo LA, Souza MBC, Barbosa GAS, Carreiro ADFP. Peri-Implant Bone Loss of External Hexagon and Morse Taper in Patients Wearing Immediately Loaded Overdentures. *Braz Dent J.* 2017;28(6):694-698.

Abstract

The aim of this study was to evaluate the peri-implant bone loss of External Hexagon (EH) and Morse Taper (MT) implants in patients wearing immediately loaded mandibular overdentures during a 1-year follow-up. This is a non-randomized controlled clinical trial including 18 MT and 22 EH implants. Periapical radiographs were taken after overdentures insertion and following 1 year. The peri-implant bone loss was assessed through digitalization and analysis of the radiographs in the software Corel DRAW X7. For this, measurement from implant platform to residual ridge at mesial and distal surfaces of each implant was conducted. The results showed high success rate in the groups EH (100%) and MT (94.4%). For peri-implant bone levels, it was found significant difference between the groups ($p=0.032$) and greater bone loss was observed in the group EH. In general, bone loss was 0.85mm (± 0.82) for EH and 0.10mm (± 1.0) for MT. It was concluded that greater bone loss occurred in the group EH in comparison to the group MT after a 1-year follow-up.

Peri-implant bone level (mm) evaluated in External Hexagon and Morse Taper implants after insertion of mandibular overdenture and following 1 year (T2)

External Hexagon (n=22)

	Med	Q ₂₅	Q ₇₅	LI	LS
T1	-0.34	-1.48	0.79	-1.78	1.90
T2	-1.28	-1.98	-0.31	-2.63	1.68
p**			<0.001		

Morse Taper (n=17)

	Med	Q ₂₅	Q ₇₅	LI	LS	p**
T1	0.12	-0.27	0.55	-2.59	1.83	0.032
T2	-0.73	-1.42	1.81	-2.14	2.54	
p**			0.653			

*Statistical significance between the groups (Man Whitney test).

**Statistical significance in each group regarding the period of evaluation (Wilcoxon test).

B. Morse Taper connection related to bacteria sealing



Implant News

08. dos Anjos CM, Harari ND, Reis RSA, Vidigal Junior GM. Análise in vitro da infiltração bacteriana na interface de pilares protéticos e implantes cone-morse / In vitro analysis of bacterial leakage at the interface between Morse taper implant platform and prosthetic abutments. *ImplantNews*;8(2):239-243, 2011.

Abstract

The presence of microgap between dental implant and prosthetic abutment may be responsible for the accumulation of peri-implant biofilm, composed of several bacterial strains. When described as etiological factor of inflammatory processes they trigger tissue disruption and can interfere with the long-term periimplant health. The aim of this study was to assess whether the microgap between Morse Taper platform implants and prosthetic abutment allow the occurrence of infiltration of a specific bacterial strain. It was used 30 sets implants/prosthetic abutment of two implant systems with Morse Taper interface marketed in Brazil. The sample was divided into 3 groups with 10 samples each: Neodent implants and prosthetic abutments, Ankylos implants with respective prosthetic abutments, and Ankylos implants with Neodent prosthetic abutments. The implant inner chamber was inoculated with 0.1 µl of *Escherichia coli* suspension, before the abutment recommended tightening by each manufacturer. Samples were then immersed in a culture medium for analysis of MacConkey muddiness for analysis of cloudiness, indicating infiltration at the microgap. Measurements after inoculation were performed at 1, 2, 5, 7, and 14 days. The results showed that none of the samples presented cloudiness in the culture medium, with the viability of the bacteria demonstrated by positive control tests. It was concluded that the Morse Taper interfaces systems studied prevented the migration of *E. coli* between the prosthetic abutment and implants used.

Microbiological analysis of the inoculated implants

Implants abutment Time/days	Neodent/ Neodent 1-10	Swab 1-10
1	-	-
2	-	-
5	-	-
10	-	-
14	-	-



Implant Dentistry

09. Resende CC, Castro CG, Pereira LM, Prudente MS, Zancopé K, Davi LR, Penatti MP, das Neves FD. Influence of the Prosthetic Index Into Morse Taper Implants on Bacterial Microleakage. *Implant Dent.* 2015;24(5):547-51

Purpose

To evaluate the influence of Morse taper implant index on microleakage.

Materials and Methods

Thirty implants and abutments (Neodent CM) were divided into 3 groups ($n = 10$): CM1 (universal post and implant without index), CM2 (universal post and implant with index), and CM3 (abutment and implant with index). To evaluate the microleakage from the implant inner part, the implants were inoculated with *Streptococcus sanguinis* solution at a 0.5 McFarland and incubated for 7 days at 37°C in Eppendorf tubes with sterile broth. To evaluate the microleakage into the inner part of implant, these were inoculated with sterile Schaedler broth and immersed in a *Fusobacterium nucleatum* solution at a 0.5 McFarland. The samples were incubated for 30 days in an anaerobic chamber.

Results

Nine samples of each group of the first methodology showed no presented bacterial contamination. No samples of the second methodology demonstrated turbidity of the broth.

Conclusion

The presence of the prosthetic internal index had no influence on bacterial microleakage of Morse taper implants under static conditions, for both methodologies.

Positive and Negative Results of Control Test and Microleakage From the Inner Part of Implant						
	CM1		CM2		CM3	
	Control Test	Microleakage	Control Test	Microleakage	Control Test	Microleakage
1	-	-	-	-	-	-
2	-	-	-	-	-	+
3	-	-	-	-	-	-
4	-	-	-	-	-	-
5	-	-	-	-	-	-
6	-	-	-	-	-	-
7	-	-	-	-	-	-
8	-	-	-	-	-	-
9	-	+	-	-	-	-
10	-	-	-	+	-	-
Total	0	1	0	1	0	1



Morse Taper connection related to mechanical stability

10. Bernardes SR, da Gloria Chiarello de Mattos M, Hobkirk J, Ribeiro RF. Loss of preload in screwed implant joints as a function of time and tightening/untightening sequences. *Int J Oral Maxillofac Implants.* 2014;29(1):89-96.

Purpose

The purpose of this study was to determine whether abutment screw tightening and untightening influenced loss of preload in three different implant/abutment interfaces, or on the implant body

Materials and Methods

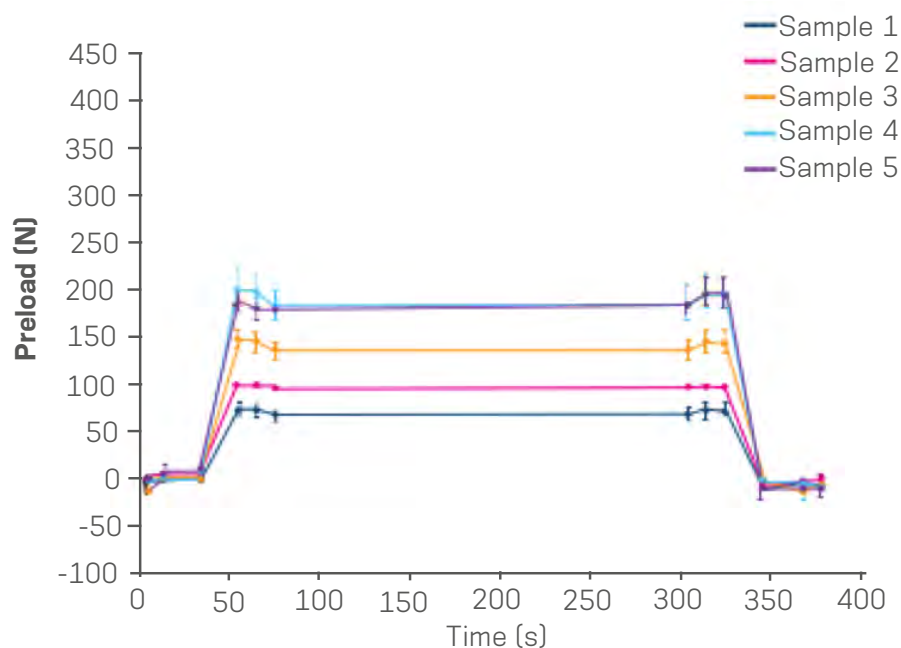
Five custom-fabricated machined titanium implants were used, each with its respective abutment, with different connection types, retention screws, and torque values (external hexagon with titanium screw/32 Ncm, external hexagon with coated screw/32 Ncm, internal hexagon/20 Ncm and internal conical/20 and 32 Ncm). Each implant tested had two strain gauges attached and was submitted to five tightening/untightening sequences.

Results

External hexagons resulted in the lowest preload values generated in the implant cervical third (mean of 27.75 N), while the internal hexagon had the highest values (mean of 219.61 N).

Conclusion

There was no immediate significant loss of preload after screw tightening. Tightening/untightening sequences, regardless of the implant/abutment interface design or type of screw used in the study, did not result in any significant loss of initial preload. Conical implant connections demonstrated greater structural reinforcement within the internal connections.



Mean preload values (N) as a function of time (seconds) and 95% CIs for the five tightening/untightening sequences for the Morse Tape One Piece 32 group.



11. González RC, Shimizu RH, Hermann C, Sartori IAM. Efeito de diferentes níveis de torques na resistência ao destorque do parafuso e dos pilares de duas peças em junções cone-morse. Estudo in vitro / The effect of different torque levels on detorque resistance of a two-piece, cone Morse abutment and screw. An in vitro study ImplantNews; 11(4): 444-450, 2014.

Objective

To determine whether the applied preload influences on detorque resistance of abutment and abutment screw of a two-piece, indexed cone-morse taper connection.

Materials and Methods

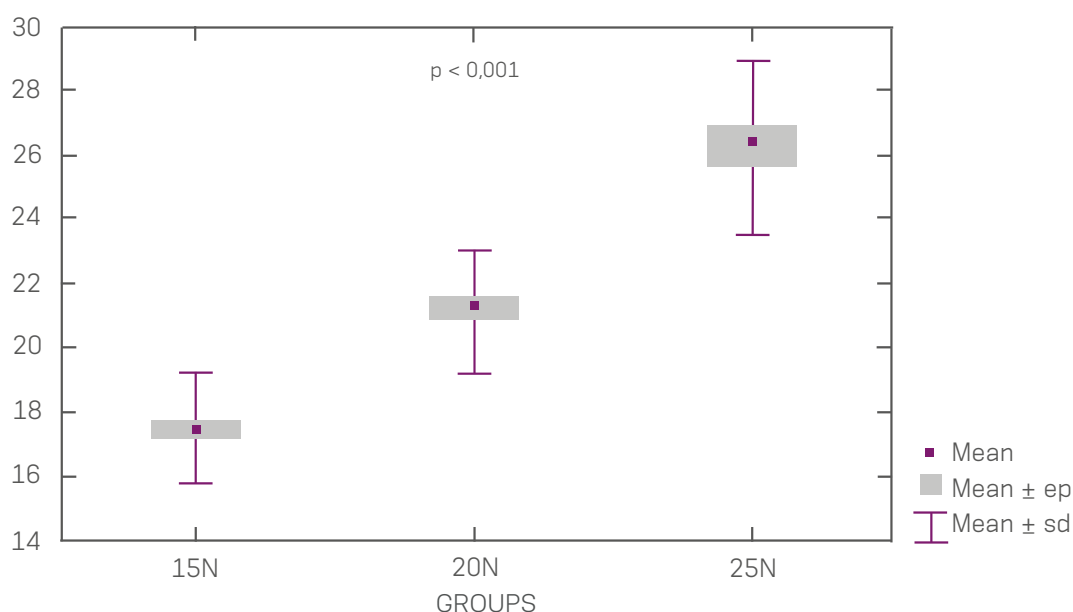
Sixty implant analogs (cone-morse taper=11,5 degrees, Neodent) with internal hexagonal indexing and sixty cone morse universal abutments (4.5 mm diameter, 2.5 mm collar height, and 4 mm in height, non-indexed), were divided into three groups according to applied torques: 15 Ncm (G1); 20 Ncm (G2), and 25 Ncm (G3). The one-way Anova and LSD tests were used for comparisons among groups (at 5% level). Representative SEM images were obtained from screw heads and key drivers.

Results


Mean detorque abutment screw values were as follows: G1=17.48 Ncm, G2=21.16 Ncm, and G3=26.42 Ncm, with statistically significant differences ($p < 0,001$) among all tested groups. Also, the mean detorque abutment levels were: G1=15.17 Ncm, G2=19.58 Ncm, and G3=21.64 Ncm, being (G1 and G2); (G1 and G3) ($p < 0.001$); and G2 and G3 ($p=0.02$).

Conclusion

1) an increase on abutment screw torque level also increases detorque values for all groups; 2) an increase on abutment torque level provided detorque values proportional to that found in G1 and G2, being this lower for G3; 3) torque values higher than those preconized by the manufacturer lead to plastic deformation at screw heads after repeated tightening sequences.



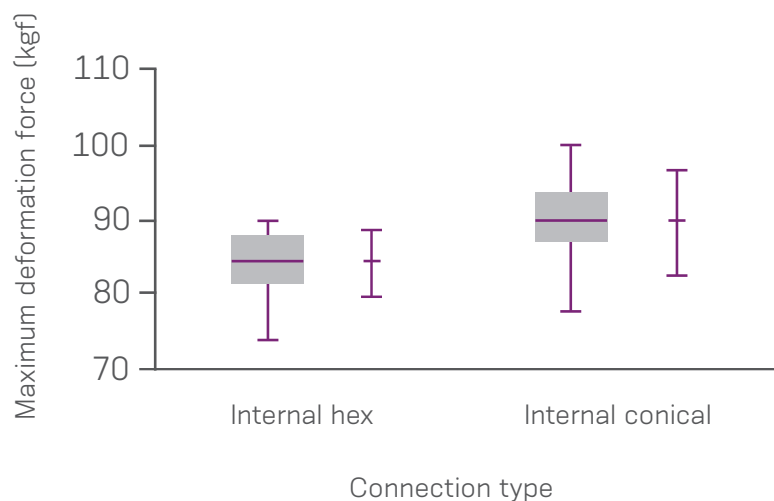
Mean detorque abutment screw values among all tested groups.



12. Coppedê AR, Bersani E, de Mattos Mda G, Rodrigues RC, Sartori IA, Ribeiro RF. Fracture resistance of the implant-abutment connection in implants with internal hex and internal conical connections under oblique compressive loading: an in vitro study. *Int J Prosthodont.* 2009;22(3):283-6.

Abstract

The objective of this study was to verify if differences in the design of internal hex (IH) and internal conical (IC) connection implant systems (Neodent) influence fracture resistance under oblique compressive forces. Twenty implant-abutment assemblies were utilized: 10 with IH connections and 10 with IC connections. Maximum deformation force for IC implants (90.58 ± 6.72 kgf) was statistically higher than that for IH implants (83.73 ± 4.94 kgf) ($P = .0182$). Fracture force for the IH implants was 79.86 ± 4.77 kgf. None of the IC implants fractured. The friction-locking mechanics and the solid design of the IC abutments provided greater resistance to deformation and fracture under oblique compressive loading when compared to the IH abutments.



Maximum deformation force values for the internal hex and the internal conical systems,



13. Castro CG, Zancopé K, Veríssimo C, Soares CJ, Neves FD. Strain analysis of different diameter Morse taper implants under overloading compressive conditions. *Braz Oral Res.* 2015;29(1):16.

Abstract

The aim of this study was to evaluate the amount of deformation from compression caused by different diameters of Morse taper implants and the residual deformation after load removal. Thirty Morse taper implants lacking external threads were divided into 3 groups ($n = 10$) according to their diameter as follows: 3.5 mm, 4.0 mm and 5.0 mm. Two-piece abutments were fixed into the implants, and the samples were subjected to compressive axial loading up to 1500 N of force. During the test, one strain gauge remained fixed to the cervical portion of each implant to measure the strain variation. The strain values were recorded at two different time points: at the maximum load (1500 N) and 60 seconds after load removal. To calculate the strain at the implant/abutment interface, a mathematical formula was applied. Data were analyzed using a one-way Anova and Tukey's test ($\alpha = 0.05$). The 5.0 mm diameter implant showed a significantly lower strain ($650.5 \mu S \pm 170.0$) than the 4.0 mm group ($1170.2 \mu S \pm 374.7$) and the 3.5 mm group ($1388.1 \mu S \pm 326.6$) ($p < 0.001$), regardless of the load presence. The strain values decreased by approximately 50% after removal of the load, regardless of the implant diameter. The 5.0 mm implant showed a significantly lower strain at the implant/abutment interface ($943.4 \mu S \pm 504.5$) than the 4.0 mm group ($1057.4 \mu S \pm 681.3$) and the 3.5 mm group ($1159.6 \mu S \pm 425.9$) ($p < 0.001$). According to the results of this study, the diameter influenced the strain around the internal and external walls of the cervical region of Morse taper implants; all diameters demonstrated clinically acceptable values of strain.

Strain criteria	Ø Implant		
	5.0 mm	4.0 mm	3.50 mm
Strain at maximum load (1500N)	650.5 ± 170.0^A	1170.2 ± 374.7^B	1388.1 ± 326.6^B
Residual Strain (after removing the load)	377.5 ± 106.9^A	594.3 ± 173.6^B	784.4 ± 128.8^C

Means followed by different letters indicate statistically significant differences at 5% compared to the similar values from different diameter implants.



14. Lillo R, Parra C, Fuentes R, Borie E, Engelke W, Beltrán V. Compressive Resistance of Abutments with Different Diameters and Transmucosal Heights in Morse-Taper Implants. *Brazilian Dental Journal*. 2015;26(2): 156-159.

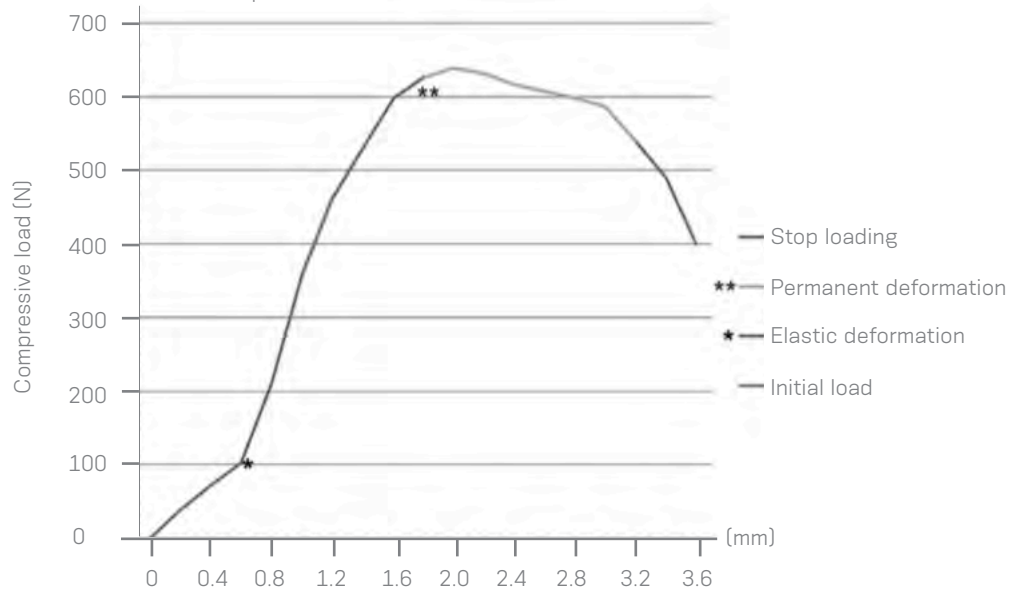
Abstract

The aim of this study was to evaluate the compressive resistance under oblique loads of abutments with two different diameters and transmucosal heights used for cement-retained implant-supported prostheses in Morse-taper implants. Forty Morse-taper implants were divided into four groups with different abutment sizes for cement-retained prostheses in order to perform the compressive test. The groups were divided by abutment diameter and transmucosal height as follows: Group 1: 4.5 x 2.5 mm; Group 2: 4.5 x 3.5 mm; Group 3: 3.3 x 2.5 mm; and Group 4: 3.3 x 3.5 mm. An oblique compressive loading test was performed on each sample located in a platform at 30° using a universal testing machine with a load cell of 1,000 kgf and 0.5 mm/min speed until achieving the deformation of abutment's neck. The compressive resistance and its mechanical behavior were recorded for each group and the data were analyzed using ANOVA, the Shapiro-Wilk and Scheffé tests. In addition, the detailed damage of all samples was recorded with a conventional camera linked to the endoscopic equipment. Significant differences were observed among the groups, except between Groups 2 and 3 ($p>0.005$). All the abutments showed permanent deformations in the upper region and at the transmucosal portion, but the threads of the screws were intact. Fractures were only identified in Groups 3 and 4. Stronger mechanical behavior and compressive resistance was observed in the abutments with 4.5 mm diameter and 2.5 mm transmucosal height.

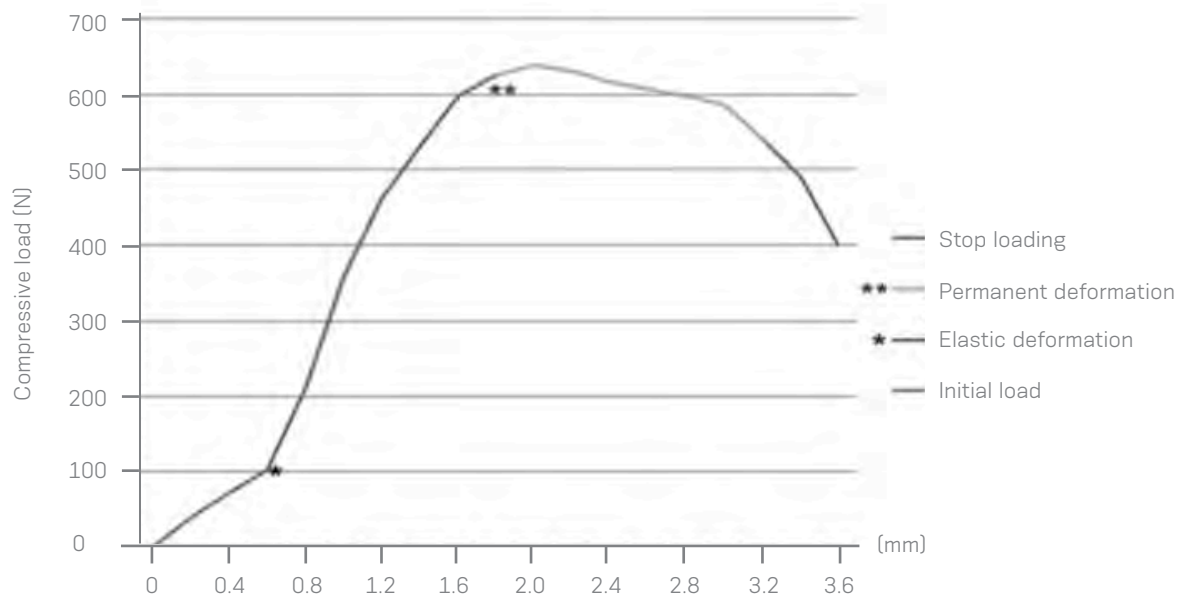
Mean (N) and standard deviation (SD) of maximum deformation load (N) for each group.

Groups	Minimum (N)	Maximum (N)	Mcan (N)	S.D.
1	600.6	608.7	605.7	± 2.33
2	530.8	542.4	536.5	± 3.63
3	503.9	517.9	511.6	± 4.78
4	440.2	464.1	449.0	± 6.52

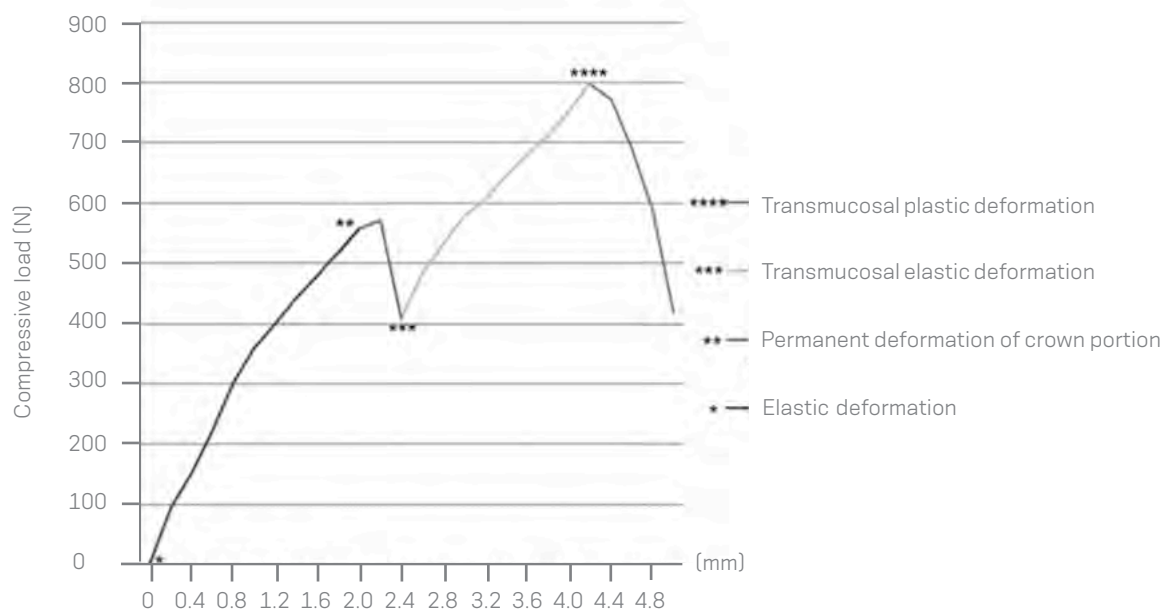
A: Coronal fracture of abutment of 3.3mm in diameter. B: Deformation of abutment of 4.5mm in diameter over the platform. C: Note the transmucosal deformation.



Summary of mechanical behavior of Groups 1 and 2.



Summary of mechanical behavior of Groups 3 and 4.





Clinical Implant Dentistry

15. Gois-Santos VT, Trento CL, dos Santos SV, RCS Santos, Santos SV, Griza S. Analysis of resistance to fatigue between straight solid and anatomic abutments of Morse taper system. Rev Odontol UNESP. 2016; 45(5): 271-276.

Background

The study of the phenomenon of fatigue is essential because implant failures usually are caused by this process.

Purpose

The objective of this study was to examine the fatigue resistance of straight and anatomical abutments joints that were submitted to cyclic loads.

Materials and Methods

We used 37 Morse taper implants and 37 abutments, divided into two groups (n= 16: straight abutment, n= 21 anatomical abutment). The sets were submitted to cyclic loading (5 million) using servo-hydraulic equipment. Three sets from each group were subjected to bending tests to determine the maximum load resistance, which served as the parameter for comparison of the cyclic tests. We evaluated number of cycles, load and bending moment.

Results

Of the 31 abutments cyclically tested, 17 (54.8%) fractured in fewer than 5 million cycles; 8 (25.8%) of these were straight abutments, and 9 (29%) were anatomical. A total of 14 samples (45.2%) resisted the cyclic loading. According to Fisher's exact test, there was no difference between groups as the fracture.

Conclusion

Despite of the straight abutments have higher average load and bending moment on the anatomical, both types of abutments showed similar performance as the fracture strength in vitro.

Values obtained for straight and anatomic abutments according to the occurrence of fracture in cyclic fatigue tests.

Status	Variable	Abutment type		p-value ^a
		Straight	Anatomical	
		Mean ± SD	Mean ± SD	
Fractured	Moment (Nmm)	3.190 ± 301	2.671 ± 582	0.09
	Cycles	178.428 ± 351.091	58.507 ± 83.306	0.236
	Load (N)	566 ± 59	367 ± 80	0.000
Not Fractured	Moment (Nmm)	2.763 ± 71	1.802 ± 324	0.001
	Cycles	-	-	-
	Load (N)	488 ± 20	247 ± 44	0.001
All	Moment (Nmm)	3.026 ± 318	2.237 ± 639	0.002
	Cycles	2.032.879 ± 2.456.246	2.529.253 ± 2.543.019	1.000
	Load (N)	536 ± 61	307 ± 87	0.000

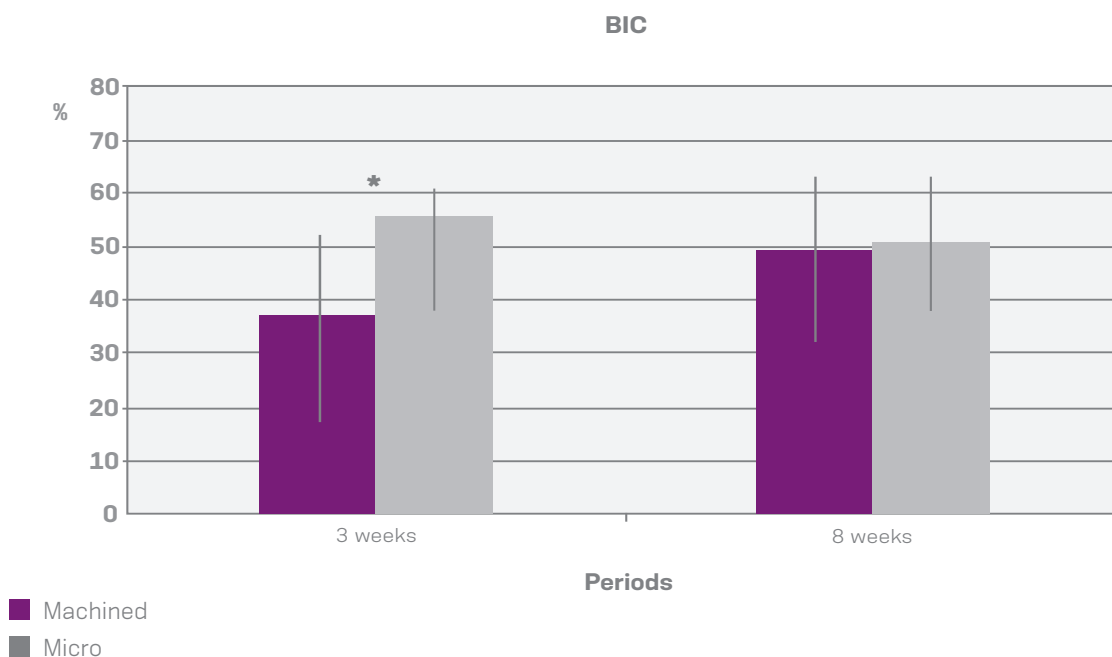
SD=standard deviation. ^aMann-Whitney Test

D. Neodent implant surface

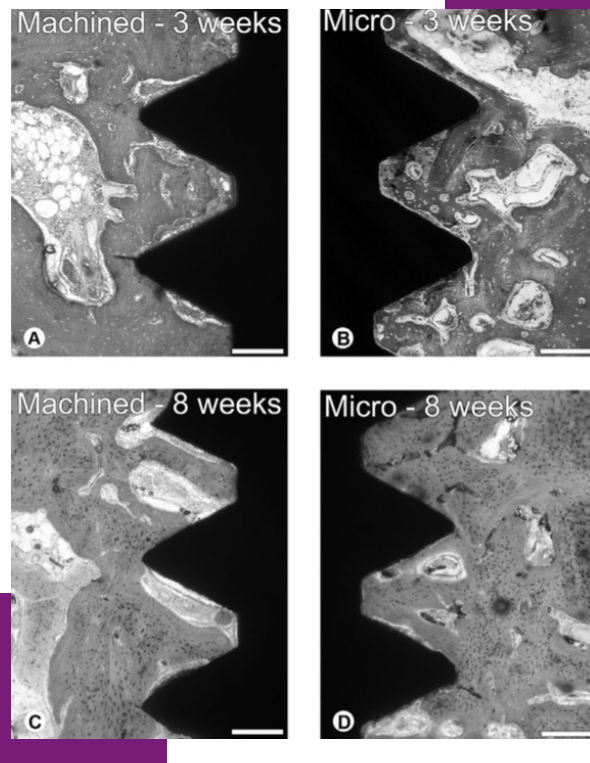
16. Xavier SP, Ikuno KE, Tavares MG. Enhanced bone apposition to Brazilian microrough titanium surfaces. Braz Dent J. 2010;21(1):18-23.

Abstract

It has recently been reported that machined and microrough (micro) Brazilian titanium (Ti) implants have good production standards. The aim of this study was to evaluate in vivo bone formation around 2 different implant surfaces placed in dog's mandible. Thirty-two screw-typed Ti implants were used in this study. Mandibular premolars were extracted in 8 dogs and, after 12 weeks, 2 machined (Neodent Titamax, Brazil) and 2 micro implants (Neodent Titamax Porous, Brazil) were placed in each animal. Biopsies were taken at 3 and 8 weeks post-implantation and stained with Stevenel's blue and Alizarin red for histomorphometric measurements of bone-to-implant contact (BIC), bone area between threads (BABT) and bone area within the mirror area (BAMA). Data were analyzed statistically by two-way ANOVA ($\alpha=0.05$). While at 3 weeks micro implants exhibited significantly more BIC than machined ones ($55 \pm 12.5\%$ and $35.6 \pm 15\%$, $p<0.05$), no significant difference in such parameter was detected at 8 weeks ($51.2 \pm 21\%$ and $48.6 \pm 18.1\%$, $p>0.05$). There were no significant differences in BABT and BAMA between the implants. Micro surfaces promoted higher contact osteogenesis. These data indicate that this commercial micro Ti implant surface enhances contact osteogenesis at an early post-implantation period when compared to the machined one.



Percentage of bone-to-implant contact (BIC; mean + SD) for machined and micro surfaces at 3 and 8 weeks.* Significant ($p<0.05$).



Mesiodistal ground sections of machined (A,C) and micro (B,D) Ti implants and the surrounding connective tissues at 3 (A,B) and 8 (C,D) weeks postimplantation. At 3 and 8 weeks, lamellar bone trabeculae and bone marrow were observed in close contact with machined surfaces (A,C), whereas a continuous, thin layer of newly formed bone, which was connected to trabeculae of lamellar bone, was observed in intimate contact with micro surfaces.



Dental Press Implantology

17. Alves MLM, Iwaki Filho L, Sábio S, Zen Filho EV, Soares S. Avaliação da estabilidade de implantes curtos Neodent, tipo Cone Morse, por meio do teste do torque reverso: estudo preliminar em coelhos / Assessing stability of Neodent Morse taper implants through reverse torque technique testing: a preliminary study in rabbits. Dent press implantol. 2014;8(4): 94-101.

Introduction

Several types of implants are available on the market, including internal or external hexagonal connections and the Morse Taper connection. The latter provides better distribution and transmission of forces throughout the implant. Implant osseointegration can be measured and assessed by reverse torque.

Objective

The objective of this study is to test, in Morse Taper implants installed in rabbit's tibia, the feasibility of a new reverse torque assessment method.

Methods

Neodent Morse Taper WS implants were installed in rabbit's tibia. The animals were sacrificed at different periods of time. The bone blocks containing the implants were cut, and a corresponding mounting device was attached to the implant, forming a single pillar. Reverse torque was simulated using a universal testing machine EMIC DL 1000. Compressive force was applied to the arm of the ratchet.

Results

The values obtained with the test were: Rabbit 1 (immediate)= 1.8 Kgf, Rabbit 2 (7 days) = 7.6 Kgf, Rabbit 3 (15 days) = 17 Kgf, Rabbit 4 (30 days)=27Kgf, and Rabbit 5 (45 days) = 36 Kgf.

Conclusion

Results were promising as they indicated an increase in the value of reverse torque over time.

Rabbit 1 (immediate) = 0,18kgf, or 1,76N;
Rabbit 2 (7 days) = 0,76kgf, or 7,45N;
Rabbit 3 (15 days) = 1,7kgf, or 16,67N;
Rabbit 4 (30 days) = 2,7kgf, or 26,48N;
Rabbit 5 (45 days) = 3,6kgf, or 35,30N.

18. Sartori IAM, Latenek RT, Budel LA, Thomé G, Bernardes SR, Tioosi R. Retrospective analysis of 2,244 implants and the importance of follow-up in implantology. JDR. 2014;2(6): 555-565.

Aim

A retrospective clinical analysis evaluated the clinical behavior of the prosthetic restorations, screw joint stability, peri-implant bone level and soft tissues, implant survival rate and patient satisfaction.

Materials and Methods

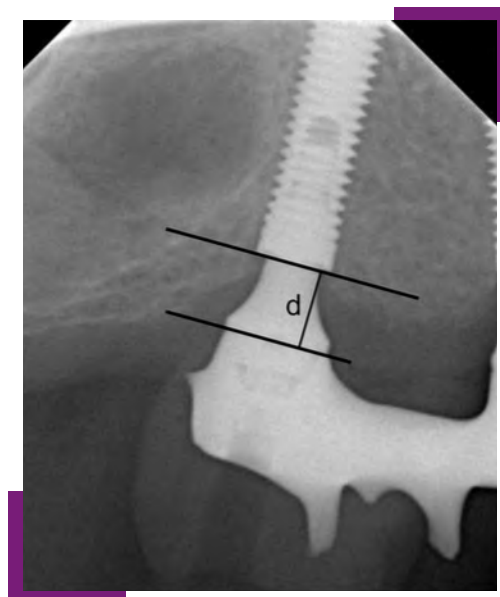
Data was collected from follow-up visits of 444 patients, aged from 26 to 88 years, that were rehabilitated with 2,244 implants (Neodent) placed between 2005 and 2010.

Results

The implant survival rate was 99.73%, 94.78% for prosthetic screws, and 96.70% for abutment screws. Peri-implant bone levels remained stable (bone loss equal or less than 1 mm) in 96.21% of the implants. Plaque accumulation was present in 275 patients and was associated with gingival bleeding in 66 patients. Three hundred and thirty patients were satisfied, 103 were somewhat satisfied, 7 patients expected more from their restorative treatment, and 4 patients were dissatisfied.

Conclusion

Continuous follow-up of patients with implant restorations provides essential information on the behavior of implants and prosthetic components, enabling the early intervention in minor prosthetic complications (e.g. screw loosening) to avoid future major complications (e.g. implant failure).



Evaluation of the peri-implant bone level - X-ray of Morse taper implant. d=measured vertical bone remodeling.

19. Sartoretto SC, Alves AT, Resende RF, Calasans-Maia J, Granjeiro JM, Calasans-Maia MD. Early osseointegration driven by the surface chemistry and wettability of dental implants. *J Appl Oral Sci.* 2015;23(3):279-87.

Objectives

The objective of this study was to investigate the impact of two different commercially available dental implants on osseointegration. The surfaces were sandblasting and acid etching (Group 1, Neoporos, Neodent) and sandblasting and acid etching, then maintained in an isotonic solution of 0.9% sodium chloride (Group 2, Acqua, Neodent).

Materials and Methods

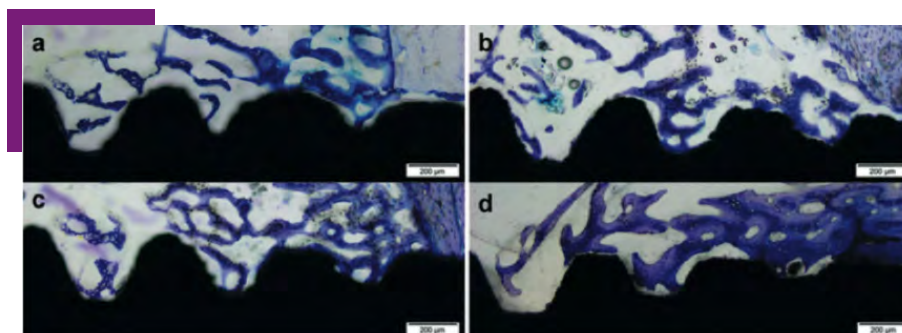
X-ray photoelectron spectroscopy (XPS) was employed for surface chemistry analysis. Surface morphology and topography was investigated by scanning electron microscopy (SEM) and confocal microscopy (CM), respectively. Contact angle analysis (CAA) was employed for wetting evaluation. Bone-implant-contact (BIC) and bone area fraction occupied (BAFO) analysis were performed on thin sections (30 μ m) 14 and 28 days after the installation of 10 implants from each group (n=20) in rabbit's tibias. Statistical analysis was performed by ANOVA at the 95% level of significance considering implantation time and implant surface as independent variables.

Results

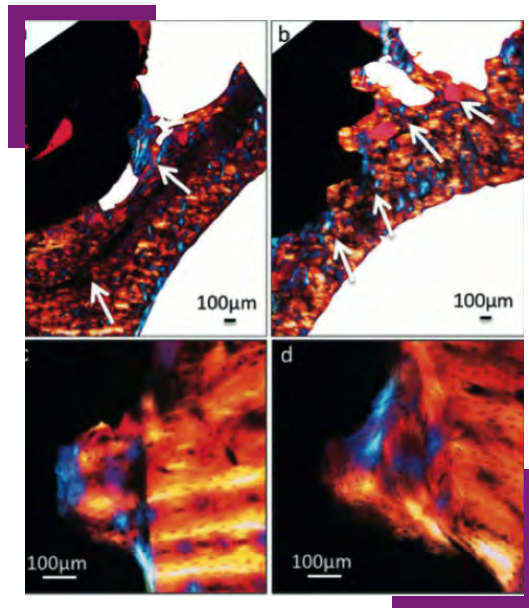
Group 2 showed 3-fold less carbon on the surface and a markedly enhanced hydrophilicity compared to Group 1 but a similar surface roughness ($p>0.05$). BIC and BAFO levels in Group 2 at 14 days were similar to those in Group 1 at 28 days. After 28 days of installation, BIC and BAFO measurements of Group 2 were approximately 1.5-fold greater than in Group 1 ($p<0.05$).

Conclusion

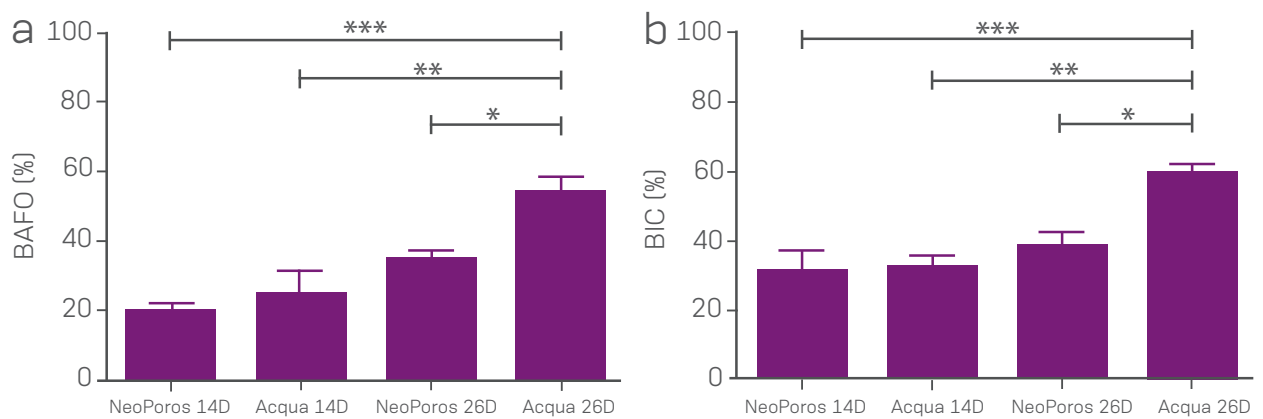
The surface chemistry and wettability implants of Group 2 accelerate osseointegration and increase the area of the bone-to-implant interface when compared to those of Group 1.



Photomicrographs of toluidine blue stained thin sections of the Group 1 at 14 days (a) and 28 days (b) and Group 2 at 14 days (c) and 28 days (d) in bright field (original magnification 10x). Observe the presence of the new bone formation in the area between threads and the contact between bone and both implant groups. In Group 2 at 28 days, see the presence of trabecular bone more compact and in a greater number than Group 1 at the same period, suggesting the acceleration of osseointegration.



Polarized light micrographs of implant sections at the 28 day period. Apical region in Group 1 (a) and Group 2 (b) (original magnification 4X); cervical region in Group 1 (c) and Group 2 (d) (original magnification 20X). The arrows indicate the direction of osteoconduction from pre-existing bone in direction to the implant.



Histomorphometric analysis of (a) Bone area fraction occupied (BAFO) and (b) Mean bone-to-implant contact (BIC). BAFO was calculated as a percentage of the region among the threads. BIC was calculated as a percentage of the total implant perimeter. Results are shown as mean percentages \pm standard deviation. Statistically significant differences are indicated by an asterisk, * $p < 0.05$; ** $p < 0.01$; *** $p < 0.001$.



Clinical Oral Implants Research

20. Dias RR, Sehn FP, de Santana Santos T, Silva ER, Chaushu G, Xavier SP. Corticocancellous fresh-frozen allograft bone blocks for augmenting atrophied posterior mandibles in humans. *Clin Oral Implants Res.* 2016;27(1):39-46.

Abstract

Allograft fresh-frozen bone (FFB) is an alternative to autogenous bone for oral implantation due to bone quantity availability and lower morbidity for patients. Few specific studies about the use of FFB for reconstructing the posterior mandibular alveolar crest have been conducted.

Objective

The objective of this study was to evaluate histological, histomorphometrical, and volumetric aspects of FFB allografts used to augment atrophied posterior mandible bone ridges. Materials and methods: Sixteen hemi-mandibles of twelve patients presenting with critical alveolar atrophy were three-dimensionally reconstructed using corticocancellous FFB. Thirty blocks were fixed with titanium screws and covered with particulate bovine bone mineral and collagen membrane. Volumetric data were obtained by cone beam computed tomography analysis after 6 months, implants were inserted, and bone biopsies were harvested and sent for histological and histomorphometric analyses.

Results

The blocks were distributed between nine female and three male patients (mean age, 50.9 ± 8.3 years). Thirty implants were installed, and the implant survival rate was 96.66%. Histology demonstrated newly formed vital bone contacting residual acellular allograft bone and connective tissue. The histomorphometric analysis showed 18.9 ± 8.1% newly formed bone and 32.5 ± 14.8% allograft residual bone. Graft absorption was 45% for height and volume, and both measures were significantly different ($P < 0.001$).

Conclusion

Fresh-frozen allografts are a viable alternative for reconstructing an atrophied mandible in the posterior region, allowing for new bone formation, installation of implants, and prosthetic loading.

	Gender	Age	Neo bone formation	Residual Allograft	Connective Tissue
Patient 1	F	64	14.9	26.9	58.2
Patient 2	M	52	17.3	73.8	8.9
Patient 3	F	46	39.1	19	41.9
Patient 4	F	47	16.3	42.9	40.8
Patient 5	F	54	14.9	36.1	49
Patient 6	M	37	7.2	27.3	65.5
Patient 7	F	52	22.6	20.2	57.2
Patient 8	F	58	15.9	24.2	59.8
Patient 9	F	51	25.8	32.7	41.5
Patient 10	F	52	14.3	36.8	48.9
Patient 11	M	37	14.6	25.9	59.5
Patient 12	F	61	23.9	24.3	51.8
Median	-	52	16.1	27.1	50.4
Mean	-	50.9	18.9	32.5	48.6
SD	-	8.3	8.1	14.8	14.9

Clinical data and histomorphometry of new bone formation (%), allogenic bone (%), and connective tissue (%).



21. Dinato TR, Grossi ML, Teixeira ER, Dinato JC, Szczepanik FS, Gehrke SA. Marginal Bone Loss in Implants Placed in the Maxillary Sinus Grafted With Anorganic Bovine Bone: A Prospective Clinical and Radiographic Study. *J Periodontol.* 2016;87(8):880-7.

Abstract

Sinus elevation is a reliable and often-used technique. Success of implants placed in such situations, even with bone substitutes alone, prompted the authors of this study to strive for bone loss close to zero and research variables that cause higher or lower rates of resorption. The objective of this study is to evaluate survival rates and marginal bone loss (MBL) around implants placed in sites treated with maxillary sinus augmentation using anorganic bovine bone (ABB), and identifies surgical and prosthetic prognostic variables.

Materials and Methods

Fifty-five implants were placed in 30 grafted maxillary sinuses in 24 patients. Periapical radiographs were evaluated immediately after implant placement (baseline), 6 months, and at the most recent follow-up. MBL was calculated from the difference between initial and final measurements, taking into account a distortion rate for each radiograph compared with original implant measurements.

Results

Survival rate was 98.2%, with only one implant lost (100% survival rate after loading) over a mean follow-up time of 2.0 – 0.9 years. MBL ranged from 0 to 2.85 mm: 75.9% of mesial sites and 83.4% of distal sites showed <1 mm of MBL, whereas 35.2% of mesial sites and 37% of distal sites exhibited no bone loss. MBL was significantly ($P < 0.05$) greater in open flap compared with flapless surgery.

Conclusion

Within the limitations of the present study, it was concluded that maxillary sinus elevation with 100% ABB gives predictable results, and that flapless surgery results in less MBL compared with traditional open-flap surgery.

Comparison of Mesial Versus Distal MBL Among Different Variables

Independent Variables	MBL (mm)	MBL (mm)	P Value	
			Mann-Whitney U test	Student t test (two-tailed)
Mesial versus distal	0.6 (± 0.7) n = 54	0.4 (± 0.5) n = 54	NS	NA
Flapless versus Flap surgery				
Mesial	0.2 (± 0.3) n = 22	0.8 (± 0.8) n = 32	NA	<0.001
Distal	0.2 (± 0.4) n = 22	0.5 (± 0.6) n = 32	<0.05	NA
One-stage versus two-stage surgery				
Mesial	0.5 (± 0.5) n = 13	0.6 (± 0.7) n = 41	NA	NS
Distal	0.3 (± 0.4) n = 13	0.4 (± 0.6) n = 41	NS	NA
Multiple versus single abutment				
Mesial	0.5 (± 0.7) n = 42	0.8 (± 0.7) n = 12	NS	NA
Distal	0.4 (± 0.5) n = 42	0.4 (± 0.7) n = 12	NS	NA
Women versus men				
Mesial	0.6 (± 0.7) n = 31	0.5 (± 0.7) n = 23	NA	NS
Distal	0.3 (± 0.5) n = 31	0.4 (± 0.3) n = 23	NS	NA

MBL Values are shown as mean (\pm SD).

NS = not significant; NA = not applicable.



Clinical Oral Implants Research

22. Sartoretto SC, Alves ATNN, Zarranz L, Jorge MZ, Granjeiro JM, Calasans-Maia MD. Hydrophilic surface of Ti6Al4V-ELI alloy improves the early bone apposition of sheep tibia. Clin Oral Implants Res. 2017;28(8):893-901.

Abstract

The aim of this preclinical study was to compare histologically and histomorphometrically both sandblasted/acid-etched implant surfaces with or without maintained in an isotonic solution of 0.9% sodium chloride in early stages of osseointegration.

Materials and Methods

Both implant surfaces were composed of a titanium/aluminum/vanadium alloy (Ti6Al4V-ELI), but they had different surface chemistries: sandblasted/acid-etched titanium surface (FN) or sandblasted/acid-etched surface maintained in an isotonic solution of 0.9% sodium chloride (FA). The surface morphology, topography and chemistry were evaluated by scanning electron microscopy (SEM), confocal microscopy (CM) and X-ray photoelectron spectroscopy (XPS), respectively. Dynamic contact angle (DCA) was employed for wettability evaluation. One implant from each group was placed in the left tibia of twenty healthy, skeletally mature Santa Ines sheep (n = 5). Bone area (BA) and bone-to-implant contact (BIC) were performed on thin sections (30 μ m) at 7, 14, 21 and 28 days after implant installation.

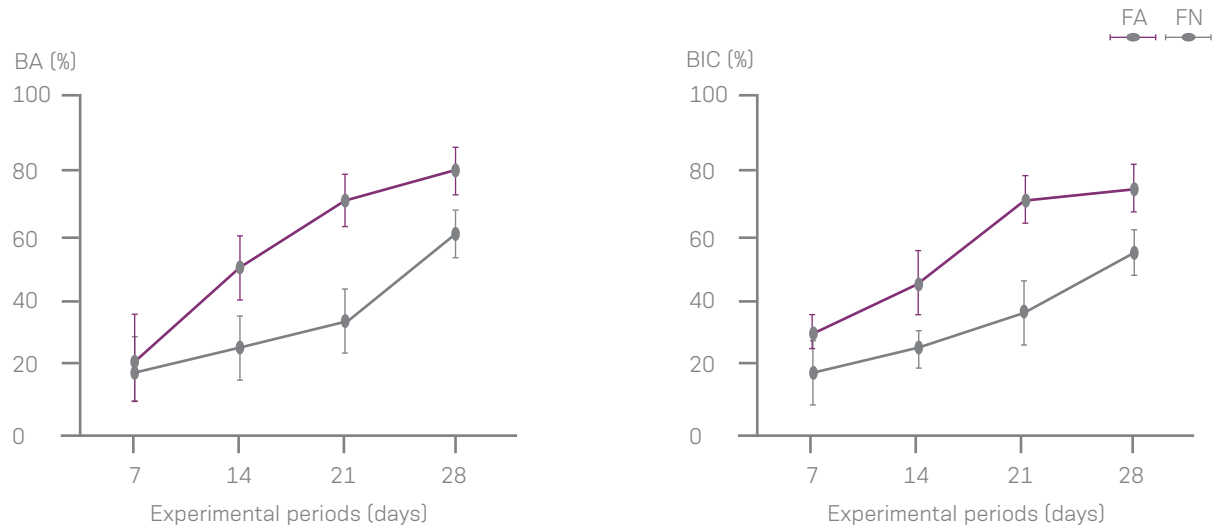
Results

Despite the roughness and morphology similarities between the groups, at the XPS evaluation, the FA group presented 2.3 times less carbon on the surface (FN: 27.3% and FA: 11.6%), sharply enhanced hydrophilicity and significantly enhanced BA and BIC at 14, 21 and 28 days of healing ($P < 0.05$) compared with the FN.

Conclusion

The data suggest that the hydrophilic FA accelerates the BA apposition and BIC interface around the implants during early stages of bone formation, providing highest degree of osseointegration.

Bone area (BA) and bone-to-implant contact (BIC) percentages in the FN and FA groups 7, 14, 21 and 28 days post-implantation. Asterisks (*) represent significant differences between the FN and FA groups at the same experimental time point. The results are shown as the mean percentages \pm confidence interval.



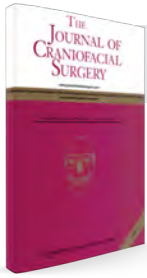Mean, median, standard deviation, minimum and maximum values of Bone area (BA) and bone-to-implant contact (BIC) for FN and FA groups after 7, 14, 21 and 28 days post-implantation

		BA (%)					BIC (%)				
	Days	Mean (n=5)	SD	Min	Max		Days	Mean (n=5)	SD	Min	Max
FN	7	17.4	6.23	12	28	FN	7	15.6	9.73	4	30
	14	26.8	11.76	15	43		14	25.8	4.38	20	32
	21	35.8*	12.28	23	54		21	41.4*	12.15	23	56
	28	60.2*†‡	6.26	51	66		28	56.0*†	8.39	45	66
FA	7	20.2	8.20	10	32	FA	7	27.8	4.38	24	33
	14	47.2*	8.64	39	58		14	45.0*	10.63	30	60
	21	72.6*†	5.64	66	80		21	67.8*†	5.31	60	74
	28	77.6*†	6.11	68	84		28	73.0*†	5.91	66	82

*Significant difference vs. same group at 7 days.

†Significant difference vs. same group at 14 days.

‡Significant difference vs. same group at 21 days.



The Journal of Craniofacial Surgery

23. Val JE, Gómez-Moreno G, Ruiz-Linares M, Prados-Frutos JC, Gehrke SA, Calvo-Guirado JL. Effects of Surface Treatment Modification and Implant Design in Implants Placed Crestal and Subcrestally Applying Delayed Loading Protocol. *J Craniofac Surg.* 2017;28(2):552-558.

Abstract

The aim of this study is to evaluate the effect of the surface modification and cervical implant design on the bone remodeling in implants installed at the crestal and subcrestal bone level.

Materials and Methods

Ten American Fox Hound of approximately 1 year of age, each weighing approximately 14 to 15 kg, were used for this study. Two different dental implant macrodesign were used: cylindric-conical with 3.5mm of diameter and 9 in length (implant A) and conical with 2.9 mm of diameter and 9 mm in length (implant B). Two surfaces were used: sandblasting and acid etching (surface 1) and sandblasting and acid etching, then maintained in an isotonic solution of 0.9% sodium chloride (surface 2). Four groups were performed (n 1/4 20 implants): Group A1 (implant A with the surface 1), Group A2 (implant A with surface 2), Group B1 (implant B with surface 1), and Group B2 (implant B with surface 2). The mandibular premolars and molars (P1, P2, P3, M1) were removed and, after 2 months of healing, implants were inserted at the crestal and 2 mm subcrestal position related to the buccal bone level. Analysis was performed at 4 and 8 weeks. Histomorphometry with longitudinal measurements and bone implant contact, bone remodeling and implant stability quotient analysis were realized.

Results

Despite the roughness and morphology similarities between the groups, at the XPS evaluation, the FA group presented 2.3 times less carbon on the surface (FN: 27.3% and FA: 11.6%), sharply enhanced hydrophilicity and significantly enhanced BA and BIC at 14, 21 and 28 days of healing ($P < 0.05$) compared with the FN.

Conclusion

The data suggest that the hydrophilic FA accelerates the BA apposition and BIC interface around the implants during early stages of bone formation, providing highest degree of osseointegration.

Mean, median, standard deviation, minimum and maximum values of Bone area (BA) and bone-to-implant contact (BIC) for FN and FA groups after 7, 14, 21 and 28 days post-implantation

		Crestal		Subcrestal	
BIC (%)		Mean \pm SD	Median	Mean \pm SD	Median
4 weeks	Group A1	62.32 \pm 6.74	62.32	64.54 \pm 5.37*	54.54
	Group A2	56.93 \pm 5.17	56.93	59.23 \pm 4.12*	59.23
	Group B1	61.33 \pm 4.32	61.33	65.54 \pm 3.15	65.54
	Group B2	55.83 \pm 3.54	55.82	60.83 \pm 5.01	60.83
8 weeks	Group A1	65.34 \pm 5.16 [†]	65.34	69.43 \pm 1.93*, [†]	69.42
	Group A2	61.74 \pm 3.12 [†]	61.75	63.25 \pm 3.12 [†]	63.25
	Group B1	64.62 \pm 4.83 [†]	64.62	67.92 \pm 2.09*, [†]	67.93
	Group B2	60.73 \pm 4.95 [†]	60.73	63.52 \pm 2.91*, [†]	63.52

Data shows mean, SD, and medians.

* Comparison between crestal and subcrestal

[†] Comparison between 4 and 8 weeks. [*] Significant differences, P<0.05.

Bruner Langer Test of Linear Parameters Measured Values of the Crestal Implants Placement at 4 and 8 weeks Follow-up Period for the Groups

Linear (mm)	Measurements CRESTAL	PM-IS-BC		PM-IS-LC		IS-BC		IS-LC	
		Mean \pm SD	Median	Mean \pm SD	Median	Mean \pm SD	Median	Mean \pm SD	Median
4 weeks	Group A1	4.13 \pm 0.43	4.13	4.01 \pm 0.15	4.01	1.74 \pm 0.92	1.74	1.22 \pm 0.83	1.22
	Group A2	4.54 \pm 0.11* (P=0.015)	4.14	4.12 \pm 0.12	4.12	1.97 \pm 0.84	1.97	1.43 \pm 0.75	1.44
	Group B1	4.12 \pm 0.16	4.12	3.99 \pm 0.16	3.99	1.95 \pm 0.23	1.94	1.46 \pm 0.79	1.47
	Group B2	4.65 \pm 0.19* (P=0.024)	4.65	4.14 \pm 0.91*	4.14	2.06 \pm 0.73*	2.06	1.83 \pm 0.19*	1.83
8 weeks	Group A1	4.12 \pm 1.04	4.12	4.11 \pm 1.03	4.11	1.70 \pm 0.43	1.70	1.20 \pm 0.05	1.20
	Group A2	4.62 \pm 0.93* (P=0.022)	4.63	4.32 \pm 0.99*	4.32	2.04 \pm 0.95*	2.04	1.54 \pm 0.94*	1.53
	Group B1	4.19 \pm 1.64	4.19	4.01 \pm 0.23	4.00	1.99 \pm 1.40	1.99	1.49 \pm 1.03	1.49
	Group B2	4.87 \pm 1.03* (P=0.017)	4.88	4.16 \pm 1.02*	4.16	2.17 \pm 3.02*	2.17	2.30 \pm 2.01*	2.31

Data shows mean, SD, and medians, (IS-BC), distance between implant shoulder to buccal contact; (IS-LC), distance between implant shoulder to lingual contact; (PM-IS-BC), distance between the peri-implant mucosa and buccal implant shoulder, (PM-IS-LC), distance between the shoulder of the implant and the peri-implant lingual mucosa.

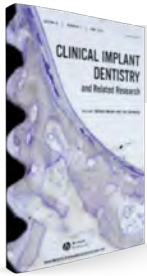* Significant differences, P<0.05.

Bruner Langer Test of Linear Parameters Measured Values of the Subcyrestal Implants Placement at 4 and 8 weeks Follow-up Period for the Groups

Linear (mm)	Measurements CRESTAL	PM-IS-BC		PM-IS-LC		IS-BC		IS-LC	
		Mean \pm SD	Median	Mean \pm SD	Median	Mean \pm SD	Median	Mean \pm SD	Median
4 weeks	Group A1	3.39 \pm 0.19	3.39	3.11 \pm 0.94	3.11	1.45 \pm 0.84	1.45	1.10 \pm 0.55	1.10
	Group A2	4.01 \pm 0.04*	4.01	3.92 \pm 0.49*	3.92	1.72 \pm 0.49*	1.72	1.63 \pm 0.44*	1.63
	Group B1	3.33 \pm 0.09	3.33	2.32 \pm 0.63	2.32	1.48 \pm 0.63	1.48	1.40 \pm 0.05	1.40
	Group B2	4.12 \pm 0.93*	4.12	4.54 \pm 0.99*	4.54	2.10 \pm 0.93*	2.10	1.91 \pm 0.67*	1.91
8 weeks	Group A1	3.42 \pm 2.31	3.42	3.40 \pm 2.14	3.40	1.61 \pm 0.08	1.62	1.54 \pm 0.92	1.54
	Group A2	4.44 \pm 1.03*	4.44	4.00 \pm 0.05*	4.00	1.94 \pm 0.30*	1.93	1.74 \pm 0.12*	1.74
	Group B1	3.38 \pm 0.41	3.38	3.62 \pm 0.08	3.62	1.93 \pm 1.06	1.93	1.70 \pm 2.04	1.70
	Group B2	4.01 \pm 0.18*	4.01	4.13 \pm 2.20*	4.13	2.31 \pm 2.05*	2.32	2.00 \pm 1.43*	2.01

Data shows mean, SD, and medians, (IS-BC), distance between implant shoulder to buccal contact; (IS-LC), distance between implant shoulder to lingual contact; (PM-IS-BC), distance between the peri-implant mucosa and buccal implant shoulder, (PM-IS-LC), distance between the shoulder of the implant and the peri-implant lingual mucosa.

* Significant differences, P<0.05.



Clinical Implant Dentistry and Related Research

24. Novellino MM, Sesma N, Zanardi PR, Laganá DC. Resonance frequency analysis of dental implants placed at the posterior maxilla varying the surface treatment only: A randomized clinical trial. *Clin Implant Dent Relat Res.* 2017;19(5):770-775.

Background

Chemical modifications of the dental implant surface that improve the wettability result in a faster and better osseointegration.

Purpose

The aim of this randomized clinical trial was to evaluate the implant stability quotient (ISQ) of implants with similar designs, treated with 2 surfaces, sandblasted acid-etched (SAE) and hydrophilic SAE, within the initial 16 weeks of healing.

Materials and Methods

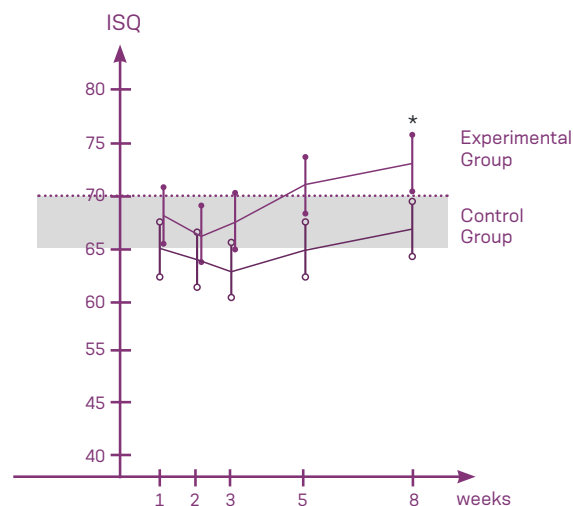
A total of 64 implants (32 SAE—control group and 32 modified SAE—test group) with the same design, length, and diameter (conical and compressive, 4.3 × 10 mm) were inserted into the posterior maxillae of 21 patients partially edentulous. The ISQ values were collected at post-surgery (T0), 1 week (T1), 2 weeks (T2), 3 weeks (T3), 5 weeks (T4), 8 weeks (T5), 12 weeks (T6), and 16 weeks (T7).

Results

None of the implants failed. Test group presented ISQ values higher than the control group (ANOVA— $P < .01$) from T5 to T7. When comparing groups regarding the amount of time required to achieve ISQ!70 as a reference, there was a statistically significant difference (cox regression— $P < .01$), and a hazard ratio of 2.24 (CI 1.62-3.11). At the 1-year follow-up, there was a drop out of 1 patient, and 2 implants were no longer evaluated. Survival rate for both groups was 100% at the 1-year follow-up.

Conclusion

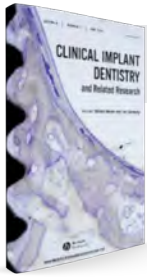The current study suggests that implants with hydrophilic surface (modified SAE) integrate faster than implants with SAE surface. The stability gain of the test group was 2.24 times faster than the control group after 5 weeks of evaluation at the posterior region of the edentulous maxillae.



Mean ISQ values and confidence interval of Acqua and Neoporos. Acqua presented ISQ values higher than the control group from T5 to T7.

E.

Immediate protocols and primary stability



Clinical Implant Dentistry and Related Research

25. Borges AF, Dias Pereira LA, Thomé G, Melo AC, de Mattias Sartori IA. Prostheses removal for suture removal after immediate load: success of implants. Clin Implant Dent Relat Res. 2010;12(3):244-8.

Purpose

The aim of this cohort study was to evaluate the success of implants after immediate loading in cases when the prostheses were removed for suture removal on the tenth day following implant placement. We describe a technique for fabricating effective definitive prostheses passively fitted to facilitate immediate load in edentulous patients.

Materials and Methods

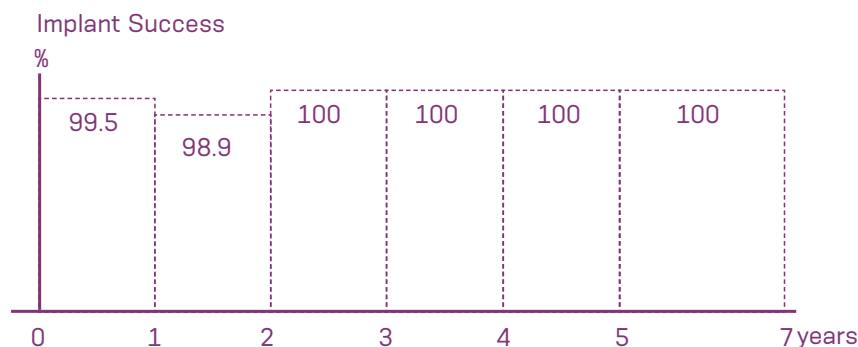
Seventy-one patients with resin-metal prostheses installed within less than 48 hours after implant placement were recalled. Patients for whom various amounts of time had elapsed since implant placement returned for follow-up. Time elapsed ranged from 6 months to 7 years. Stability of the implants was tested after prosthesis removal by horizontal and vertical percussion tests. Implant success was determined as the number of functional implants displaying no mobility.

Results

Follow-up revealed that all implants from each period evaluated were stable, with no mobility (100% of implants success), except for the 1-year time point (99.5%) and the 2-year time point (98.9%). No signs of inflammation and/or bleeding were observed.

Conclusion

Prosthesis removal for suture removal on the tenth day after implant placement represents a reliable and predictable procedure that did not jeopardize implant stability during bone remodeling.





26. Vieira RA, Melo AC, Budel LA, Gama JC, de Mattias Sartori IA, Thomé G. Benefits of rehabilitation with implants in masticatory function: is patient perception of change in accordance with the real improvement? *J Oral Implantol.* 2014;40(3):263-9.

Abstract

This study aimed to compare index of satisfaction and masticatory function of edentulous patients before and after rehabilitation and to evaluate if patient's perception of the changes in their oral health status are in agreement with the results of masticatory performance test. Fourteen edentulous patients were rehabilitated with lower implant-supported fixed prosthesis and upper removable dentures. Index of satisfaction and masticatory capacity (subjective analysis) and performance test (objective analysis) were evaluated before and 20 days and 8 months after rehabilitation. The patients were asked to respond a yes/no masticatory capacity questionnaire and to rate their oral satisfaction on a 0 to 10 Visual Analogue Scale (VAS). Masticatory performance test comprised the ability of the individual to pulverize an artificial test food (Optocal), after 20 and 40 masticatory strokes. When baseline answers were compared to 8 months after treatment answers, all questions, unless the ones that considered pain and social disability, were statistically different. Wilcoxon test was used to compare index of satisfaction before and after treatment. All answers showed statistically significant differences unless the one that referred to easiness to clean the prostheses. Considering the masticatory performance test, Student's t test (normally distributed) and Wilcoxon test (non-normally distributed) were used to test the null hypothesis that the weight of the particles of the test food left in sieves were equal in all times of evaluation. In the larger sieve with 20 cycles statistically significant differences were observed between baseline and 8 months, 20 days and 8 months. With 40 strokes, baseline and 20 days, baseline and 8 months and 20 days and 8 months showed significant differences. It was concluded that oral rehabilitation leads to better masticatory function in edentulous patients and there is a coincidence between patient perception and real improvement on masticatory function.




Brazilian Oral Research


27. Sotto-Maior BS, Lima Cde A, Senna PM, Camargos Gde V, Del Bel Cury AA. Biomechanical evaluation of subcrestal dental implants with different bone anchorages. *Braz Oral Res.* 2014;1(28):1-7.

Abstract

This study evaluated the biomechanical influence of apical bone anchorage on a single subcrestal dental implant using three-dimensional finite element analysis (FEA). Four different bone anchorage designs were simulated on a posterior maxillary segment using one implant with platform switching and internal Morse taper connection (Neodent CM) as follows: 2 mm subcrestal placement with (SW) or without (SO) the implant apex engaged into the cortical bone or position at bone level with anchorage only in the crestal cortical (BO) bone or with bicortical fixation (BW). Each implant received a premolar crown, and all models were loaded with 200 N to simulate centric and eccentric occlusion. The peak tensile and compressive stress and strain were calculated at the crestal cortical, trabecular, and apical cortical bone. The vertical and horizontal implant displacements were measured at the platform level. FEA indicated that subcrestal placement (SW and SO) created lower stress and strain in the crestal cortical bone compared with crestal placement (BO and BW models). The SW model exhibited lesser vertical and horizontal implant micromovement compared with the SO and BO models under eccentric loading; however, stress and strain were higher in the apical cortical bone. The BW model exhibited the lowest implant displacement. These results indicate that subcrestal placement decreases the stress in the crestal cortical bone of dental implants, regardless of apical anchorage; however, apical cortical anchorage can be effective in limiting implant displacement. Further studies are required to evaluate the effects of possible remodeling around the apex on the success of subcrestal implants.

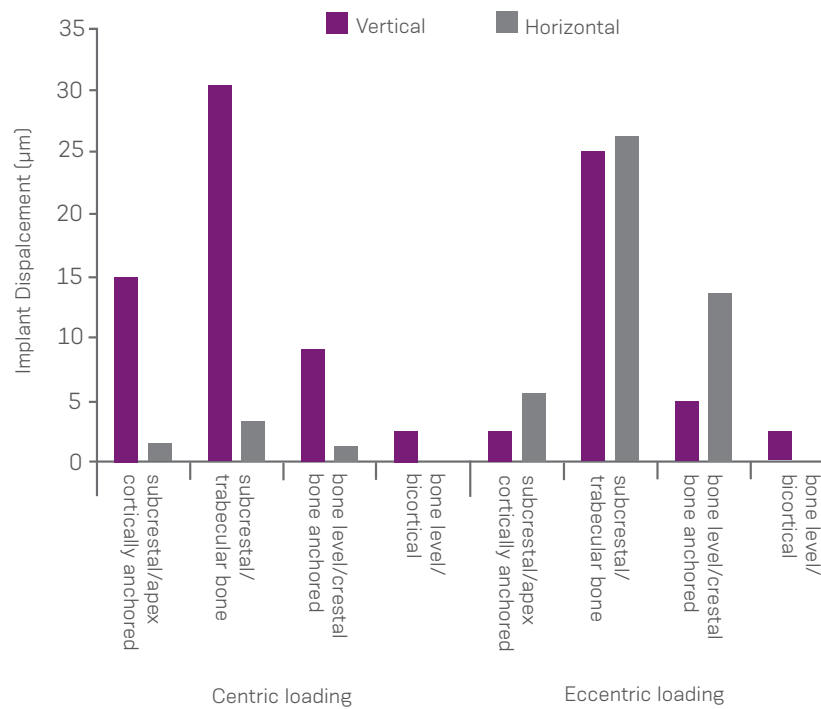


Compressive stress (MPa) around implants with different anchorage designs under centric loading.



Compressive stress (MPa) around implants with different anchorage designs under eccentric loading.

Region	Model	Peak tensile stress	Peak compressive stress	Strain
Crestal cortical bone	subcrestal/apex cortically anchored	86.8	56.8	0.0045
	subcrestal/trabecular bone	24.6*	34.1	0.0016*
	bone level/crestal bone anchored	67.4	119.2*	0.0048
	bone level/bicortical	66.6	127.4	0.0038
Trabecular bone	subcrestal/apex cortically anchored	85.2	65.6	0.2210*
	subcrestal/trabecular bone	39.0	54.3	0.1460
	bone level/crestal bone anchored	60.9	46.3	0.0750
	bone level/bicortical	12.9*	17.6*	0.1079
Apical cortical bone	subcrestal/apex cortically anchored	124.2*	527.8*	0.0167*
	subcrestal/trabecular bone	6.6	6.7	0.0026
	bone level/crestal bone anchored	14.4	14.9	0.0005
	bone level/bicortical	24.3	61.5	0.0014



Vertical and horizontal implant displacement (µm) during centric and eccentric loading simulations.



Clinical Oral Investigations

28. Valente ML, de Castro DT, Shimano AC, Lepri CP, Dos Reis AC. Analysis of the influence of implant shape on primary stability using the correlation of multiple methods. Clin Oral Investig. 2015;19(8):1861-6.

Objectives

The purpose of this study was to analyze the influence of the shape of various implants and the density of substrate on primary stability using a combination of methods.

Materials and Methods

Fifty-four Neodent® brand cylindrical and conical implants with different prosthetic platforms were used. Implants were inserted into a pork rib bone and polyurethane blocks. Primary stability was assessed by insertion torque (IT), resonance frequency analysis (RFA), and pullout strength. Screws were also analyzed by scanning electron microscopy (SEM) before insertion and after removal to justify their use for inserting in different substrates.

Results

The conical cone morse implant had the highest average for all of the assays performed and was significantly different ($p < 0.05$) from the cylindrical implants for IT in the bone, pullout strength in the 40 per cubic foot (PCF) polyurethane, and the bone. The internal hex cylindrical implant had the lowest averages, which were significantly different ($p < 0.05$) from the conical implants for IT and RFA in the bone, pullout strength in the 40 PCF polyurethane, and the bone. The IT, RFA, and pullout strength assays were moderately correlated, and the photomicrographs did not reveal changes in the implants.

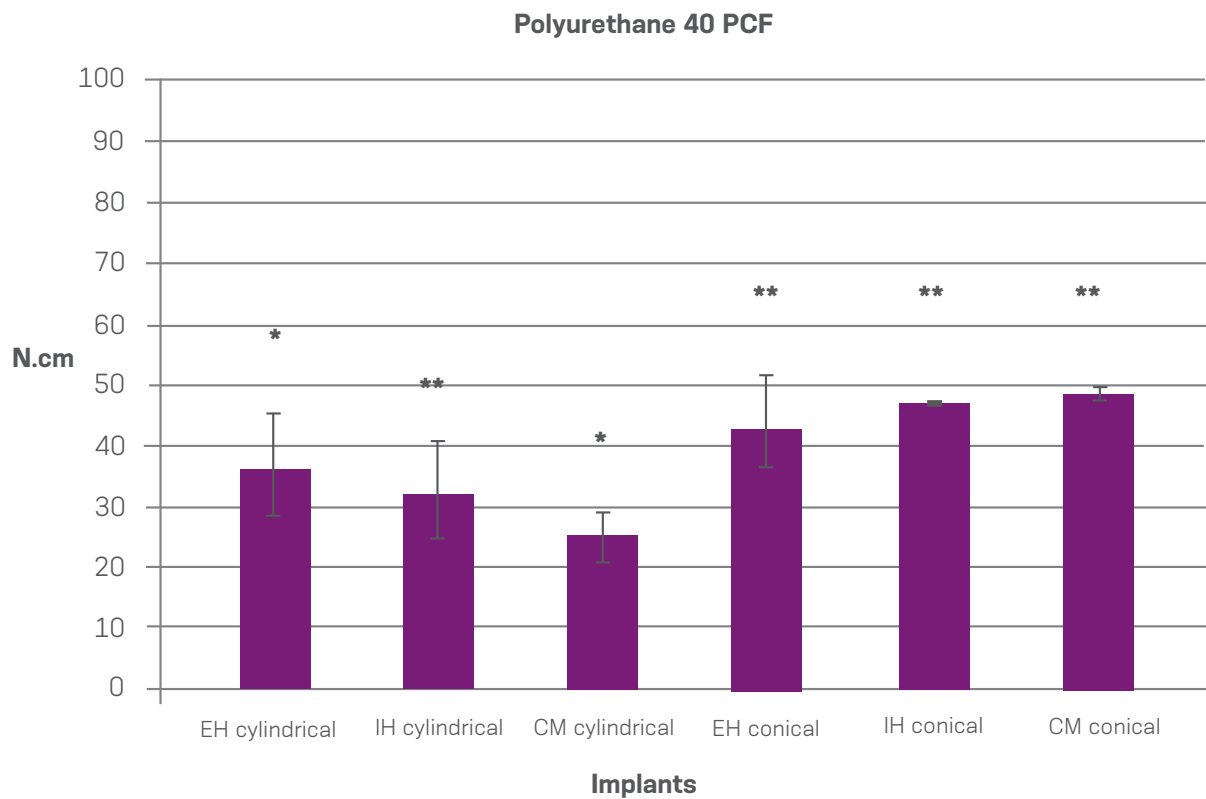
Conclusion

The analysis of different implants showed a better primary stability of tapered implants; the density of the substrate influences the primary stability and the 15 PCF polyurethane was not adequate to evaluate primary stability; correlation was obtained between the different methodologies of analysis of primary stability.

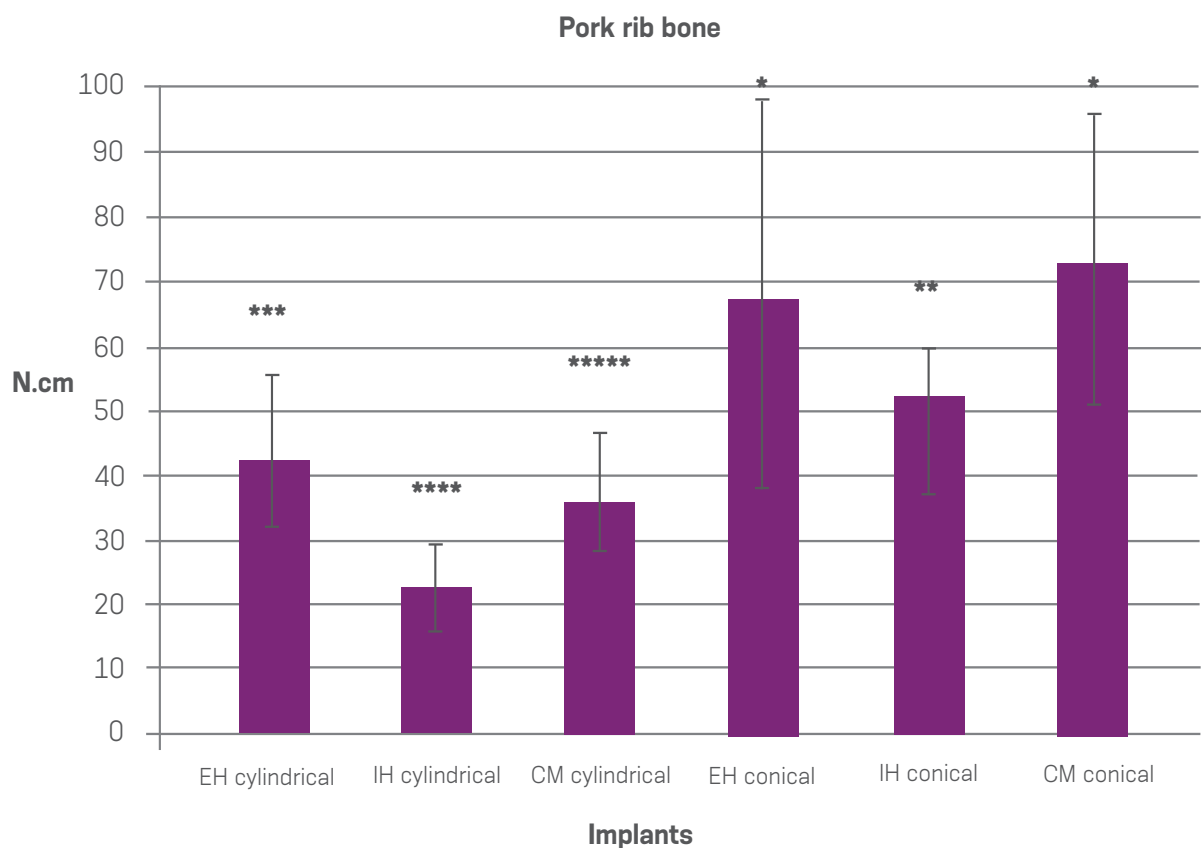
Clinical Relevance

The study shows the influence of different implant macro-geometries and densities of substrates on primary stability.

Mean and standard deviation of insertion torque (N.cm) of the implants inserted in polyurethane 40 PCF:



Mean and standard deviation of insertion torque (N.cm) of the implants inserted in pork rib:





The Journal of Prosthetic Dentistry

29. Able FB, de Mattias Sartori IA, Thomé G, Moreira Melo AC. Retrospective, cross-sectional study on immediately loaded implant-supported mandibular fixed complete-arch prostheses fabricated with the passive fit cementation technique. *J Prosthet Dent.* 2018;119(1):60-66.

Statment of Problem

Mandibular fixed complete-arch dental prostheses on dental implants have been benefiting patients for a long time, but problems with passive fitting between the metallic framework of the prostheses and the implants might influence its long-term success.

Objectives

The purpose of this cross-sectional study of immediately loaded mandibular fixed complete-arch dental prostheses was to evaluate the survival and success rates of prostheses, the survival rates of dental implants, the occurrence of complications in the prostheses and implants, participant satisfaction, and the association between cantilever length and prosthesis complications.

Materials and Methods

Data were collected from the participants' records. The exposure variables were participant related (sex and age) and treatment related (number of implants and length of cantilever). The outcome variables were the survival and success of the prostheses and implants, complications, and participant satisfaction. The Fisher or chi-square tests was used for the association between 2 qualitative variables ($\alpha=.05$).

Results

Two hundred ninety consecutive participants (1429 implants) with a mean follow-up time of 4.4 years were included. The survival rate for the prostheses was 98.6 and the success rate was 96.6%. The implant survival rate was 99.6%. Sixty-seven participants experienced a prosthetic complication, the most common being tooth fracture. Only 2.45% ($n=35$) of the implants were associated with screw loosening. Of the total number of participants, 86.9% were completely satisfied with their treatment. The length of the cantilever (up to 25 mm) was not associated with complications ($P>.05$).

Conclusion

Implant-supported mandibular fixed complete-arch dental prostheses fabricated with a passive fit technique provide successful treatment for patients with edentulism. The success and survival rates of implants and prostheses were high. Only straightforward complications were observed. Cantilever length was not associated with complications.

Cantilever length versus implant complication

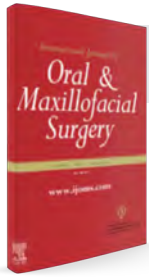Implant Complications	Right Cantilever Length (mm)		
	<15	15 to 20	21 to 25
No, n (%)	162 (97.01)	107 (95.54)	11 (100.00)
Yes, n (%)	5 (2.99)	5 (4.46)	0
Total	167	112	11
P	.748*		

Implant Complications	Left Cantilever Length (mm)		
	<15	15 to 20	21 to 25
No, n (%)	153 (95.63)	111 (98.23)	16 (94.12)
Yes, n (%)	7 (4.38)	2 (1.77)	1 (5.88)
Total	160	113	17
P	.520*		

*Adjusting for age, sex, and number of implants: right cantilever length (P=.797); left cantilever length (P=.887); logistic regression model and Wald test, $\alpha=.05$. Cantilever length <15 versus ≥ 15 mm (Fisher exact test, $\alpha=.05$).

F.

Case reports about clinical success



The International Journal of Oral Maxillofacial Surgery

30. Sartori EM, Padovan LE, de Mattias Sartori IA, Ribeiro PD Jr, Gomes de Souza Carvalho AC, Goiato MC. Evaluation of satisfaction of patients rehabilitated with zygomatic fixtures. *J Oral Maxillofac Surg.* 2012;70(2):314-9.

Purpose

The aim of this study was to evaluate the satisfaction of patients rehabilitated with zygomatic fixtures and prosthesis with immediate loading.

Materials and Methods

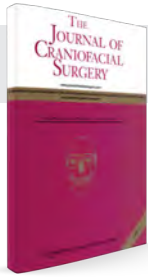The study selected patients who were rehabilitated with zygomatic implants (Neodent) at the clinic of the Latin American Institute for Dental Research and Education (ILAPEO, Curitiba-PR, Brasil) between 2005 and 2009. The patients were asked to answer a control-questionnaire during their follow-up visits. Data were collected regarding the level of patient satisfaction, reason for dissatisfaction, number of post-operative clinical sessions, and the type of complication. Sixteen patients were selected: 10 females and 6 males.

Results

Half of the patients were completely satisfied while the other half were satisfied with some complaints. The complaints were related to hygiene, esthetics, phonetics, and discomfort during chewing. Regarding the post-operative evaluation, 50% of the patients were attended due to the prosthesis (62.5%) and the implant (37.5%).

Conclusion

The treatment with zygomatic fixtures is predictable and reliable. The patients were satisfied both with implants and prosthesis.



The Journal of Craniofacial Surgery

31. Suzuki D, Bassi AP, Lee HJ, Alcântara PR, de Sartori IM, Luvizuto ER, Faco EF, Faot F. Inferior alveolar nerve lateralization and implant placement in atrophic posterior mandible. J Craniofac Surg. 2012;23(4):e347-9.

Abstract

The aims of this article were to describe the surgical technique of the inferior alveolar nerve lateralization followed by implant (Neodent) installation by means of a clinical report and also to discuss the importance of an adequate surgical and prosthetic planning for atrophic posterior mandible rehabilitation.




Academy of General Dentistry

32. Faot F, Hermann C, Sartori EM, Bassi AP. Tilted implants and prototyping: a security option for improving the anchorage in atrophic maxilla. *Gen Dent.* 2013;61(2):28-31.

Abstract

Rehabilitating atrophic maxilla poses many challenges. Reconstructive techniques that require sinus grafting are viable and acceptable; however, these techniques also are considered to be expensive, invasive, and time-consuming. Tilted implants anchored in distal areas using available bone have been reported as a less invasive and highly predictable treatment option. This article presents a case involving implant (Neodent) anchorage via tilted implants as an alternative technique to bone grafting procedures.



The International Journal of Prosthodontics

33. Aparecida de Mattias Sartori I, Uhlendorf Y, Padovan LE, Junior PD, Melo AC, Tiossi R. Attachment-retained gingival prosthesis for implant-supported fixed dental prosthesis in the maxilla: a clinical report. *J Prosthodont.* 2014;23(8):654-8.

Abstract

The rehabilitation of edentulous maxillae is a complex procedure due to the involvement of esthetic and functional requirements. A trial maxillary denture can be used to identify the need for adequate upper lip support when replacing removable complete dentures by implant-fixed dental prostheses. This clinical report describes the outcome of the rehabilitation of an edentulous atrophic maxilla with unfavorable maxillomandibular relationship and deficient upper lip support. A trial denture was fabricated and used to diagnose the need for a prosthesis capable of restoring the upper lip support. The reduced upper lip support was also confirmed by a lateral cephalogram. The patient was rehabilitated by an implant-fixed dental prosthesis associated with an attachment-retained gingival prosthesis. The case presented shows that when loss of upper lip support is detected and the patient does not wish to undergo further surgical reconstruction procedure, the retention of a gingival prosthesis using a ball attachment is a satisfactory treatment option.



The International Journal of Oral & Maxillofacial Implants

34. Luiz J, Padovan LE, Claudino M. Recombinant human bone morphogenetic protein 2 in augmentation procedures: case reports. *Int J Oral Maxillofac Implants*. 2014;29(5):1198-203.

Abstract

To successfully rehabilitate edentulous patients using endosseous implants, there must be enough available bone. Several techniques have been proposed for augmentation of sites with insufficient bone volume. Although autogenous bone has long been considered the gold standard for such procedures, the limited availability of graft material and a high morbidity rate are potential disadvantages of this type of graft. An alternative is to use recombinant human bone morphogenetic protein 2 (rhBMP-2), which is able to support bone regeneration in the oral environment. These case demonstrate the applicability of rhBMP-2 in maxillary sinus elevation and augmentation procedures in the maxilla to enable dental implant placement. The use of rhBMP-2 in alveolar augmentation procedures had several clinical benefits for these patients.



35. Jamcoski VH, Faot F, de Mattias Sartori IA, Vieira RA, Tiossi R. Occlusal concepts application in resolving implant prosthetic failure: case report. *J Oral Implantol.* 2014;40(2):203-10.

Abstract

The prosthetic management of a poor implant treatment is presented in this case report. The recommended occlusion concepts for implant-supported prostheses were applied for the resolution of the case. The rehabilitation of the posterior segments provided a mutually protected occlusion with adequate distribution of the axial and lateral bite forces with stable posterior occlusion. The clinical exam indicated the need for modification in the vertical dimension of occlusion. Sufficient interocclusal rest space was present to test the alteration in the vertical dimension. The aim was to achieve an occlusion scheme that followed four specific criteria: (1) centric contacts and centric relation of the jaw-to-jaw position; (2) anterior guidance only; (3) shallow anterior angle of tooth contact; and (4) vertical dimension of occlusion with acceptable tooth form and guidance. The success of an oral rehabilitation relies in following the aforementioned criteria, appropriate interaction between the dental laboratory technician and the clinician, careful elaboration of the provisional rehabilitation with all the desired details to be reproduced in the final prosthetic restoration and sufficient follow-up time of the provisional prostheses before placing the final restoration.



36. Padovan LE, Ribeiro-Júnior PD, de Mattias Sartori IA, Thomé G, Sartori EM, Uhlenndorf J. Multiple zygomatic implants as an alternative for rehabilitation of the extremely atrophic maxilla: a case letter with 55 months of follow-up. *J Oral Implantol.* 2015 Feb;41(1):97-100.

Introduction

Zygomatic implants have been considered an alternative treatment for prosthetic rehabilitation of patients with an atrophied maxilla without bone augmentation. These fixtures were introduced by Branemark in 1988, ranging in length from 30 mm to 52.5 mm and designed to be anchored in zygomatic bone.⁴ These implants have also been widely used for rehabilitation of maxillary defects as a result of tumor resections, congenital defects, trauma, and cases of severe atrophy of the maxilla. Indeed, the applicability of zygomatic implants represents a simplification of the conventional treatment of atrophic maxillae, which is based in bone augmentation procedures associated with dental implant placement. Therefore, these implants involve a less invasive surgical technique, reduction of costs, and treatment duration, compared to conventional rehabilitation of atrophic maxillae.

Case Report

A 78-year-old male patient was referred to the Latin American Institute of Dental Research and Education complaining of an unstable maxillary complete denture (Figure 1). The medical record includes a history of chronic sinusitis. However, the patient also related the absence of symptoms for a long time and no evidence of opacification of the maxillary sinus were detected in computerized tomography evaluation (Figure 2). Clinical, radiographical and tomographical examinations revealed absence of all teeth in the maxilla and the presence of an osseointegrated nonfunctional implant in the region corresponding to tooth #1. This implant was not removed in order to avoid communications or bone resorption in this region. Moreover, it was detected that there was extensive bone resorption with bilateral pneumatization of the maxillary sinuses aggravated by the previous use of a subperiosteal implant (Figure 2). In the mandible, the following teeth were missing: #18, #19, #20, #21, #22, #23, #24, #25, #26, and #30. Teeth #31, #29, #28, and #27 had severe periodontal disease with mobility. There was also the presence of 3 osseointegrated implants in regions corresponding to teeth #26, #22, and #20, which supported a metal-ceramic fixed prosthesis replacing teeth #26, #25, #24, #23, #22, #21, #20, and #19. In the region corresponding to tooth #31, there was a fractured metal pin.

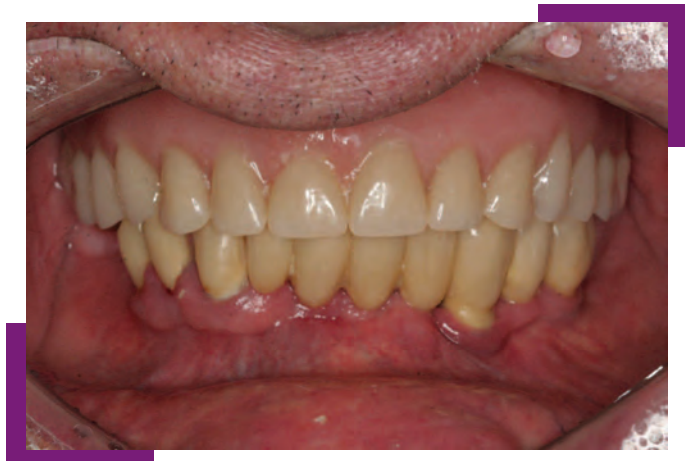

Figure 1. Initial clinical aspect.

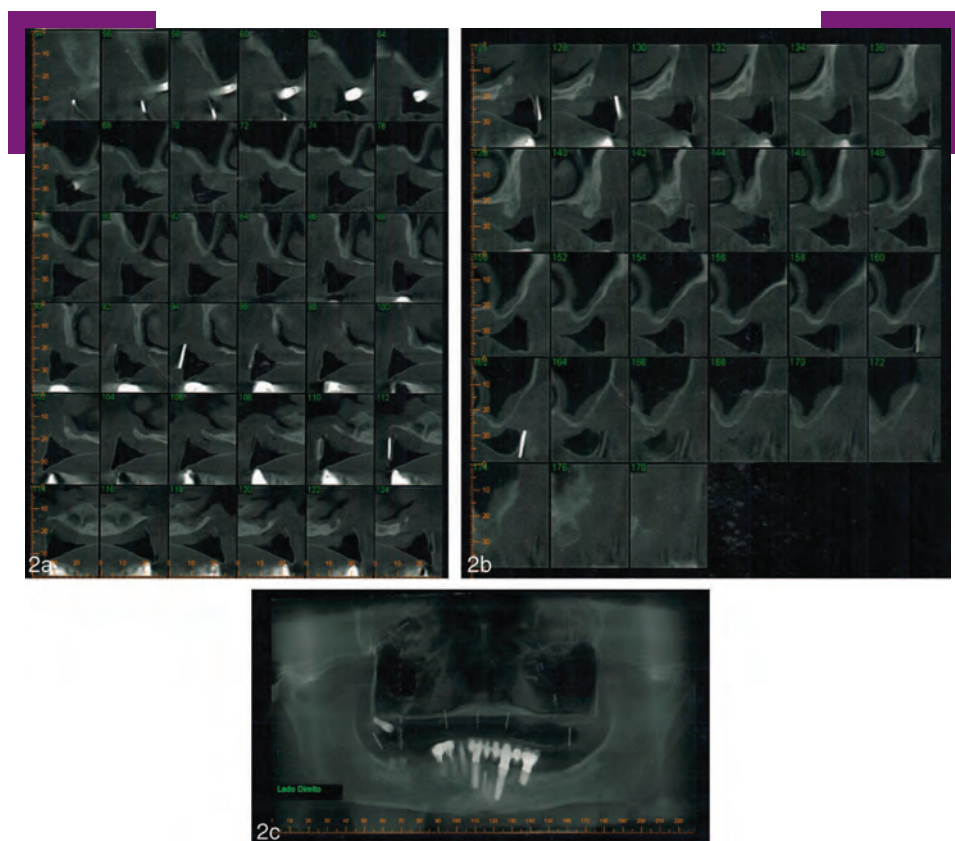

Figure2. Initial cone beam computed tomography. (a) and (b) refers to transversal reconstruction and (c) panoramic reconstruction. Observe the severe maxillary atrophy, bilateral pneumatization, and the absence of opacification of the maxillary sinuses.

A treatment plan was based upon the placement of 3 zygomatic implants in the right maxilla and 1 zygomatic and 2 conventional implants in the left maxilla. Prosthetic planning was performed prior to initiation of the surgical procedures.

Initially, teeth #31, #29, #28, and #27 were extracted and the prosthesis was removed. Two implants with Morse taper interface (Alvim CM, Neodent, Curitiba, Brazil) were placed in the regions corresponding to teeth #27 and #28, and implant-supported fixed prosthesis was installed.

In the next phase, surgical procedures were performed in the maxilla under general anesthesia. Initially, a mucoperiosteal incision was performed above the maxillary mucogingival line, from the region corresponding to teeth positions #3 to #7 and the region of teeth positions #14 to #10. Thus, 3 zygomatic implants with Morse taper interface were installed on the right side (Figure 3), 1 zygomatic implant with a Morse cone platform on the left side and 2 cylindrical implants interface (Titamax CM, Neodent, Curitiba, Brazil) in the region of teeth positions #12 and #13 (Figure 4). An installation torque greater than 40 N.cm was obtained in the placement of all implants, allowing the use of immediate load protocol. Mini-pilar and transepithelial abutments (Neodent, Curitiba, PR, Brazil) were installed on the conventional and zygomatic implants, respectively (Figure 5). Postoperatively, the use of antibiotic (amoxicillin, 500 mg), anti-inflammatory (ibuprofen, 600 mg) and analgesic (paracetamol, 750 mg) drugs were prescribed. Clinical, radiographical and tomographical examinations revealed absence of all teeth in the maxilla and the presence of an osseointegrated nonfunctional implant in the region corresponding to tooth #1.

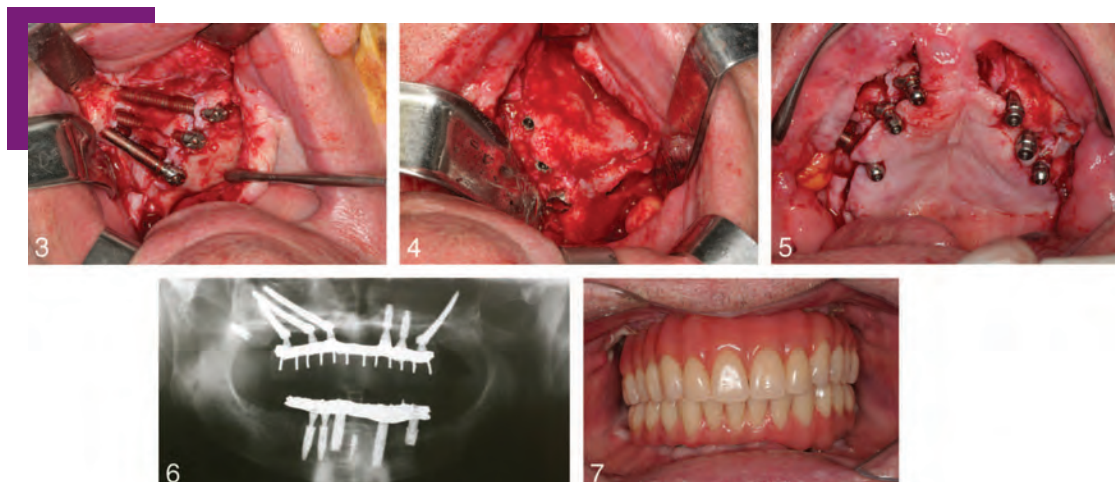


Figure 3-7. Placement of 3 zygomatic implants in the right maxilla using immediate loading. Figure 4. Placement of 1 zygomatic implant and 2 conventional implants in the left maxilla using immediate loading. Figure 5. Placement of abutments and protective caps. Observe the formation of a polygon. Figure 6. Immediate postoperative panoramic radiograph of the maxilla. Figure 7. Installation of complete maxillary metal-resin prosthesis over implants in the maxilla.

This implant was not removed in order to avoid communications or bone resorption in this region. Moreover, it was detected that there was extensive bone resorption with bilateral pneumatization of the maxillary sinuses aggravated by the previous use of a subperiosteal implant (Figure 2). In the mandible, the following teeth were missing: #18, #19, #20, #21, #22, #23, #24, #25, #26, and #30. Teeth #31, #29, #28, and #27 had severe periodontal disease with mobility. There was also the presence of 3 osseointegrated implants in regions corresponding to teeth #26, #22, and #20, which supported a metal-ceramic fixed prosthesis replacing teeth #26, #25, #24, #23, #22, #21, #20, and #19. In the region corresponding to tooth #31, there was a fractured metal pin.

Postoperative follow-up was performed at 9 (Figure 8), 17 (Figure 9), 28 (Figure 10), 36 (Figure 11), and 55 months (Figure 12), including clinical and radiographical examinations.

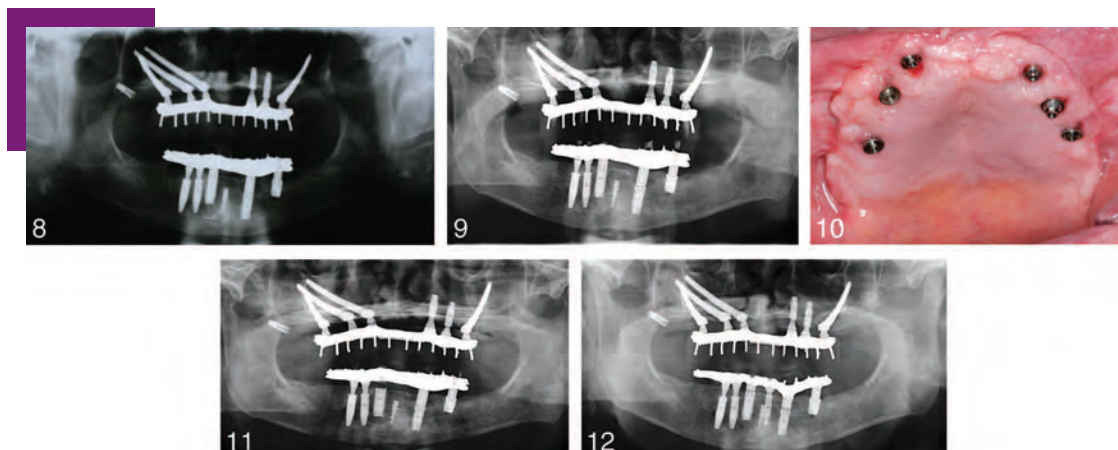


Figure 8. Radiographical follow-up at 9 months postsurgery. Figure 9. Radiographical follow-up at 17 months postsurgery. Figure 10. Clinical follow-up at 28 months postsurgery. Figure 11. Radiographical follow-up at 36 months postsurgery. Figure 12. Radiographical follow-up at 55 months postsurgery.

Taken together, these findings suggest that the use of multiple zygomatic implants in the rehabilitation of extremely atrophic maxilla is a safe and predictable technique, an excellent alternative to bone augmentation procedures. However, the placement of these fixtures must be considered a complex surgical procedure and requires experienced surgeons, considering that important anatomic structures may be involved.

Case Report Dentistry

37. Faot F, Thomé G, Bielemann AM, Hermann C, Melo ACM, Padovan LEM, Sartori IAM. Simplifying the Treatment of Bone Atrophy in the Posterior Regions: Combination of Zygomatic and Wide-Short Implants—A Case Report with 2 Years of Follow-Up.

Abstract

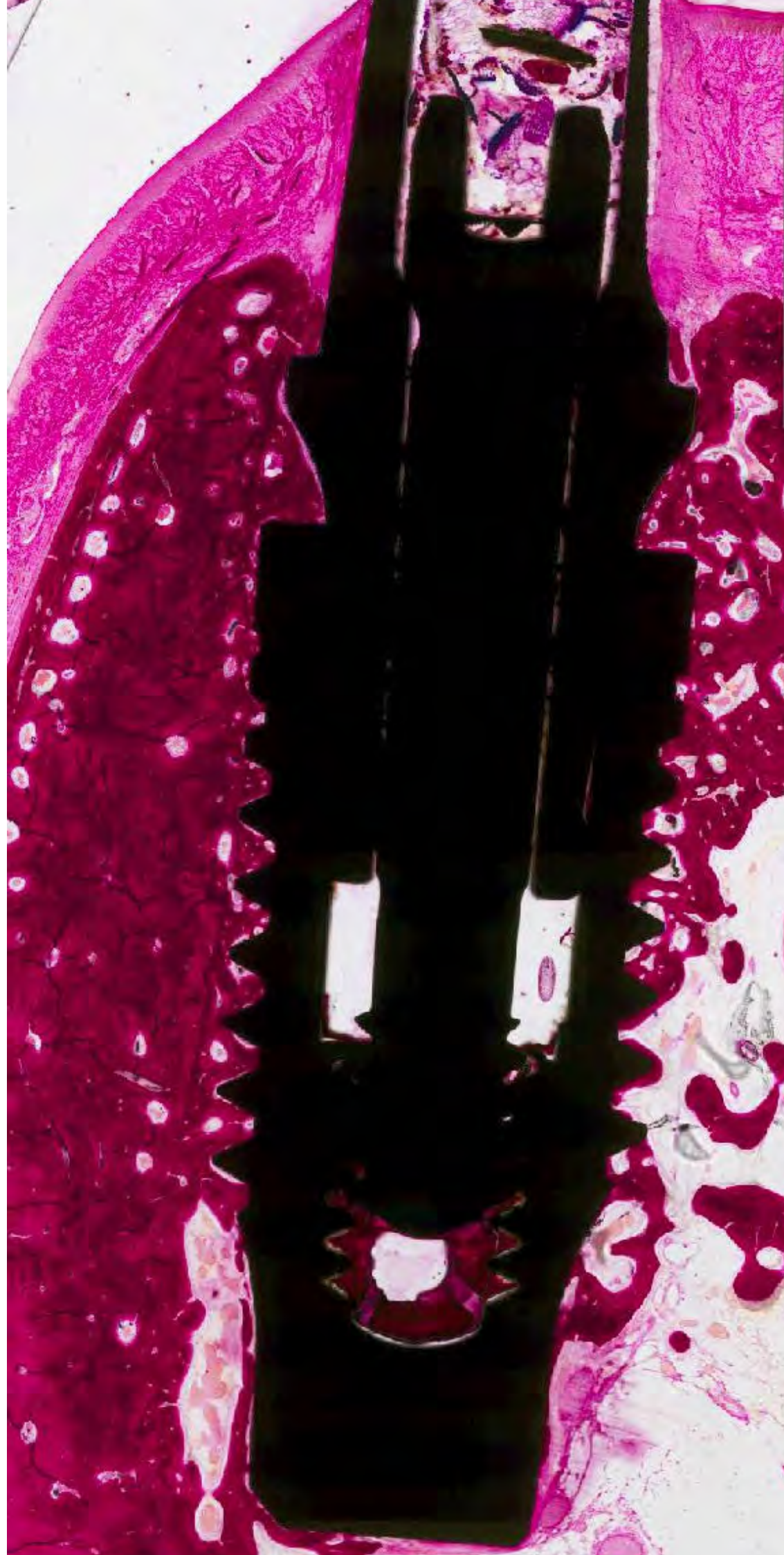
The rehabilitation of maxillary and mandibular bone atrophy represents one of the main challenges of modern oral implantology because it requires a variety of procedures, which not only differ technically, but also differ in their results. In the face of limitations such as deficiencies in the height and thickness of the alveolar structure, prosthetic rehabilitation has sought to avoid large bone reconstruction through bone grafting; this clinical behavior has become a treatment system based on evidence from clinical scientific research. In the treatment of atrophic maxilla, the use of zygomatic implants has been safely applied as a result of extreme technical rigor and mastery of this surgical skill. For cases of posterior mandibular atrophy, short implants with a large diameter and a combination of short and long implants have been recommended to improve biomechanical resistance. These surgical alternatives have demonstrated a success rate similar to that of oral rehabilitation with the placing of conventional implants, allowing the adoption of immediate loading protocol, a decrease in morbidity, simplification and speed of the treatment, and cost reduction. This case report presents complete oral rehabilitation in a patient with bilateral bone atrophy in the posterior regions of the maxilla and mandible with the goal of developing and increasing posterior occlusal stability during immediate loading.

REFERENCES

01. de Siqueira RAC, Fontão FNGK, Sartori IAM, Santos PGF, Bernardes SR, Tiossi R. Effect of different implant placement depths on crestal bone levels and soft tissue behavior: a randomized clinical trial. *Clin Oral Implants Res.* 2017;28(10):1227-1233.
02. Sumiyassu, S et al. Tissue response around morse taper and external hexagon implants: preliminary results of a randomeized split- mouth design. *SALUSVITA.* 2013; 32(1):09-24.
03. Castro DS, Araujo MA, Benfatti CA, Araujo C dos R, Piattelli A, Perrotti V, Iezzi G. Comparative histological and histomorphometrical evaluation of marginal bone resorption around external hexagon and Morse cone implants: an experimental study in dogs. *Implant Dent.* 2014;23(3):270-6
04. Martin C, Thomé G, Melo AC, Fontão FN. Peri-implant bone response following immediate implants placed in the esthetic zone and with immediate provisionalization-a case series study. *Oral Maxillofac Surg.* 2015;19(2):157-63.
05. Novaes AB Jr, Barros RR, Muglia VA, Borges GJ. Influence of interimplant distances and placement depth on papilla formation and crestal resorption: a clinical and radiographic study in dogs. *J Oral Implantol.* 2009;35(1):18-27
06. Barros RRM, Novaes AB Jr, Muglia VA, Iezzi G, Piattelli A. Influence of interimplant distances and placement depth on peri-implant bone remodeling of adjacent and immediately loaded Morse cone connection implants: a histomorphometric study in dogs. *Clin Oral Implants Res.* 2010;21(4):371-8.
07. Melo LA, Souza MBC, Barbosa GAS, Carreiro ADFP. Peri-Implant Bone Loss of External Hexagon and Morse Taper in Patients Wearing Immediately Loaded Overdentures. *Braz Dent J.* 2017;28(6):694-698.
08. dos Anjos CM, Harari ND, Reis RSA, Vidigal Junior GM. Análise in vitro da infiltração bacteriana na interface de pilares protéticos e implantes cone-morse / In vitro analysis of bacterial leakage at the interface between Morse taper implant platform and prosthetic abutments. *ImplantNews*;8(2):239-243, 2011.
09. Resende CC, Castro CG, Pereira LM, Prudente MS, Zancopé K, Davi LR, Penatti MP, das Neves FD. Influence of the Prosthetic Index Into Morse Taper Implants on Bacterial Microleakage. *Implant Dent.* 2015;24(5):547-51
10. Bernardes SR, da Gloria Chiarello de Mattos M, Hobkirk J, Ribeiro RF. Loss of preload in screwed implant joints as a function of time and tightening/untightening sequences. *Int J Oral Maxillofac Implants.* 2014;29(1):89-96.
11. González RC, Shimizu RH, Hermann C, Sartori IAM. Efeito de diferentes níveis de torques na resistência ao destorque do parafuso e dos pilares de duas peças em junções cone-morse. Estudo in vitro / The effect of different torque levels on detorque resistance of a two-piece, cone Morse abutment and screw. An in vitro study *ImplantNews*; 11(4): 444-450, 2014.
12. Coppedê AR, Bersani E, de Mattos Mda G, Rodrigues RC, Sartori IA, Ribeiro RF. Fracture resistance of the implant-abutment connection in implants with internal hex and internal conical connections under oblique compressive loading: an in vitro study. *Int J Prosthodont.* 2009;22(3):283-6.
13. Castro CG, Zancopé K, Veríssimo C, Soares CJ, Neves FD. Strain analysis of different diameter Morse taper implants under overloading compressive conditions. *Braz Oral Res.* 2015;29(1):16.

14. Lillo R, Parra C, Fuentes R, Borie E, Engelke W, Beltrán V. Compressive Resistance of Abutments with Different Diameters and Transmucosal Heights in Morse-Taper Implants. *Brazilian Dental Journal*. 2015;26(2): 156-159.
15. Gois-Santos VT, Trento CL, dos Santos SV, RCS Santos, Santos SV, Griza S. Analysis of resistance to fatigue between straight solid and anatomic abutments of Morse taper system. *Rev Odontol UNESP*. 2016; 45(5): 271-276.
16. Xavier SP, Ikuno KE, Tavares MG. Enhanced bone apposition to Brazilian microrough titanium surfaces. *Braz Dent J*. 2010;21(1):18-23.
17. Alves MLM, Iwaki Filho L, Sábio S, Zen Filho EV, Soares S. Avaliação da estabilidade de implantes curtos Neodent, tipo Cone Morse, por meio do teste do torque reverso: estudo preliminar em coelhos / Assessing stability of Neodent Morse taper implants through reverse torque technique testing: a preliminary study in rabbits. *Dent press implantol*. 2014;8(4): 94-101.
18. Sartori IAM, Latenek RT, Budel LA, Thomé G, Bernardes SR, Tiossi R. Retrospective analysis of 2,244 implants and the importance of follow-up in implantology. *JDR*. 2014;2(6): 555-565.
19. Sartoretto SC, Alves AT, Resende RF, Calasans-Maia J, Granjeiro JM, Calasans-Maia MD. Early osseointegration driven by the surface chemistry and wettability of dental implants. *J Appl Oral Sci*. 2015;23(3):279-87.
20. Dias RR, Sehn FP, de Santana Santos T, Silva ER, Chaushu G, Xavier SP. Corticocancellous fresh-frozen allograft bone blocks for augmenting atrophied posterior mandibles in humans. *Clin Oral Implants Res*. 2016;27(1):39-46.
21. Dinato TR, Grossi ML, Teixeira ER, Dinato JC, Sczepanik FS, Gehrke SA. Marginal Bone Loss in Implants Placed in the Maxillary Sinus Grafted With Anorganic Bovine Bone: A Prospective Clinical and Radiographic Study. *J Periodontol*. 2016;87(8):880-7.
22. Sartoretto SC, Alves ATNN, Zarranz L, Jorge MZ, Granjeiro JM, Calasans-Maia MD. Hydrophilic surface of Ti6Al4V-ELI alloy improves the early bone apposition of sheep tibia. *Clin Oral Implants Res*. 2017;28(8):893-901.
23. Val JE, Gómez-Moreno G, Ruiz-Linares M, Prados-Frutos JC, Gehrke SA, Calvo-Guirado JL. Effects of Surface Treatment Modification and Implant Design in Implants Placed Crestal and Subcrestally Applying Delayed Loading Protocol. *J Craniofac Surg*. 2017;28(2):552-558.
24. Novellino MM, Sesma N, Zanardi PR, Laganá DC. Resonance frequency analysis of dental implants placed at the posterior maxilla varying the surface treatment only: A randomized clinical trial. *Clin Implant Dent Relat Res*. 2017;19(5):770-775.
25. Borges AF, Dias Pereira LA, Thomé G, Melo AC, de Mattias Sartori IA. Prostheses removal for suture removal after immediate load: success of implants. *Clin Implant Dent Relat Res*. 2010;12(3):244-8.
26. Vieira RA, Melo AC, Budel LA, Gama JC, de Mattias Sartori IA, Thomé G. Benefits of rehabilitation with implants in masticatory function: is patient perception of change in accordance with the real improvement? *J Oral Implantol*. 2014;40(3):263-9.
27. Sotto-Maior BS, Lima Cde A, Senna PM, Camargos Gde V, Del Bel Cury AA. Biomechanical evaluation of subcrestal dental implants with different bone anchorages. *Braz Oral Res*. 2014;1(28):1-7.

28. Valente ML, de Castro DT, Shimano AC, Lepri CP, Dos Reis AC. Analysis of the influence of implant shape on primary stability using the correlation of multiple methods. *Clin Oral Investig*. 2015;19(8):1861-6.
29. Able FB, de Mattias Sartori IA, Thomé G, Moreira Melo AC. Retrospective, cross-sectional study on immediately loaded implant-supported mandibular fixed complete-arch prostheses fabricated with the passive fit cementation technique. *J Prosthet Dent*. 2018;119(1):60-66.
30. Sartori EM, Padovan LE, de Mattias Sartori IA, Ribeiro PD Jr, Gomes de Souza Carvalho AC, Goiato MC. Evaluation of satisfaction of patients rehabilitated with zygomatic fixtures. *J Oral Maxillofac Surg*. 2012;70(2):314-9.
31. Suzuki D, Bassi AP, Lee HJ, Alcântara PR, de Sartori IM, Luvizuto ER, Faco EF, Faot F. Inferior alveolar nerve lateralization and implant placement in atrophic posterior mandible. *J Craniofac Surg*. 2012;23(4):e347-9.
32. Faot F, Hermann C, Sartori EM, Bassi AP. Tilted implants and prototyping: a security option for improving the anchorage in atrophic maxilla. *Gen Dent*. 2013;61(2):28-31.
33. Aparecida de Mattias Sartori I, Uhlenndorf Y, Padovan LE, Junior PD, Melo AC, Tiossi R. Attachment-retained gingival prosthesis for implant-supported fixed dental prosthesis in the maxilla: a clinical report. *J Prosthodont*. 2014;23(8):654-8.
34. Luiz J, Padovan LE, Claudino M. Recombinant human bone morphogenetic protein 2 in augmentation procedures: case reports. *Int J Oral Maxillofac Implants*. 2014;29(5):1198-203.
35. Jamcoski VH, Faot F, de Mattias Sartori IA, Vieira RA, Tiossi R. Occlusal concepts application in resolving implant prosthetic failure: case report. *J Oral Implantol*. 2014;40(2):203-10.
36. Padovan LE, Ribeiro-Júnior PD, de Mattias Sartori IA, Thomé G, Sartori EM, Uhlenndorf J. Multiple zygomatic implants as an alternative for rehabilitation of the extremely atrophic maxilla: a case letter with 55 months of follow-up. *J Oral Implantol*. 2015 Feb;41(1):97-100.
37. Faot F, Thomé G, Bielemann AM, Hermann C, Melo ACM, Padovan LEM, Sartori IAM. Simplifying the Treatment of Bone Atrophy in the Posterior Regions: Combination of Zygomatic and Wide-Short Implants—A Case Report with 2 Years of Follow-Up.



— CLINICAL CASE

Grand Morse

Neodent Grand Morse

GM HELIX implant with Immediate Loading in lower molar

Summary of Medical History

Female patient, aged 48, leucoderma, ASA 1, without systemic complications for dental implant surgery, missing teeth 36 and 37 for 5 years.

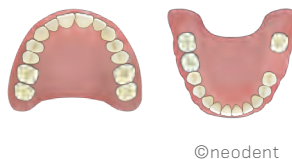
Planejamento

Single.

Position 36 of Mandible.

Immediate Loading.

Access Technique With flap.




Surgery

After opening the flap, the surgical drilling sequence was initiated using the drills from the Grand Morse surgical kit to place the implant. Instrumentation was done as far as drill 4.0, without the use of pilot drill 4.0 and drill 4.0+, since less bone density was found in the area than expected, in order to allow good primary stability of the implant, permitting Immediate Loading technique. Placement began with the surgical contra-angle and finished with the torque wrench (final torque: 40Ncm).

Conclusion

The GM HELIX implant proved highly favorable for performing the immediate loading technique, offering great versatility in the instrumentation technique, according to the available bone density, due to the various drill options in its Surgical Kit. Extremely easy capture is one of its great benefits, in addition to providing a range of prosthetic options similar to the Neodent Cone Morse implants. The click coping for temporary restoration is also a great improvement for the immediate loading technique since it facilitates intraoral capture of provisional crowns.



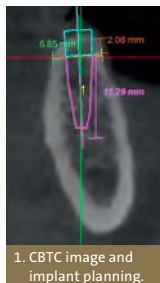
MARCELO FONTES TEIXEIRA

mfonttes@uol.com.br
BRASIL

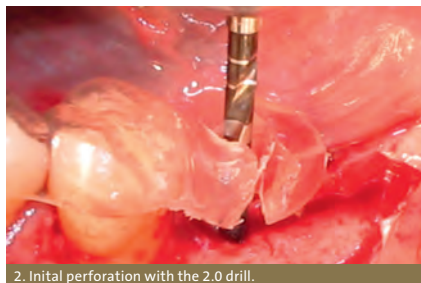
Masters degree in Implantology;
Specialist in Periodontology,
Orthodontology and TMD;
Coord. Spec. Implantology (UniFOA -
VR / RJ - Brazil);
Scientific Reviewer, JOMI/EJOI - Brazil;
Scientific Consultant for NEODENT.

www.neodent.com.br/grandmorse

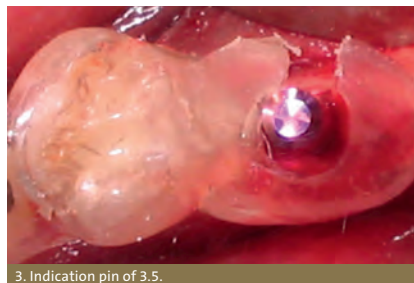GM HELIX implant with Immediate Loading in lower molar.



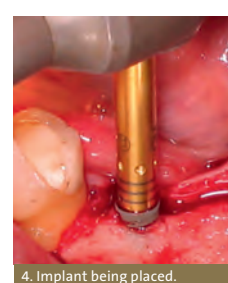
1. CBTC image and implant planning.



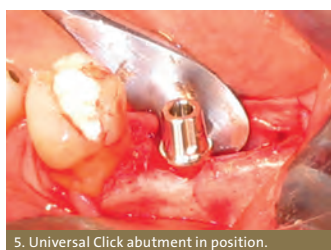2. Initial perforation with the 2.0 drill.



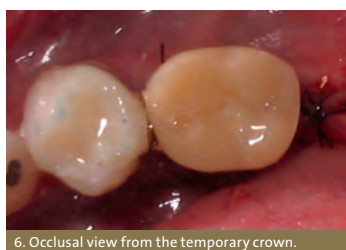3. Indication pin of 3.5.



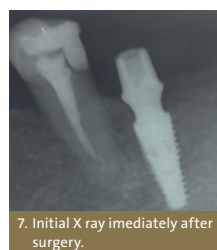4. Implant being placed.



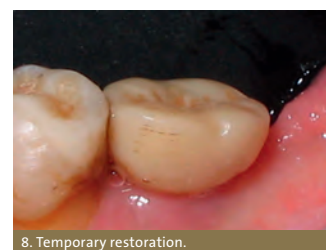5. Universal Click abutment in position.



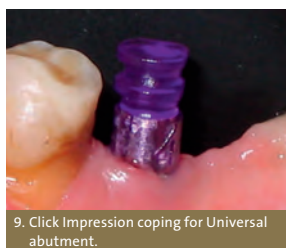6. Occlusal view from the temporary crown.



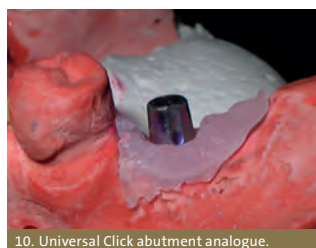7. Initial X ray immediately after surgery.



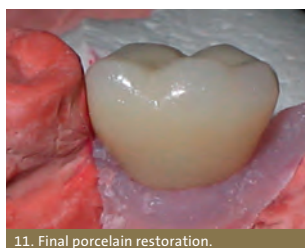8. Temporary restoration.



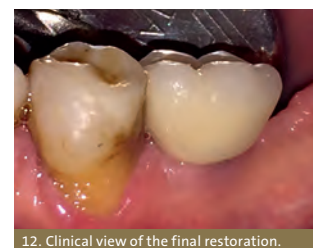9. Click Impression coping for Universal abutment.



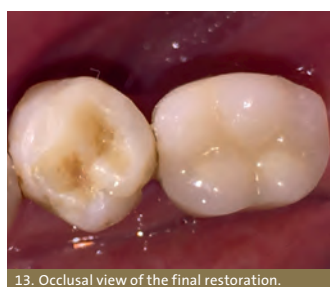10. Universal Click abutment analogue.



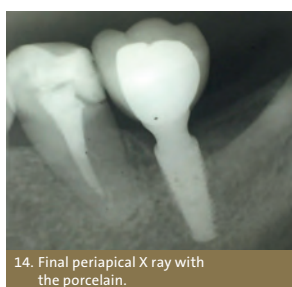11. Final porcelain restoration.



12. Clinical view of the final restoration.



13. Occlusal view of the final restoration.



14. Final periapical X ray with the porcelain.

— CLINICAL CASE

Grand Morse

GM HELIX immediate implant with immediate loading.

Patient's Medical History

Female patient, aged 52, leucoderma, ASA 1, without systemic complications for dental implant surgery, with tooth 15 presenting a longitudinal crack, with constant loosening of the crown and of the intraradicular pin, with indication for extraction and immediate implant.

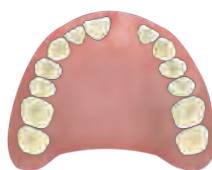Planning

Single Case.

Position 21 of the Maxilla (FDI System).

Immediate Loading Protocol.

No Flap Access Technique.



Description of the procedure

Grand Morse surgical kit for placement of a Helix GM 4.3x13 implant. Drilling sequence was followed until drill 3.5, without the use of drill 4.3 or pilot drill 4.3, to optimize primary stability of the implant by undersizing osteotomy, taking into consideration the low bone density found in the area during initial drilling, allowing use of the immediate loading technique. Placement began with the surgical contra-angle and finished with the torque wrench (final torque: 50N.cm).

Prosthetic Description

The GM click exact universal abutment 3.3x6x2.5 was placed (torque 20N.cm). The click provisional coping was positioned. A full provisional crown was milled in-house, filled with autopolymerizing acrylic resin and placed in the mouth over the provisional click coping 3.3x6. After capture, the provisional crown was removed, with the provisional coping inside it. After the final adjustments, the crown was fixed just with the click effect of the provisional coping, remaining under occlusion.

Result description and/or conclusion

The GM Helix implant is highly suitable for the immediate implant technique with immediate loading, especially when the sub-instrumentation technique is used, even with little bone density. Extremely easy capture of the implant is one of its great benefits. The connection between the GM exact click universal abutment and the click provisional coping makes the immediate loading technique simple, quick and predictable, reducing treatment time and optimizing the immediate aesthetic results.



MARCELO FONTES TEIXEIRA

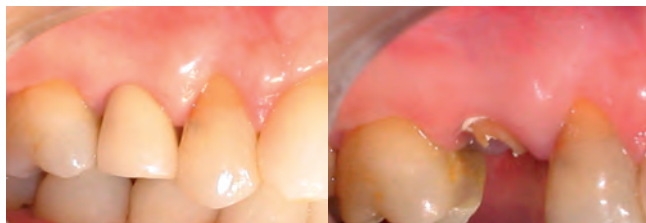mfontes@uol.com.br
BRASIL

Masters degree in Implantology;
Specialist in Periodontology,
Orthodontology and TMD;
Coord. Spec. Implantology (UniFOA -
VR / RJ - Brazil);
Scientific Reviewer, JOMI/EJOI - Brazil;
Scientific Consultant for NEODENT.

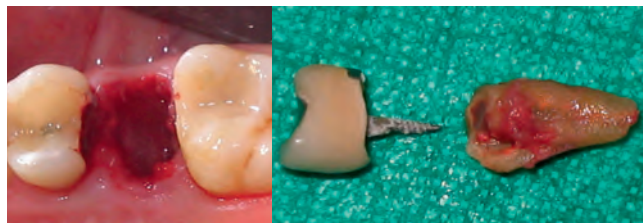
www.neodent.com.br/grandmorse

Neodent Grand Morse

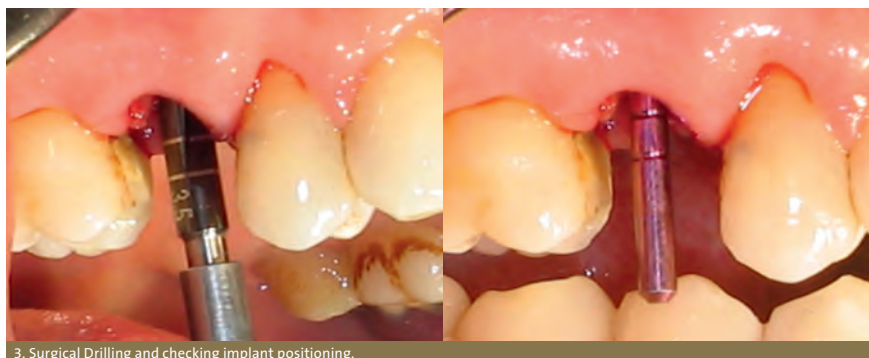GM HELIX immediate implant with immediate loading.



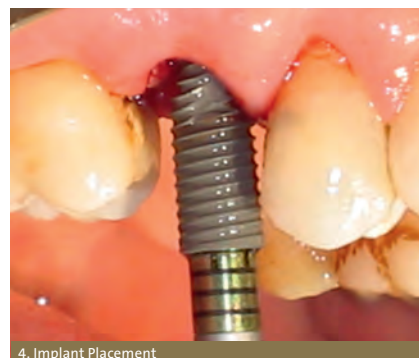1. Initial Case



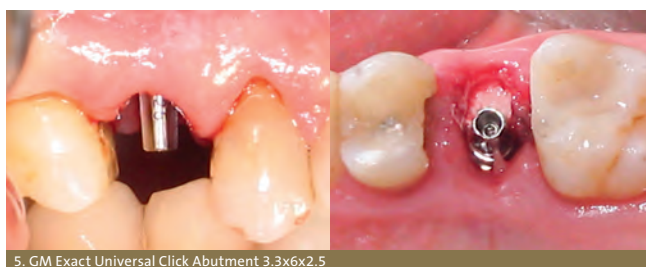2. Autramatic Extraction



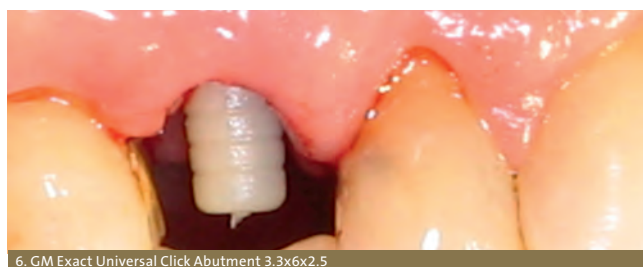3. Surgical Drilling and checking implant positioning.



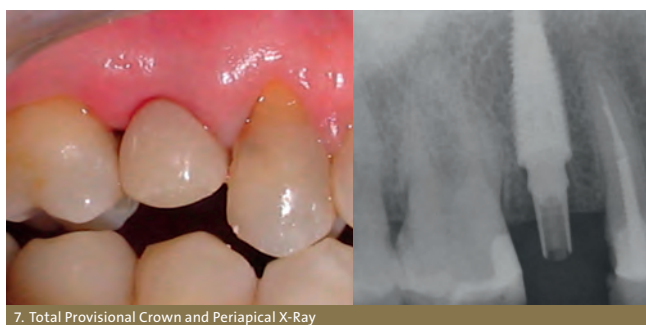4. Implant Placement



5. GM Exact Universal Click Abutment 3.3x6x2.5



6. GM Exact Universal Click Abutment 3.3x6x2.5



7. Total Provisional Crown and Periapical X-Ray

— CLINICAL CASE

Grand Morse

Maxillary sinus tangential technique for prosthetic resolution.

Patient's Medical History

Patient has atypical chronic leukemia. Takes no medication that would prevent or increase the risk of implant placement. Has been a patient of this team since 1991 and has already placed five implants in different areas in the last 15 years.

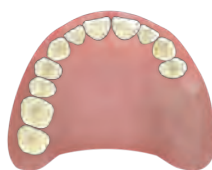
Planning

Partial Arch.

Positions 25, 26, 27 of the Maxilla (FDI System).

Immediate Loading Protocol.

With Flap Access Technique.



Description of the procedure

Incision in crest, from implant 25 to the distal area of 27, reflected flap, 12mm distal was measured to implant 25 and angled at 30 degrees (in relation to 25) in mesiodistal direction. Drilling with guide drill, to 15 mm (checked with direction indicator), followed by drills 3.5 and 3.75 from the GM Helix Acqua 3.75 x 13 mm, which was then placed. The torque greater than 60 N.cm allowed for immediate loading. Three days later the provisional was placed.

Prosthetic Description

A GM Angled Mini Abutment with a transmucosal height of 1.5mm and 30-degree angle, was screwed into the GM Helix implant placed tangentially to the maxillary sinus at the height of tooth 27. Another straight Mini Abutment, with a 1 mm band, was placed on the existing implant, rehabilitating 25. Both Mini Abutments received temporary resin-covered copings so as to build a provisional splint from 25 to 27 with 26 as the pontic.

Result description and/or conclusion

The work is still provisional, but illustrates a practical solution, with a reduction in cost, time and morbidity, in the treatment of posterior upper areas with bone height limitation. Obviously, there needs to be bone thickness in the part distal to the maxillary sinus and an implant or bone area compatible with placement in the anterior region, so as to allow splinting with the distal implant.



DR. FLÁVIO DOMINGUES DAS NEVES

flaviodominguesneves@gmail.com
BRASIL

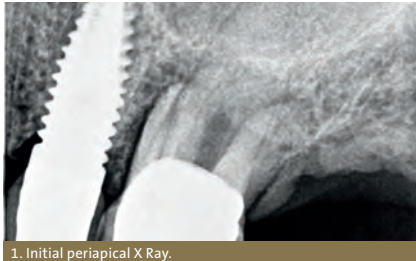Professor at the School of Dentistry of
the Federal University of Uberlândia
- UFU;
Prosthetic Specialist - UFU and
Implantology USP - Bauru;
Master's and PhD in Oral
Rehabilitation USP - Ribeirão Preto;
Scientific and Technical Internship in
CAD/CAM - Chapel Hill - NC-USA.

Other doctors that participated in the
procedure:

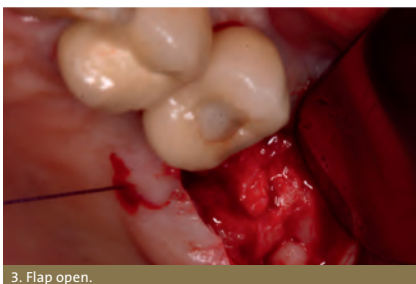
Flávio Domingues das Neves;
Célio Jesus do Prado;
Tiago Augusto Quirino Barbosa;
Tais Alves dos Reis.

www.neodent.com.br/grandmorse

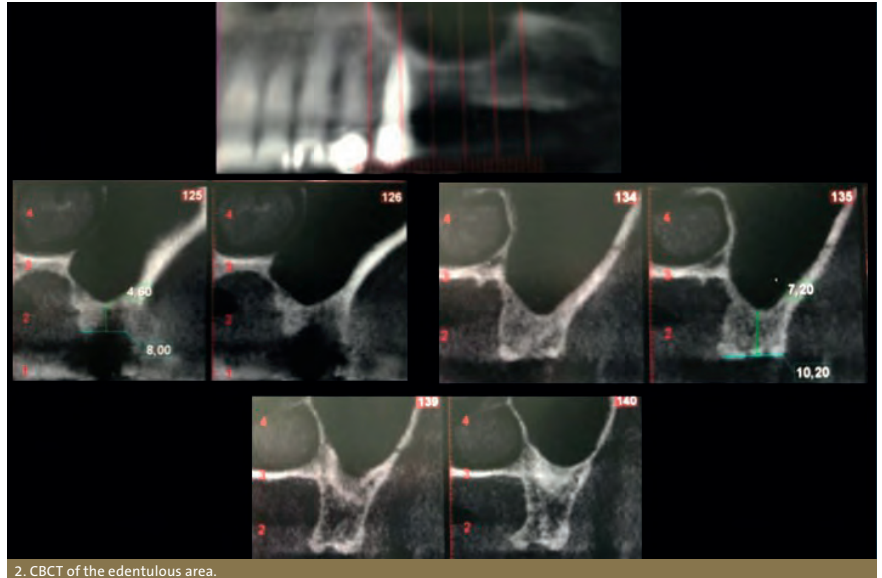
Maxillary sinus tangential technique for prosthetic resolution.



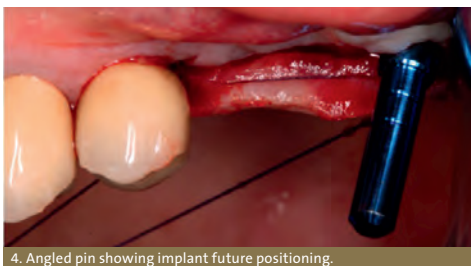
1. Initial periapical X Ray.



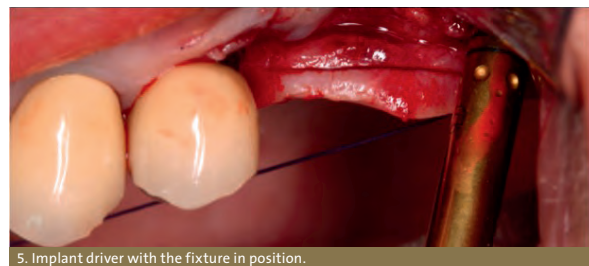
3. Flap open.



2. CBCT of the edentulous area.



4. Angled pin showing implant future positioning.



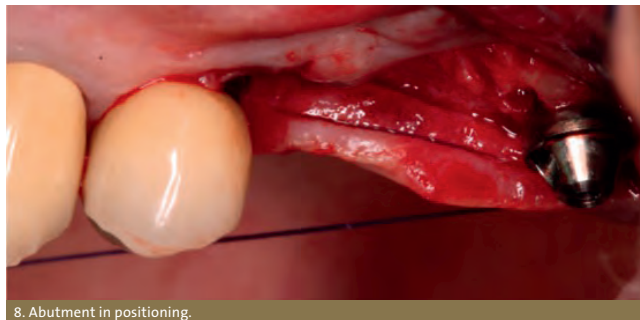
5. Implant driver with the fixture in position.



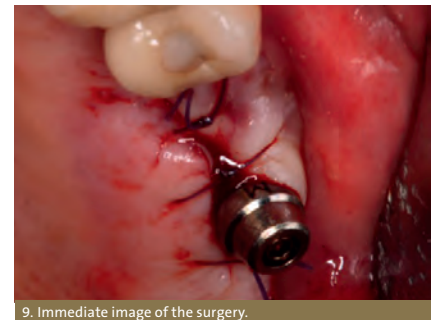
6. Acqua Helix GM implant.



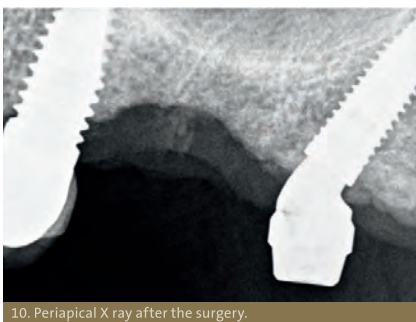7. Angled abutment to be placed.



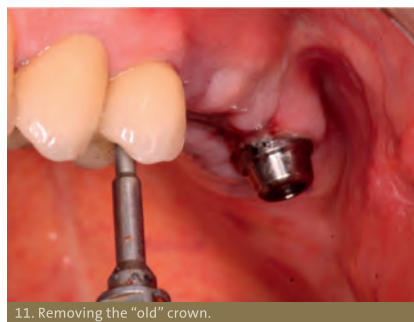
8. Abutment in positioning.



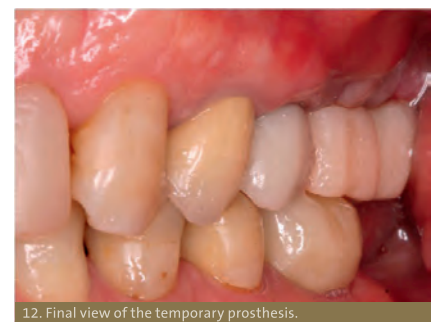9. Immediate image of the surgery.



10. Periapical X ray after the surgery.



11. Removing the "old" crown.



12. Final view of the temporary prosthesis.

— CLINICAL CASE

Grand Morse

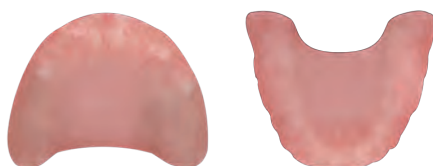
Total Inferior Rehabilitation with Grand Morse Implants.

Patient's Medical History

Patient has had full upper and lower prosthesis for over 50 years, came to the clinic due to lack of stability of full lower prosthesis and she was feeling twinges in the posterior region of the mandible on both sides when chewing and had great difficulty chewing.

Planning

Full Arch.
Immediate Loading Protocol.
With Flap Access Technique.



©neodent

Description of the procedure

Infiltrative anesthesia administered in the region of the mental foramen and lingual infiltration supplement on both sides L and R, marking in the proximity of the mental foramen on both sides with a copying pencil to limit the extension of the incision.

Total flap and detachment to locate the mental foramen on both sides L and R. Conventional bone drilling sequence, without sub-instrumentation. First, placement of inclined implants in the region of 34 and 44 and then implant placement in the region of 32 and 42.

All implants surgically placed with 45 N.cm

32 and 42 - GM Helix Acqua implants of 11.5 mm

34 and 44 - GM Helix Acqua implants of 13 mm

Prosthetic Description

Placement of GM Mini Conical Abutments of 3.5 mm and fitting with multifunctional guide joined to the impression components with pattern acrylic resin and added silicone.

Result description and/or conclusion

After 6 months of clinical and radiographic monitoring, the patient is satisfied and has recovered her masticatory function.



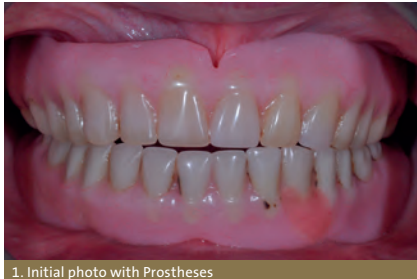PROF. DR. EDILSON FERREIRA

dredilsonferreira50@gmail.com
BRASIL

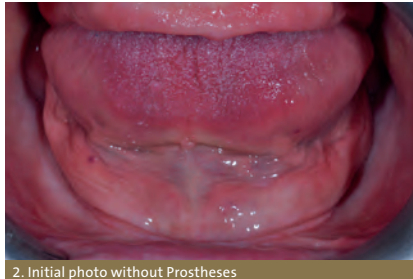Specialist in Implantology; Master's
in Oral Rehabilitation; PhD in
Implantology; Post-doctorate in
Implantology.

www.neodent.com.br/grandmorse

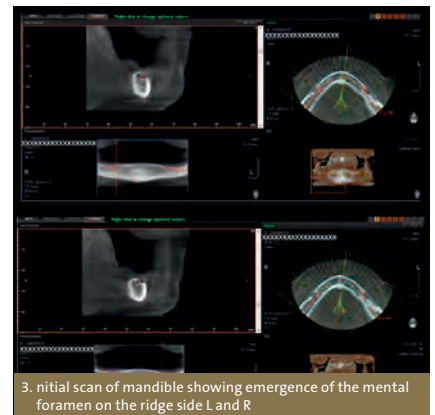
Total Inferior Rehabilitation with Grand Morse Implants.



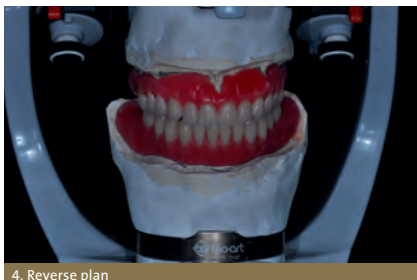
1. Initial photo with Prosthesis



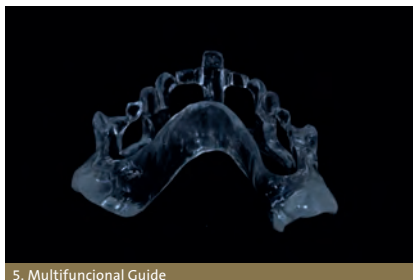2. Initial photo without Prosthesis



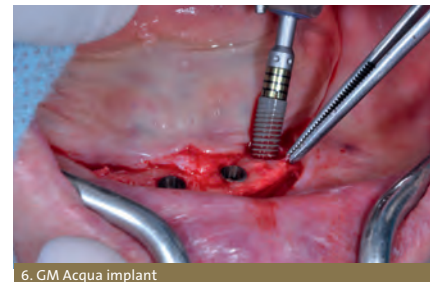
3. Initial scan of mandible showing emergence of the mental foramen on the ridge side L and R



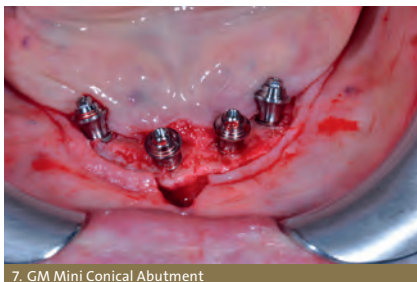4. Reverse plan



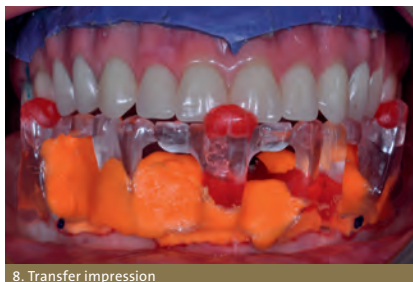5. Multifunctional Guide



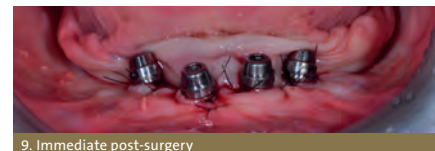6. GM Acqua implant



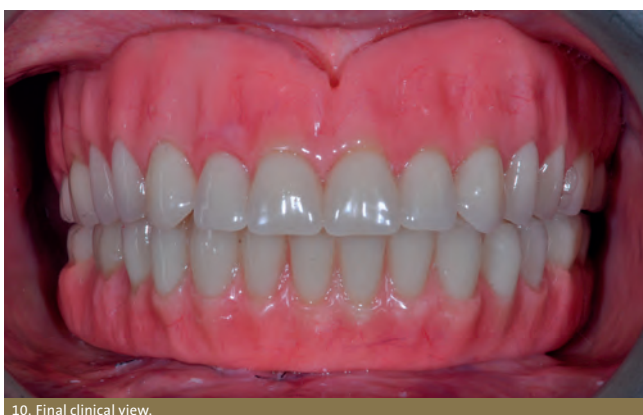7. GM Mini Conical Abutment



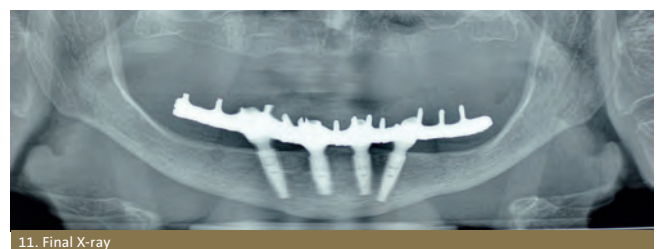
8. Transfer impression



9. Immediate post-surgery



10. Final clinical view.



11. Final X-ray

— CLINICAL CASE

Grand Morse

Neodent Grand Morse

Inferior denture with narrow implants (3.5mm).

Patient's Medical History

Patient without systemic compromise, ASA1, not on any ongoing medication, presence only of teeth 42 and 43.

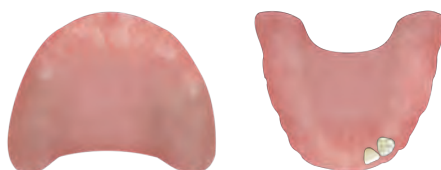
Complained of difficulty chewing, pain in the remaining teeth as well as dissatisfaction with aesthetics.

Planning

Full Arch.

Immediate Loading Protocol.

With Flap Access Technique.



Description of the procedure

For ideal placement of the implants and prosthesis, a multifunctional guide was fabricated according to reverse planning. The surgery was performed under local anesthetic in the inferior alveolar nerves and bilateral mental nerve. Teeth 32 and 33 were then extracted, followed by supracrestal and oblique incision, flap detachment, smoothing of the ridge and drilling (drill GM 2 and 3.5). Five GM Acqua Helix 3.5x13 mm implants were placed in the intermentonian region and all obtained a torque greater than 60N.cm.

Prosthetic Description

The mini abutments were selected (5.5mm) and placed (torque of 32N.cm), then followed by continuous suture. The copings were fitted over the mini abutments and joined together and to the multifunctional guide, the occlusal record was made, followed by the transfer impression. The copings were unscrewed and the impression was removed and sent to the laboratory to fabricate the metal bar and assemble the inferior denture using the passive-fit cementation technique. The prostheses were then placed and an occlusal adjustment made.

Result description and/or conclusion

It was possible to conclude that in cases where patients require full lower arch rehabilitation and have little bone thickness in the intermentonian region, the use of 5 narrow implants is an excellent alternative. This case obtained a highly satisfactory result for hard and soft tissue with 1 year's monitoring, without complications for either the implant or the prosthesis.



DR. GENINHO THOMÉ

ltrojan@neodent.com.br
BRASIL

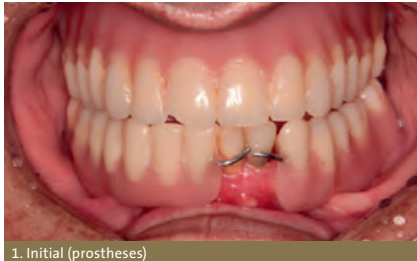Master's and PhD in Implantology;
Scientific Chairman for Neodent;
Chairman of Neodent's Board of Directors.

Other doctors that participated in the procedure:

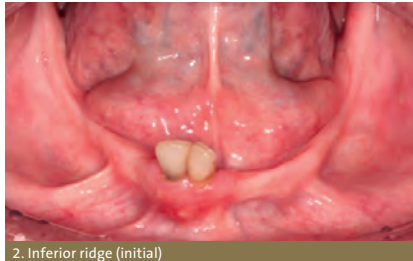Sérgio Bernardes;
Mary Stella Dias Vitório;
Carolina Accorsi Cartelli;
Larissa Trojan.

www.neodent.com.br/grandmorse

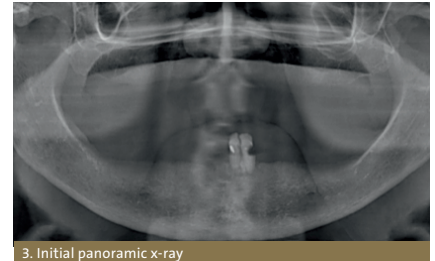Inferior denture with narrow implants (3.5mm).



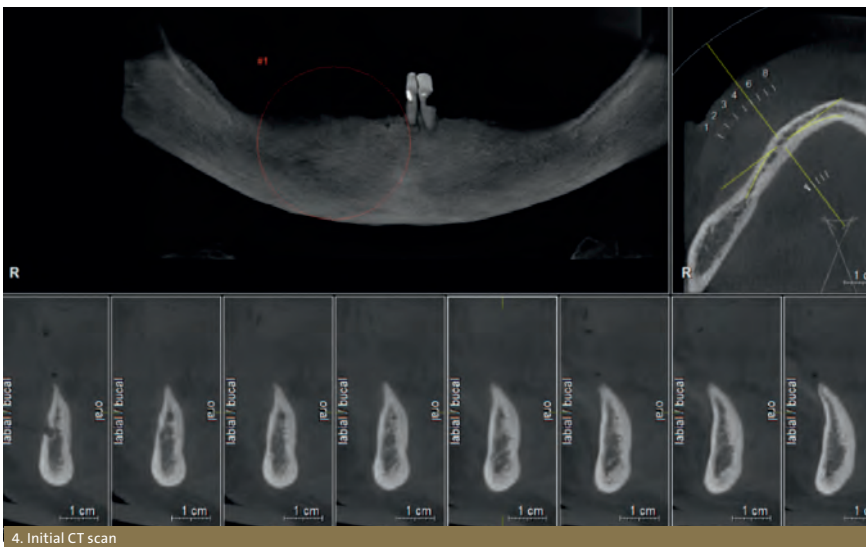
1. Initial (prostheses)



2. Inferior ridge (initial)



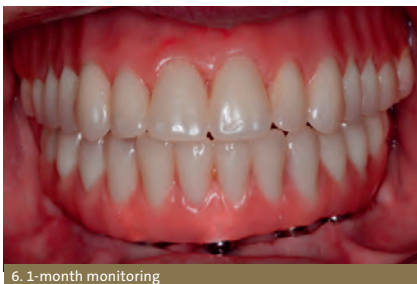3. Initial panoramic x-ray



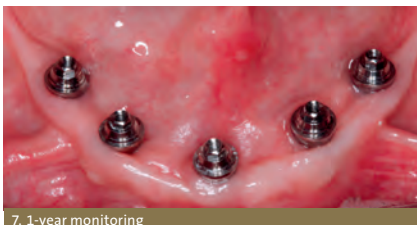4. Initial CT scan



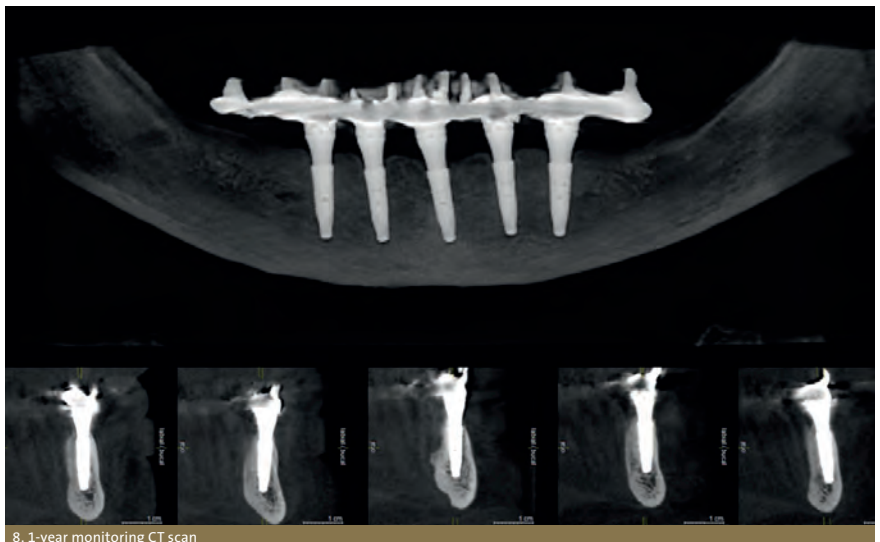5. Implant Helix 3.5mm



6. 1-month monitoring



7. 1-year monitoring



8. 1-year monitoring CT scan

— CLINICAL CASE

Grand Morse

Single implant in the posterior mandible under immediate loading.

Patient's Medical History

Patient ASA 1, not on any ongoing medication, non-smoker.

Main complaint: absence of tooth 36.

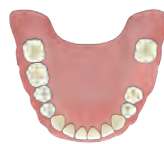Planning

Single Case.

Position 36 of the Mandible (FDI System).

Immediate Loading Protocol.

No Flap Access Technique.



©neodent

Description of the procedure

The surgery was performed under local infiltration anesthesia in the region, without nerve block. Drilling was then completed with the 2mm, 3.5mm and 4.3mm drills, without opening up a flap (flapless). The GM Acqua Helix 4.3x11.5 mm implant was then placed approximately 2mm subcrestal and a progressive torque of 60Ncm was obtained.

The 4.5x4x3.5 abutment was selected and placed with 32Ncm. The provisional crown was then fabricated, using the acrylic coping, and provisionally cemented.

Prosthetic Description

The provisional crown was fabricated conventionally over the abutment to apply immediate loading. Once the peri-implant tissue had regenerated, the transfer impression was taken in order to fabricate the metal coping. Since the coping had been tested and a periapical x-ray was taken to confirm adaptation, a transfer impression was made to apply the ceramic. The metal ceramic prosthesis was then screwed in and the screw channel sealed with Teflon and resin-based composite.

Result description and/or conclusion

In the 1st year of monitoring, excellent behavior of the bone tissue and soft tissue was observed, with no complications in the implant or prosthesis.



DR. GENINHO THOMÉ

ltrojan@neodent.com.br

BRASIL

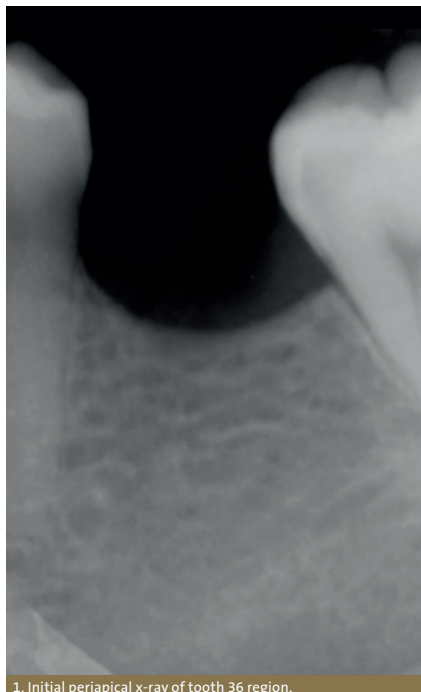
Master's and PhD in Implantology;
Scientific Chairman for Neodent;
Chairman of Neodent's Board of
Directors.

Other doctors that participated in the
procedure:

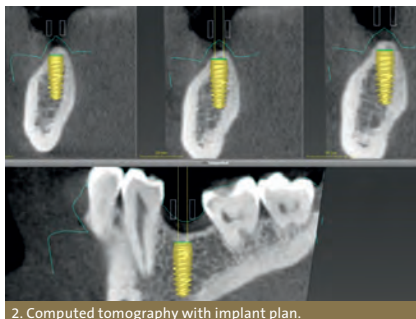
Sérgio Rocha Bernardes;
Mary Stella Dias Vitório;
Carolina Accorsi Cartelli;
Larissa Trojan.

www.neodent.com.br/grandmorse

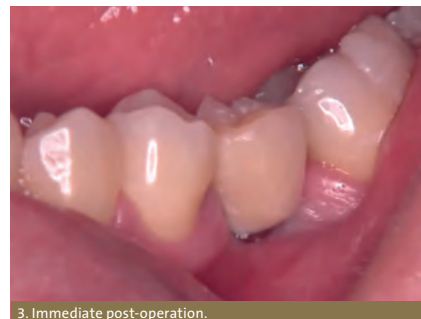
Single implant in the posterior mandible under immediate loading.



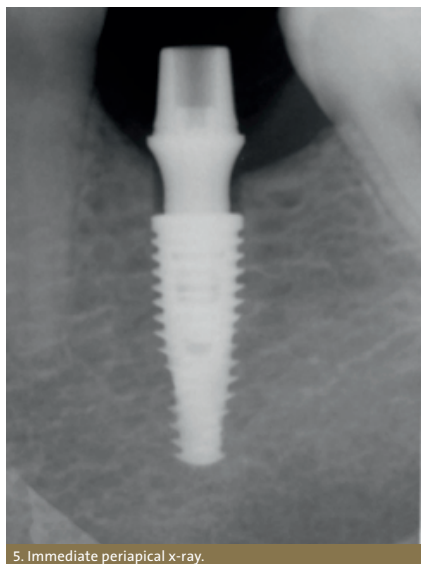
1. Initial periapical x-ray of tooth 36 region.



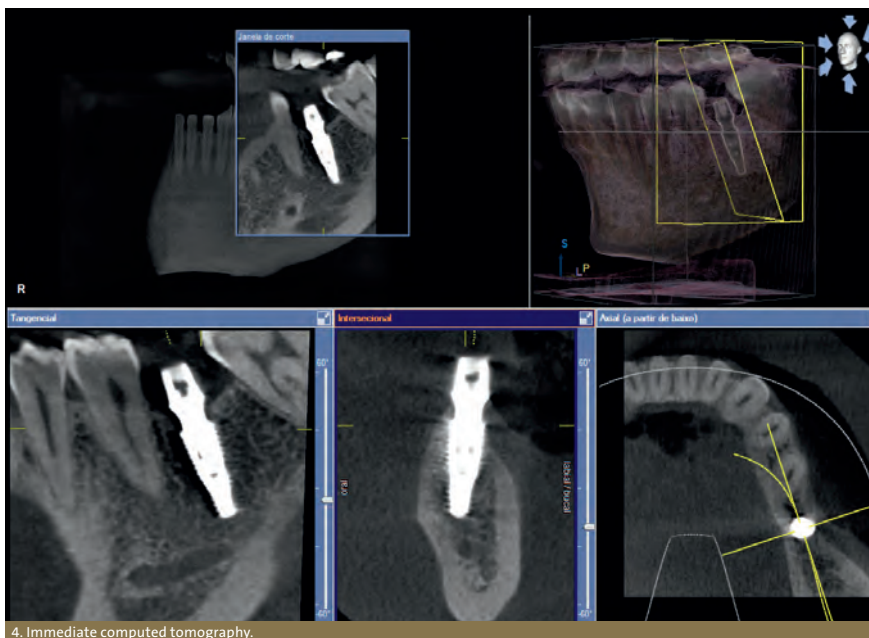
2. Computed tomography with implant plan.



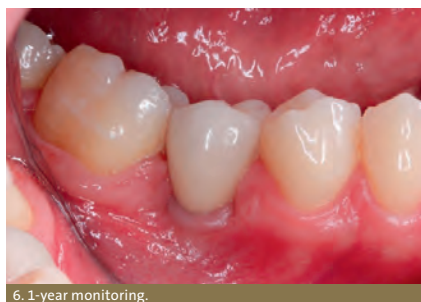3. Immediate post-operation.



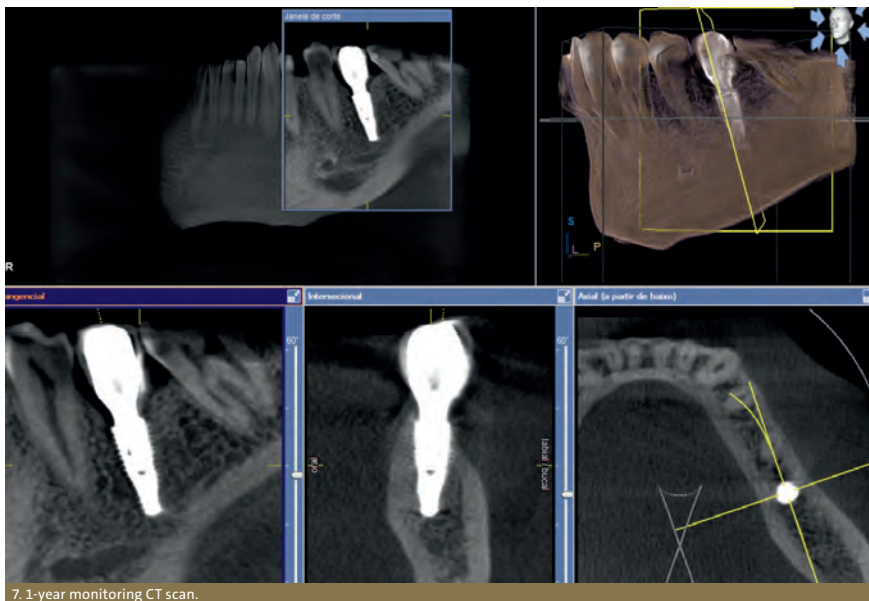
5. Immediate periapical x-ray.



4. Immediate computed tomography.



6. 1-year monitoring.



7. 1-year monitoring CT scan.

— CLINICAL CASE

Grand Morse

Neodent Grand Morse

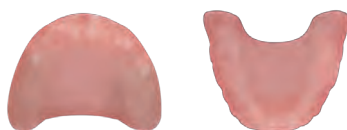
Double hybrid bridges under immediate loading.

Patient's Medical History

Patient without systemic compromise, ASA 1, not on any ongoing medication, total loss of upper and lower teeth. Main complaint: Full upper and lower prosthesis loose, difficulty in masticatory function and aesthetic dissatisfaction.

Planning

Full Arch.
Immediate Loading Protocol.
With Flap Access Technique.



©neodent

Description of the procedure

After local anesthesia, a supracrestal and oblique incision was made in both arches and the flap detached. Osteotomy due to the position of the teeth on the multifunctional guide. The surgery began in the maxilla, where 5 GM Helix Acqua implants were placed. 5 GM Helix Acqua implants were also placed in the mandible. All the implants obtained torque greater than 60N.cm. Mini abutments were selected and placed (torque of 32N.cm) for upper and lower transfer impression.

Prosthetic Description

The mini abutments were selected, placed and joined together and onto the multifunctional guide. The occlusal record was made, which was followed by the transfer impression made with condensation silicone. The copings were unscrewed and the impression was removed and sent to the laboratory to fabricate the metal bars and assemble the hybrids using the passive-fit cementation technique.

The lower and upper hybrid prostheses were placed and adjusted according to the principles of balanced bilateral occlusion.

Result description and/or conclusion

In the 1st year of monitoring, excellent behavior of the bone tissue and soft tissue was observed, and behavior of the implants and prostheses. Considering the evolution of the case, a patient with full upper and lower prostheses, who 2 days after implant placement receives definitive implant-supported prostheses, the result obtained was highly satisfactory.



DR. GENINHO THOMÉ

ltrojan@neodent.com.br

BRASIL

Master's and PhD in Implantology;
Scientific Chairman for Neodent;
Chairman of Neodent's Board of Directors.

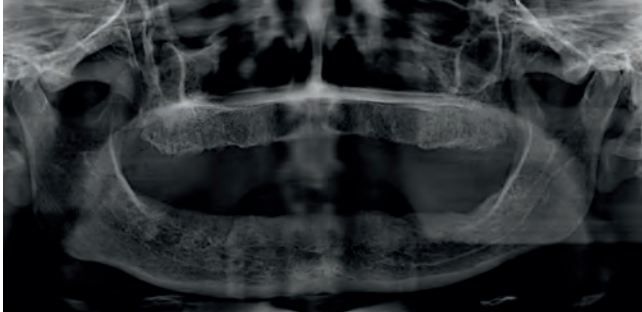
Other doctors that participated in the procedure:

Sérgio Bernardes;
Mary Stella Dias Vitório;
Carolina Accorsi Cartelli;
Larissa Trojan.

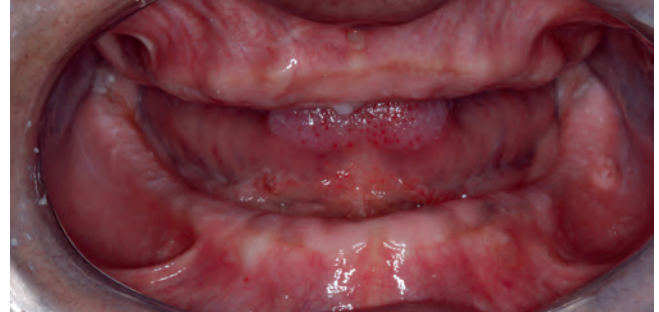www.neodent.com.br/grandmorse

Neodent Grand Morse

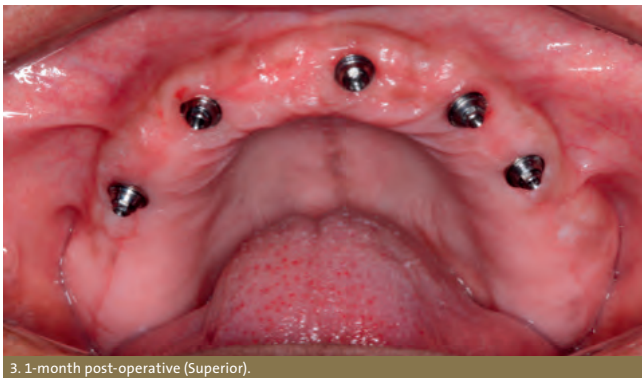Double hybrid bridges under immediate loading.



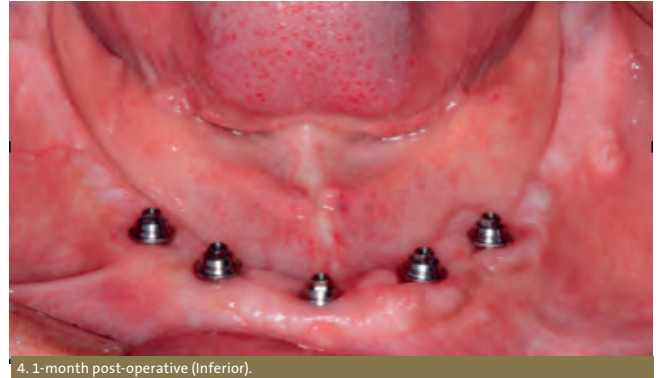1. Initial panoramic x-ray.



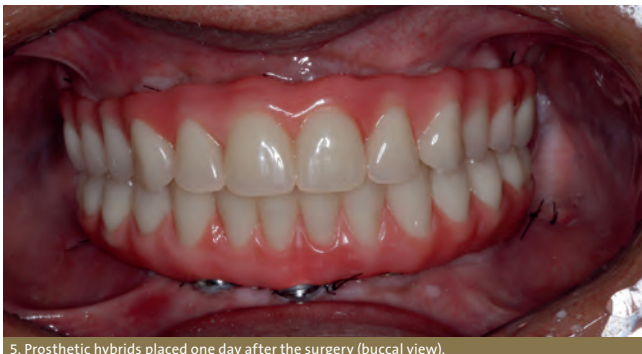2. Initial condition (intraoral).



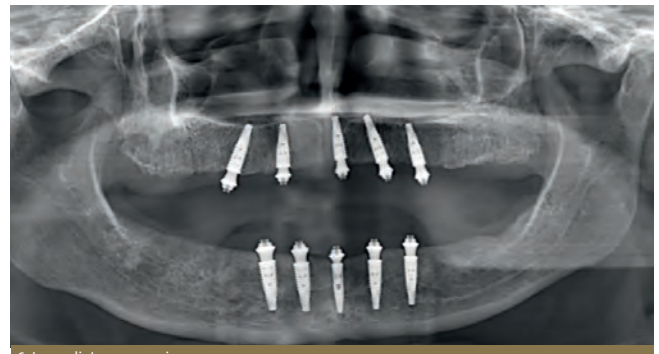3. 1-month post-operative (Superior).



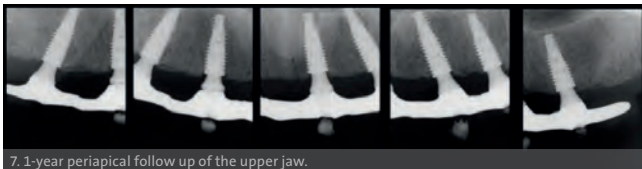
4. 1-month post-operative (Inferior).



5. Prosthetic hybrids placed one day after the surgery (buccal view).



6. Immediate panoramic x-ray.



7. 1-year periapical follow up of the upper jaw.



8. 1-year periapical follow up of the lower jaw.

— CLINICAL CASE

Grand Morse

Immediate implant with aesthetic area immediate loading.

Patient's Medical History

Patient ASA1, not on any ongoing medication, non-smoker.

Main complaint: mobility in tooth 12.

Clinical exam and x-ray revealed presence of radicular fracture and periapical lesion.

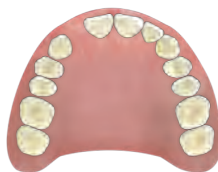
Planning

Single Case.

Position 12 of the Maxilla (FDI System).

Immediate Loading Protocol.

No Flap Access Technique.



Description of the procedure

The surgery was performed under local anesthesia, starting with syndesmotomy of tooth 12 and minimally traumatic extraction using a dental extractor. Drilling was then completed with 2 and 3.5mm drills, without opening up a flap (flapless). The GM Acqua Helix 3.5x16 mm was placed 2mm subcrestal and a progressive torque of 45N.cm was obtained. The gap in the buccal region was filled with an alloplastic graft. The Ti base and the zirconia base were then placed and the immediate provisional crown fabricated.

Prosthetic Description

The Ti base 3.5x4x2.5 component was placed and the zirconia base cemented over it. The immediate provisional crowns were fabricated and cemented with temporary cement.

After 10 months of monitoring, the final prosthesis was planned. For the transfer impressions, a retraction cord was inserted around the component followed by the closed-tray impression with addition silicone.

A Lithium disilicate crown was then fabricated, and after being tested and adjusted (proximal and occlusal contacts) it was cemented with resinous cement.

Result description and/or conclusion

The result obtained in 1 year of monitoring were excellent behavior of the bone tissue and soft tissue, taking into account the area in question (aesthetic area), the patient's big smile and a cleverly resolved case.



DR. GENINHO THOMÉ

ltrojan@neodent.com.br

BRASIL

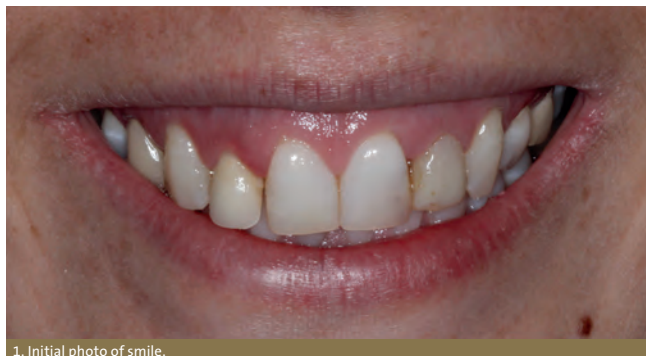Master's and PhD in Implantology;
Scientific Chairman for Neodent;
Chairman of Neodent's Board of
Directors.

Other doctors that participated in the
procedure:

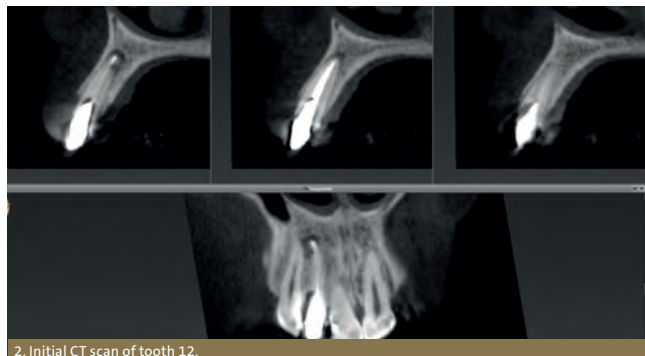Sérgio Bernardes;
Mary Stella Dias Vitório;
Carolina Accorsi Cartelli;
Larissa Trojan.

www.neodent.com.br/grandmorse

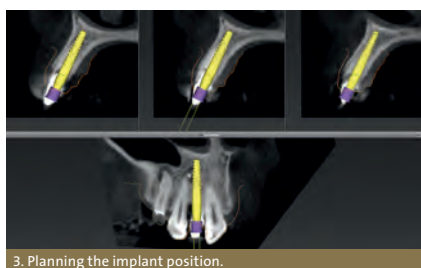
Immediate implant with aesthetic area immediate loading.



1. Initial photo of smile.



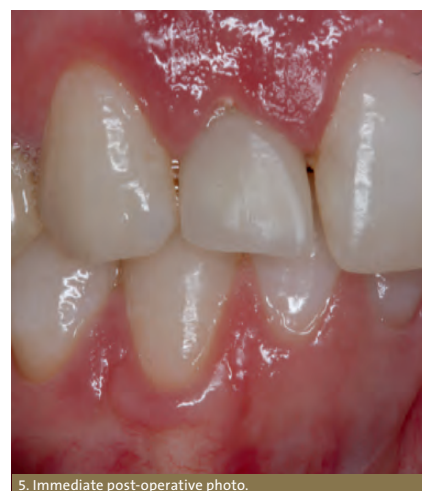2. Initial CT scan of tooth 12.



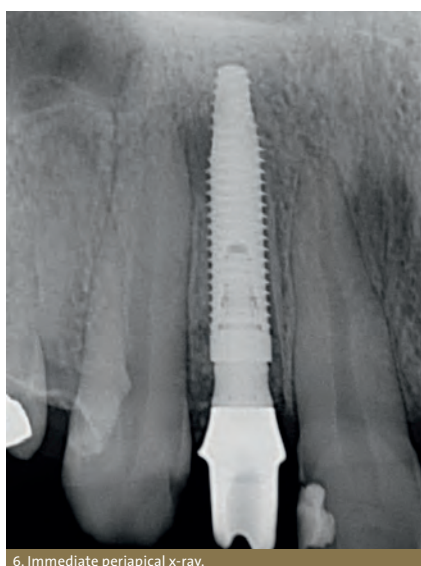3. Planning the implant position.



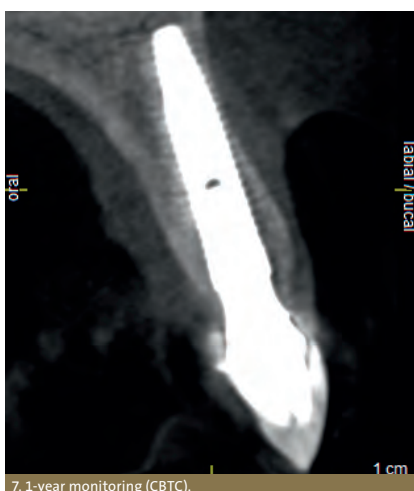4. Helix Grand Morse Implant.



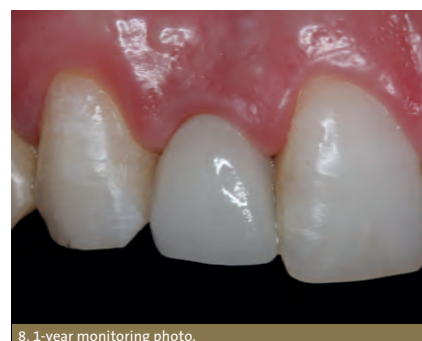5. Immediate post-operative photo.



6. Immediate periapical x-ray.



7. 1-year monitoring (CBTC).



8. 1-year monitoring photo.

— CLINICAL CASE

Grand Morse

Rehabilitation with Lower Denture Immediate Loading.

Patient's Medical History

Patient without systemic compromise, ASA1, not on any ongoing medication, total loss of teeth. Main complaint: Whole lower prosthesis loose.

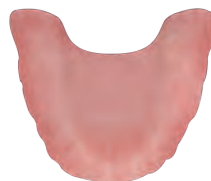Clinical and x-ray evaluation. First clinical consultation on 02/22/2016.

Planning

Full Lower Arch.

Immediate Loading Protocol.

With Flap Access Technique.



©neodent

Description of the procedure

For ideal placement of the implants and prosthesis, the multifunctional guide was fabricated according to a "reverse planning". The surgery was performed under local anesthetic in the inferior alveolar nerves and bilateral mental nerve. Supracrestal and oblique incision, flap detachment and smoothing of the ridge, followed by drilling. The GM Acqua Helix 4.3x13 mm implants were placed and all obtained a torque greater than 60Ncm. The GM mini conical abutments were then placed and continuous suture performed.

Prosthetic Description

The mini abutments were selected, placed and joined together and onto the multifunctional guide. The occlusal record was made, which was followed by the transfer impression made with condensation silicone. The transfers were unscrewed and the impression was removed and sent to the laboratory to fabricate the metal bar and assemble the denture using the passive-fit cementation technique.

The lower denture prostheses and full upper prosthesis were placed and adjusted according to the principles of balanced bilateral occlusion.

Result description and/or conclusion

In one year of monitoring, excellent behavior of the bone tissue and soft tissue was observed. The result obtained was highly satisfactory, with considerable improvement in the patient's masticatory function and quality of life.



DR. GENINHO THOMÉ

ltrojan@neodent.com.br

BRASIL

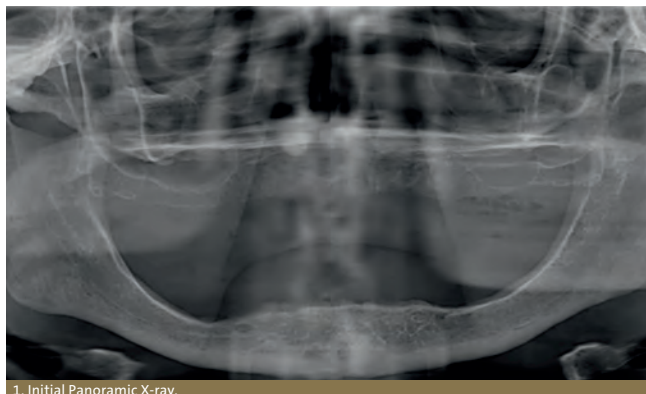Master's and PhD in Implantology;
Scientific Chairman for Neodent;
Chairman of Neodent's Board of Directors.

Other doctors that participated in the procedure:

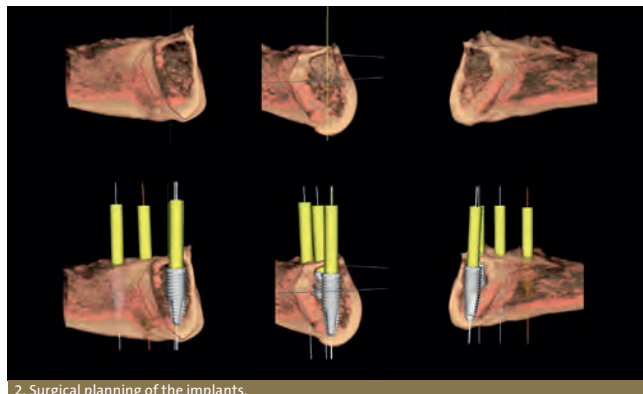
Sérgio Bernardes;
Mary Stella Dias Vitório;
Carolina Accorsi Cartelli;
Larissa Trojan.

www.neodent.com.br/grandmorse

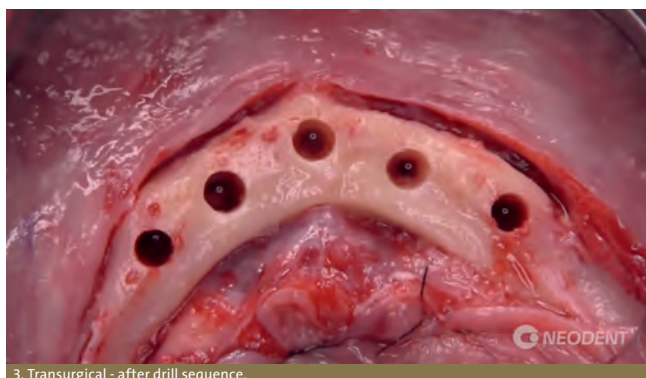Rehabilitation with Lower Denture Immediate Loading.



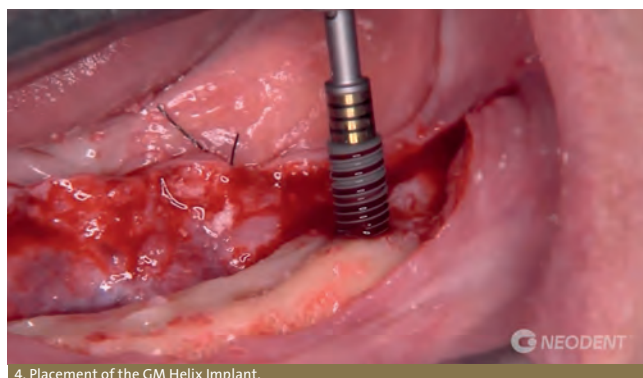
1. Initial Panoramic X-ray.



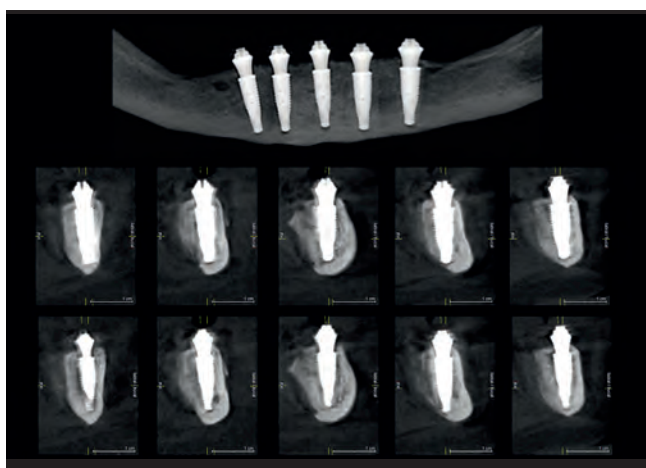
2. Surgical planning of the implants.



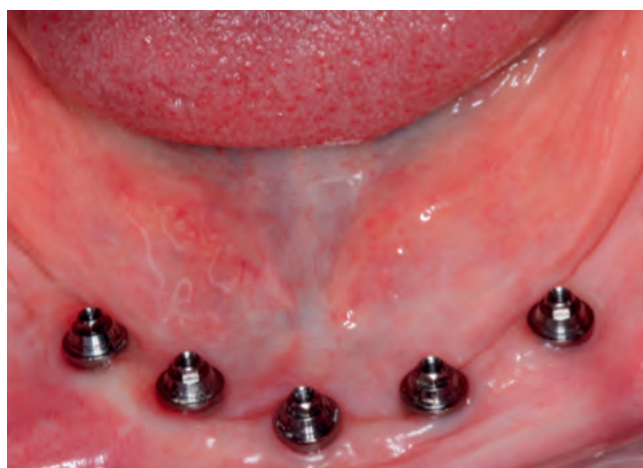3. Transsurgical - after drill sequence.



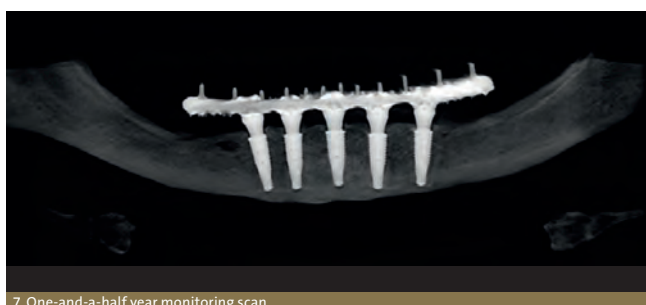4. Placement of the GM Helix Implant.



5. Tomography right after the surgery.



6. View of the mini abutments after 1 year of monitoring.



7. One-and-a-half year monitoring scan.

— CLINICAL CASE

Grand Morse

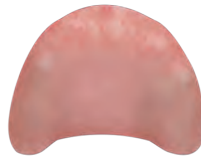Full arch immediate fixed reconstruction.

Patient's Medical History

Patient is female, aged 58, and has a history with migraines and antidepressants.

Planning

Full arch.
Immediate Loading Protocol.
With Flap Access Technique.



©neodent

Description of the procedure

1. Full upper arch clearance
2. Placement of tilted implants to avoid sinus augmentation.
3. Placement of multiunit mini conical abutments
4. Placement of impression copings (open tray)
5. Floss and pattern resin to secure a rigid matrix
6. Multifunctional appliance impression.
7. Placement of sutures.
8. Placement of healing caps.

Prosthetic Description:

Acrylic on a metal strengthener - Temporary prosthesis

Acrylic on PEEK - Final Prosthesis.

Result description and/or conclusion

In conclusion, the patient was extremely conscious of her upper teeth and smile; she wanted a "Hollywood" appearance smile.

The patient therefore chose a bleached tooth option for her final restoration and she wanted her new smile to be dramatically different from her original teeth. This patient was highly motivated and was delighted with the end result, which has given her a lot more self confidence.



PROF. JOE BHAT BDS FDS RCS

MClinDent MRD RCSEd

drjoebhat@gmail.com

UNITED KINGDOM

Hon. Visiting Professor,
Specialist Prosthodontist and Oral
Surgeon, Director at Moor Park
Specialist Dental Centre, ITI Fellow.

Other doctors that participated in the
procedure:

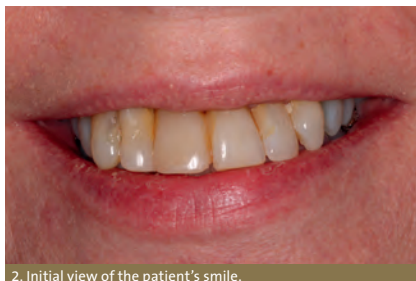DR CHANDNI PATTNI

www.neodent.com.br/grandmorse

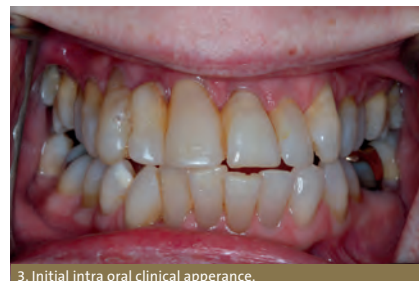Full arch immediate fixed reconstruction.



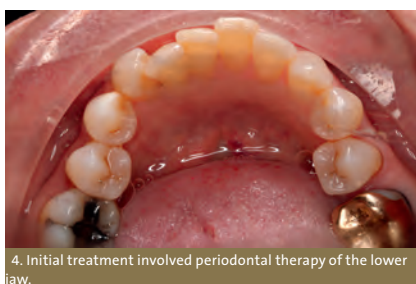1. Initial view of the patient.



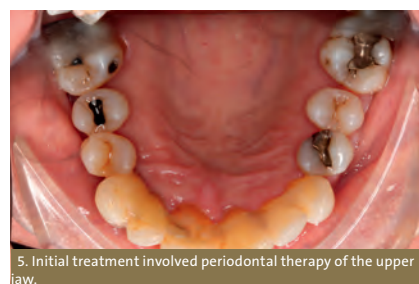2. Initial view of the patient's smile.



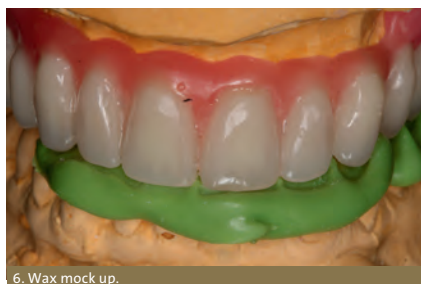3. Initial intra oral clinical appearance.



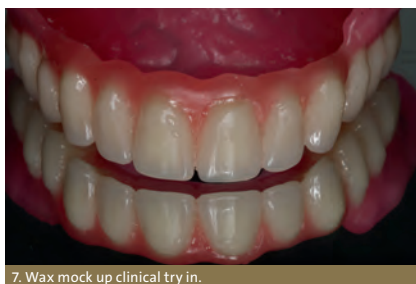4. Initial treatment involved periodontal therapy of the lower jaw.



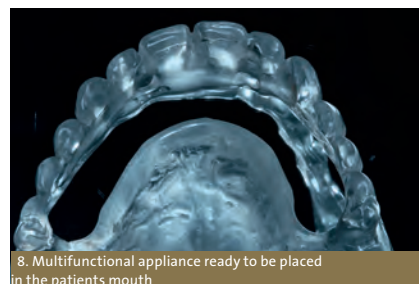5. Initial treatment involved periodontal therapy of the upper jaw.



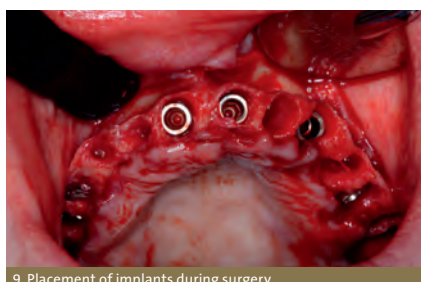
6. Wax mock up.



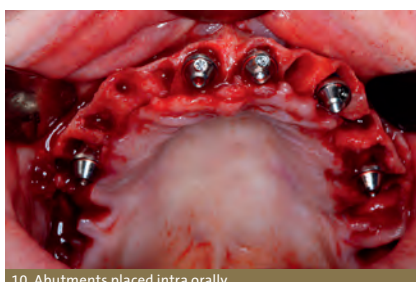7. Wax mock up clinical try in.



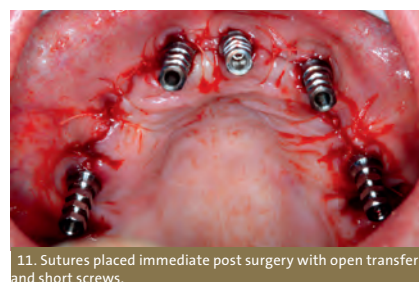8. Multifunctional appliance ready to be placed in the patients mouth



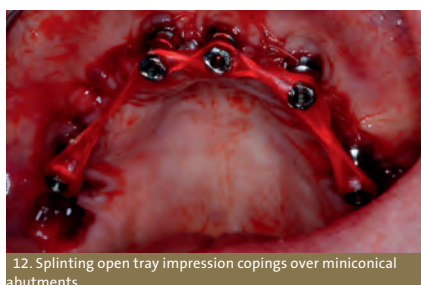9. Placement of implants during surgery.



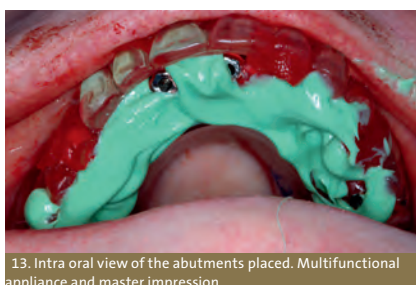
10. Abutments placed intra orally.



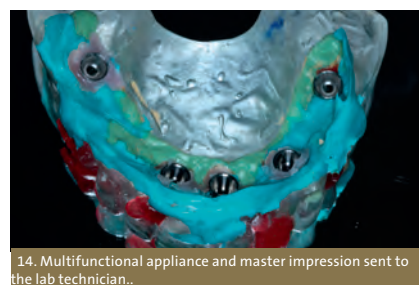
11. Sutures placed immediate post surgery with open transfers and short screws.



12. Splinting open tray impression copings over miniconical abutments.

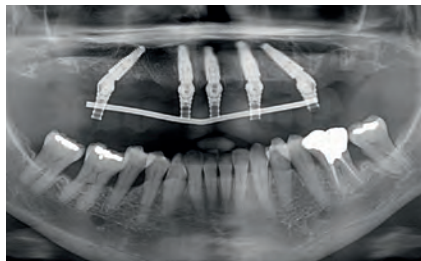


13. Intra oral view of the abutments placed. Multifunctional appliance and master impression.

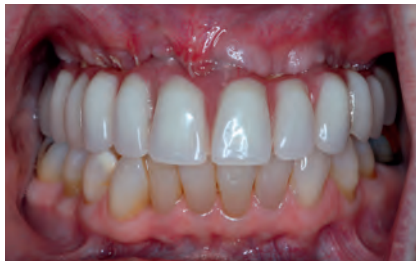

14. Multifunctional appliance and master impression sent to the lab technician..

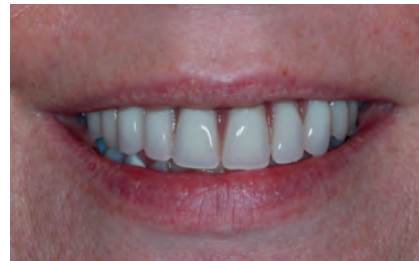Full arch immediate fixed reconstruction.



15. 1 week post surgery.



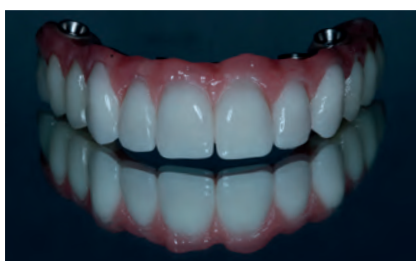16. 1 week post surgery.



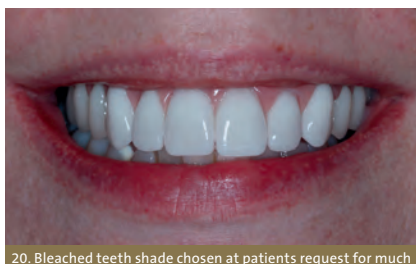17. 1 week post surgery.



18. 1 week post surgery.



19. Final hybrid bridge.



20. Bleached teeth shade chosen at patients request for much lighter teeth.



21. Bleached teeth shade chosen at patients request for much lighter teeth.

— CLINICAL CASE

Grand Morse

Neodent Grand Morse

Rehabilitation with Grand Morse implants and digital flow.

Patient's Medical History

Patient ASA1, not on any continuous medication, smoker. Complaints of mobility in fixed prosthesis in teeth 11- 21-22, which had already been re-stuck inadequately several times.

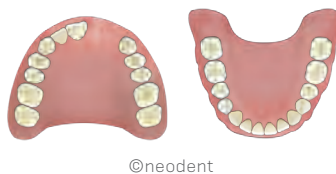
Planning

Parcial Arch.

Positions 21 and 22 of the Maxilla and 38 of the Mandible (FDI System).

Immediate Loading Protocol.

No Flap Access Technique..



©neodent

Description of the procedure

For ideal placement of the implant and prosthesis, the surgical guide was made according to the Neodent Guided Surgery protocol. This way, flapless surgery was performed under local anesthetic, starting with extraction of tooth 22 using tooth extractor, drilling in areas 21 and 22 and then placement of GM Helix Acqua 3.5x16mm infra-bone implants. Both obtained torques of more than 60 Ncm. The component selected was universal abutment 3.3x6x3.5 mm and the immediate provisional crowns were temporarily cemented.

Prosthetic Description

The provisional crowns were made conventionally over the abutments. Once the peri-implant tissue had regenerated and the preparations for the on-teeth prostheses were finalized, zirconia copings were made using CAD/CAM technology for the 4 teeth (11 and 12 over tooth/ 21 and 22 over abutment). After the copings had been tried and a periapical x-ray taken to confirm the placement, a transfer impression was made to apply the ceramic. The crowns were then adjusted and cemented with resinous cement.

Result description and/or conclusion

In the 1st year of monitoring, excellent behavior of the bone tissue and soft tissue was observed. Considering the area (anterior), the remaining available bone for implant placement and the patient's broad smile, the result obtained was highly satisfactory.



DR. GENINHO THOMÉ

ltrojan@neodent.com.br

BRASIL

Masters and PhD in Implantology.
Scientific Chairman Neodent.
Chairman of the Board of Directors of Neodent.

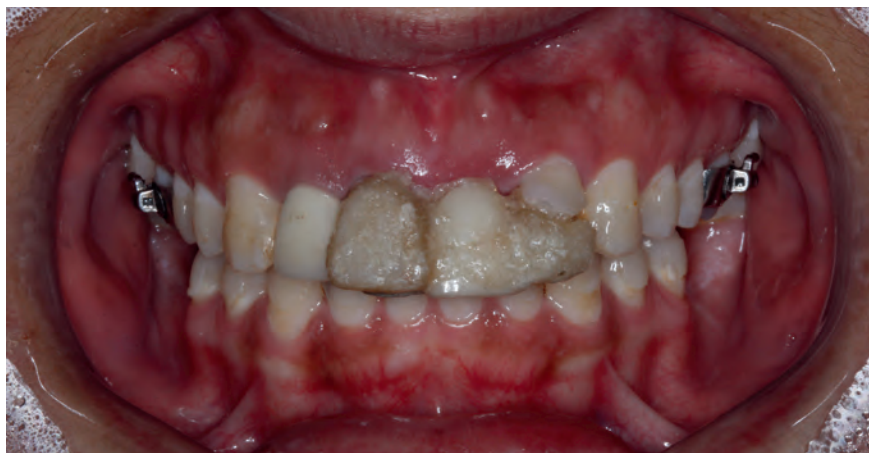Other doctors that participated in the procedure:

Sérgio Bernardes;
Mary Stella Dias Vitório;
Carolina Accorsi Cartelli;
Larissa Trojan.

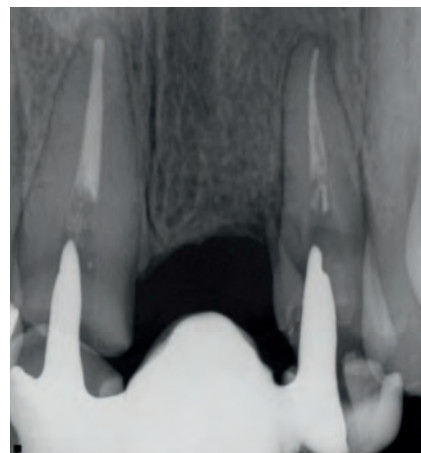
www.neodent.com.br/grandmorse

Neodent Grand Morse

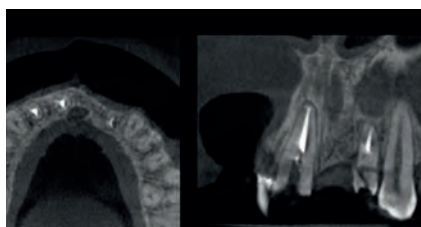
Rehabilitation with Grand Morse implants and digital flow.



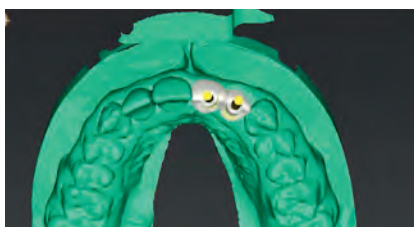
1. Initial intra oral view.



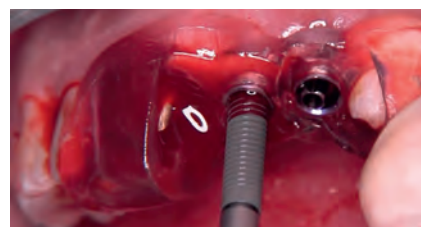2. Initial x-Ray.



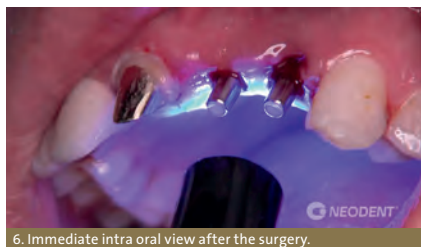3. Initial tomography.



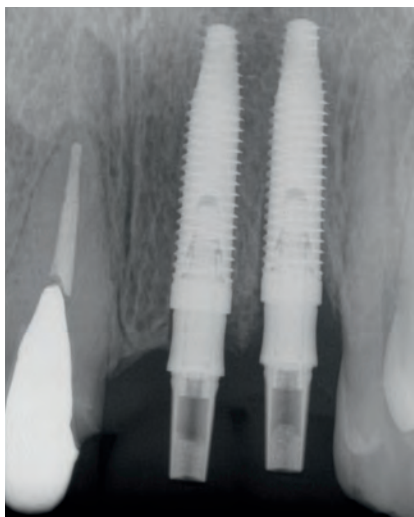4. Planning.



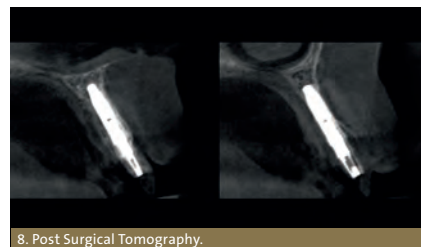
5. Implant Placement.



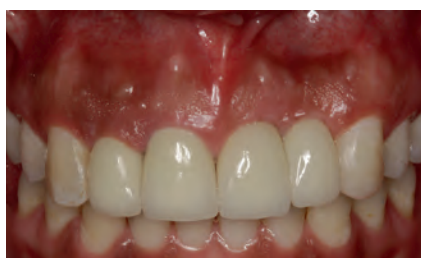6. Immediate intra oral view after the surgery.



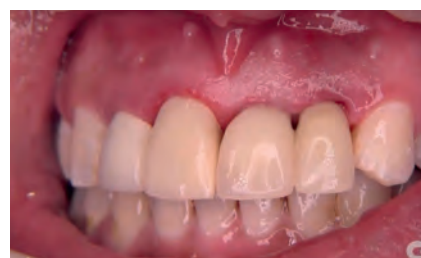7. Immediate Post Surgical x-Ray.



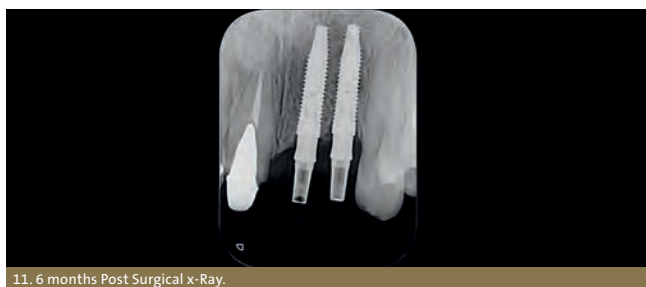8. Post Surgical Tomography.



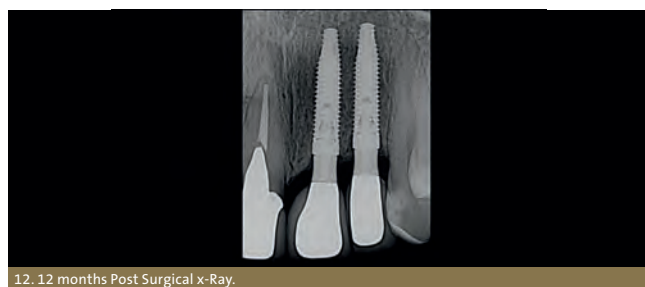9. Final retoration (intra oral view).



10. Provisional (intra oral view).



11. 6 months Post Surgical x-Ray.



12. 12 months Post Surgical x-Ray.

— CLINICAL CASE

Grand Morse

Immediate Load Double Arch.

Patient's Medical History

Female, age 39.

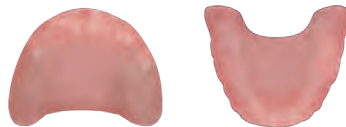
Recovered drug addict, long term smoker, poor compliance and poor nutrition. Heart disease, heart attack, cardiac stent, clopidogrel, mild arthritis, hay fever, allergic to tomatoes, binge drinking. Regular blood tests since rehab.

Planning

Full Arch.

Immediate Loading Protocol.

With Flap Access Technique.



©neodent

Description of the procedure

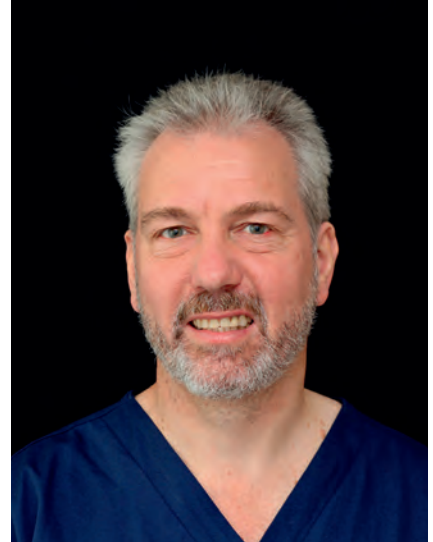Local anaesthetic dental clearance, ridge reduction in areas of sockets, placement of upper and lower NeoArch using Titamax GM Acqua on lower and Titamax CM Acqua on upper. Lower posterior (35;45) 4x15mm with 30 degree miniconical abutments, lower anterior 4x11mm straight miniconical abutments. Upper posterior (15) 3.5 x17 (25) 3.75 x15 with 30 degree miniconical abutments, Upper anterior 3.75 x11 with 17 degree abutments. All implants placed with motor driver at 45 Ncm and abutments placed at 15 Ncm. Immediate onto prefabricated acrylic bridges using titanium temporary copings at 10Ncm.

Prosthetic description

Surgery undertaken 12/01/2018. Two month integration check 26/02/2018. Final impressions due 26/03/2018. Createc bars, acrylic wrap following wax try-in.

Result description and/or conclusion

Double arch acrylic wrap.



DR ROBERT N HAYES

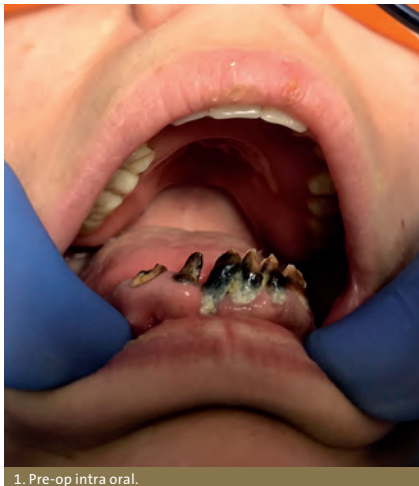
rnhayesbds@aol.com
UNITED KINGDOM

Dr Hayes is a Royal College of Surgeons accredited implant training mentor and holds the Certificate in Advanced Implant Dentistry. He has undertaken research on immediate loading of single implants and Quad Zygoma and was the first surgeon outside the USA to undertake an immediate load double arch in 2006 using the NobelGuide All-on-4 technique. Robert provides live surgery courses for Neodent UK and mentors surgeons at all levels in all aspects of implant dentistry and related surgery.

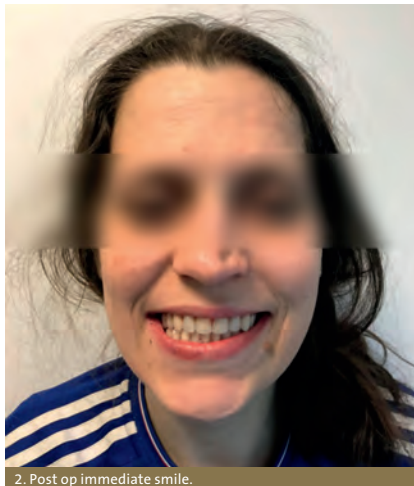www.neodent.com.br/grandmorse

Neodent Grand Morse

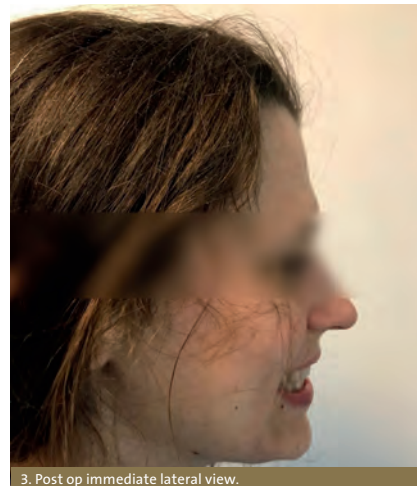Immediate Load Double Arch.



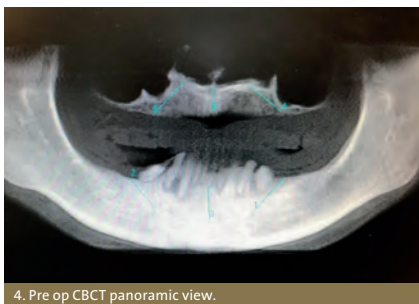1. Pre-op intra oral.



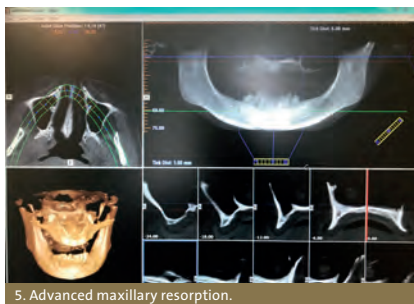
2. Post op immediate smile.



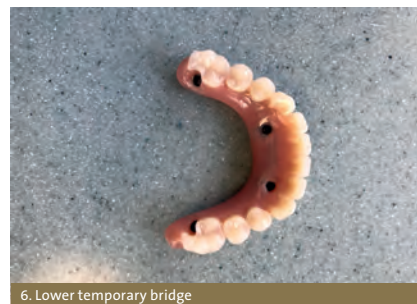3. Post op immediate lateral view.



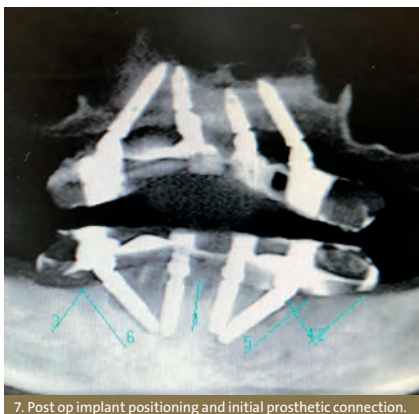4. Pre op CBCT panoramic view.




5. Advanced maxillary resorption.




6. Lower temporary bridge



7. Post op implant positioning and initial prosthetic connection.



8. Helix Grand Morse Implant.



9. Final extra oral photo

— CLINICAL CASE

Grand Morse

Neodent Grand Morse

Neodent GM Helix Acqua implant in the aesthetic zone.

Patient's Medical History

Patient is female, aged 55, and has a clear medical history.

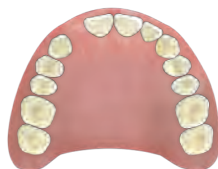Planning

Single Case.

Position 12 of the Maxilla (FDI System).

Conventional Loading Protocol.

With Flap Access Technique.



Description of the procedure

1. Full Mucoperiosteal flap, denudung of the bone surface with small perforations to improve the blood supply to receive the allograft block. The block was secured with one fixation screw then carnally and apically xenograft and autogenous chips were placed. This was covered with a slow resorbing collage membrane;
2. Re-entry at 6 months for implant placement well away from the labial plate and planned for screw retained prosthesis. Transmucosal healing abutment place and sutured to also move the much-gingival line more apically;
3. Transfer impressions with an open tray technique taken 3 months later;
4. Day of fit of the screw retained implant Emax crown on a Ti-base abutment. The tissues have yet to mature.

Result description and/or conclusion

To review for mucosal tissue maturity and possible future connective tissue graft to assess if further vertical tissue augmentation could be gained. The patient is very happy and was aware from the start that the clinical crown would be longer than the contra lateral counterpart due to the original bone peaks f the adjacent teeth of the site prior to any surgical procedures.



DR. SANJAY SETHI

sanjsmdc7@gmail.com

UNITED KINGDOM

Sanjay Sethi qualified from Guy's Hospital in 1993 with BDS. He is in private practice in London and has a special interest in aesthetics and implants in dentistry.

He has lectured extensively internationally. He is a full member and Past President of the British Academy of Aesthetic Dentistry, an active member of the European Academy of Esthetic Dentistry and is also a member of the ADI.

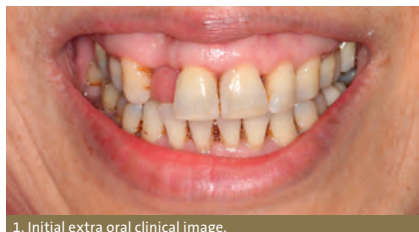Other doctors that participated in the procedure:

DR. RICHARD O'BRIEN

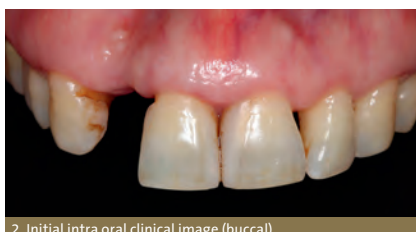www.neodent.com.br/grandmorse

Neodent Grand Morse

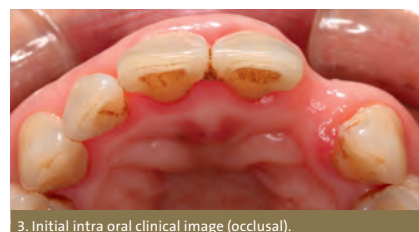Neodent GM Helix Acqua implant in the aesthetic zone.



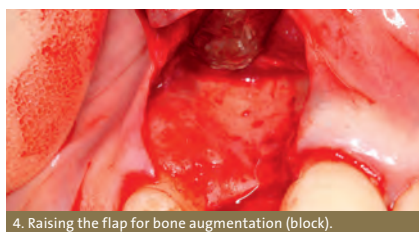
1. Initial extra oral clinical image.



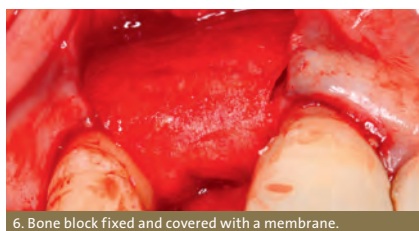2. Initial intra oral clinical image (buccal).



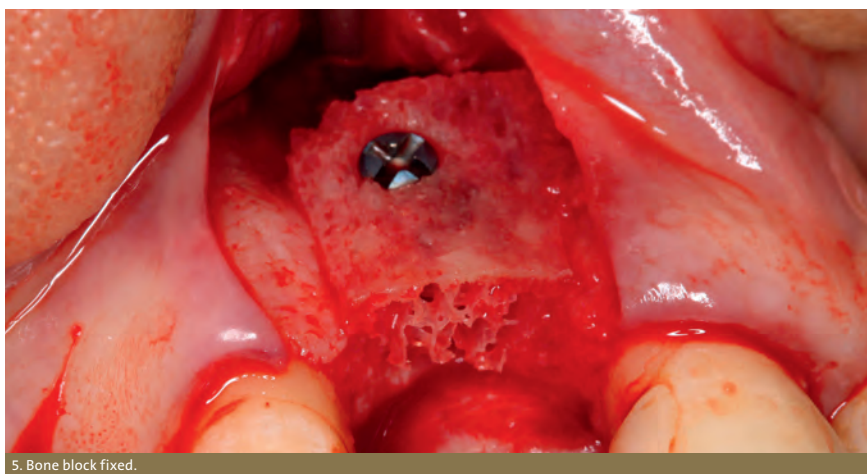
3. Initial intra oral clinical image (occlusal).



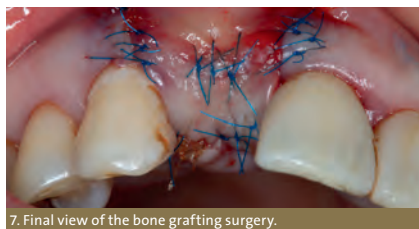4. Raising the flap for bone augmentation (block).



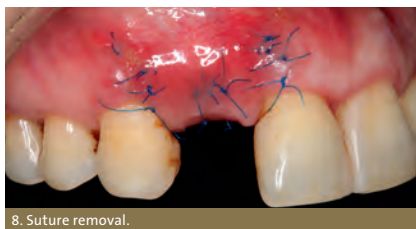
6. Bone block fixed and covered with a membrane.



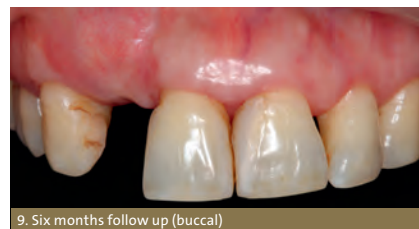5. Bone block fixed.



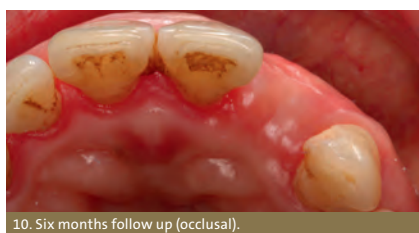7. Final view of the bone grafting surgery.



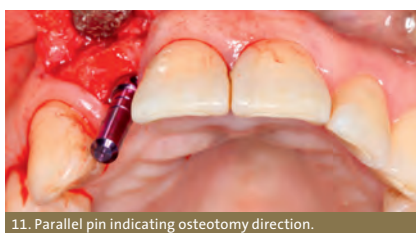8. Suture removal.



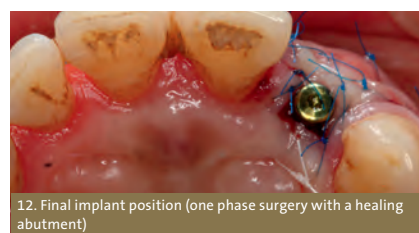9. Six months follow up (buccal)



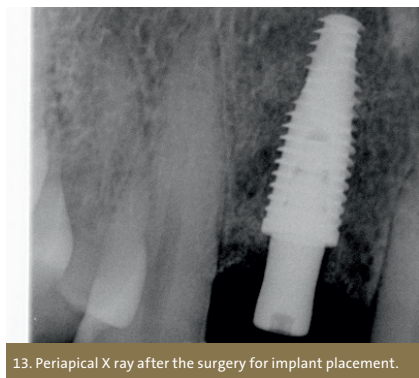
10. Six months follow up (occlusal).



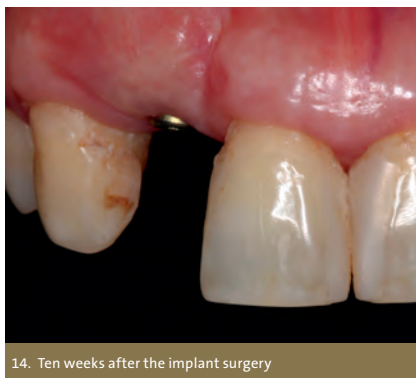
11. Parallel pin indicating osteotomy direction.



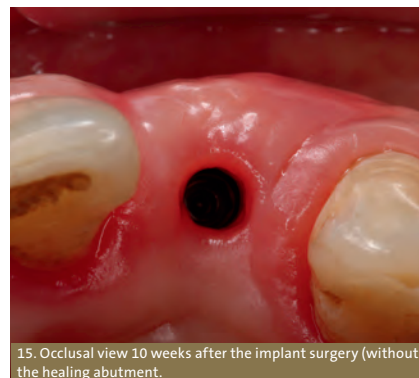12. Final implant position (one phase surgery with a healing abutment)



13. Periapical X ray after the surgery for implant placement.



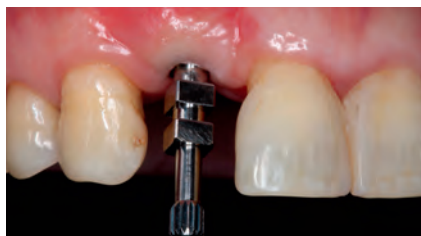14. Ten weeks after the implant surgery



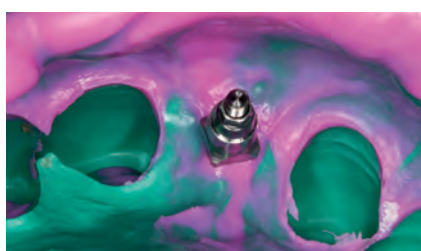15. Occlusal view 10 weeks after the implant surgery (without the healing abutment).

Neodent Grand Morse

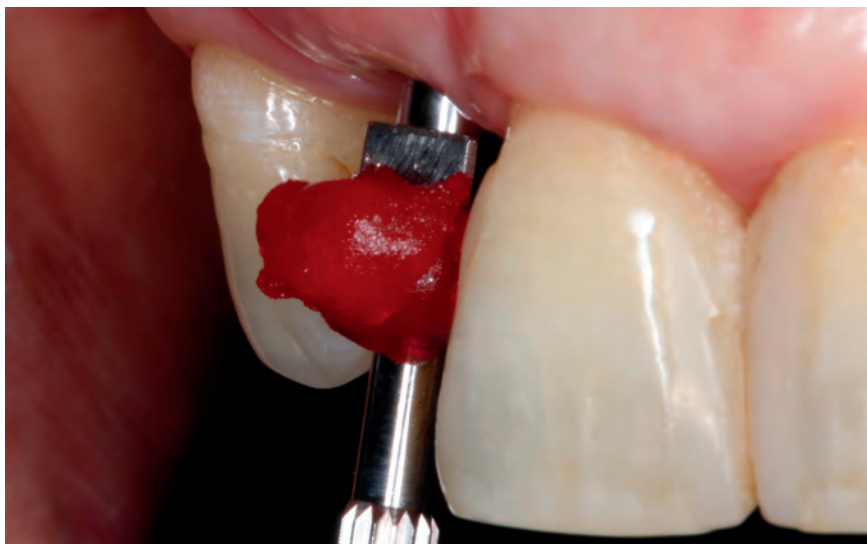
Neodent GM Helix Acqua implant in the aesthetic zone.



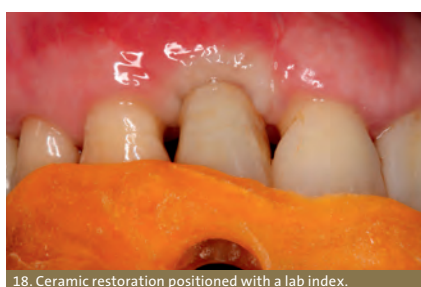16. Open tray impression at the implant level.



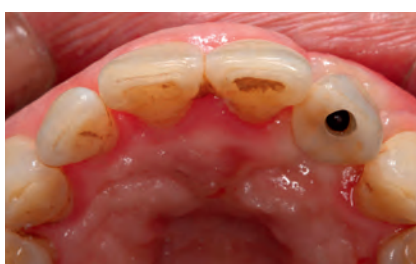18. Implant impression.



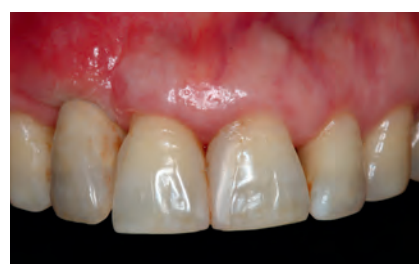17. Open tray impression coping with resin



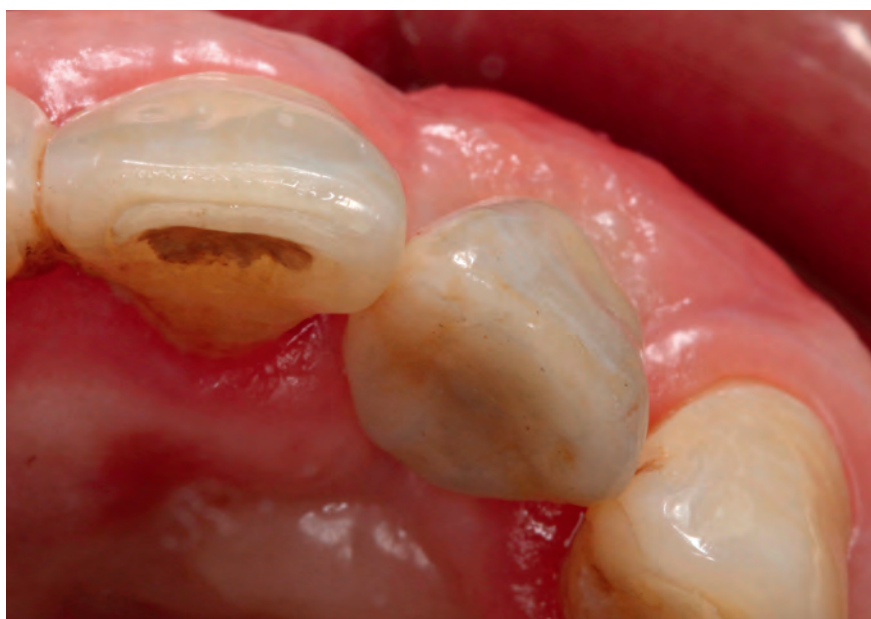18. Ceramic restoration positioned with a lab index.



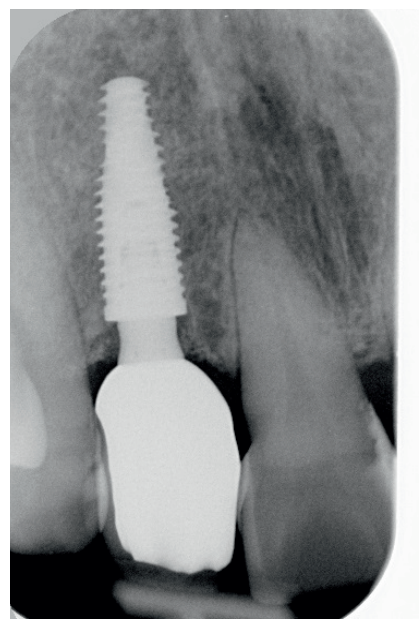
19. Occlusal view of the final restoration.



19. Buccal view of the final ceramic restoration.



20. Final occlusal view of the restoration with the screw access restored.



21. Final periapical view.

— CLINICAL CASE

Grand Morse

Single replacement with GM implant.

Patient's Medical History

Patient in orthodontic treatment, referred for implant and prosthesis placement in the region 46.

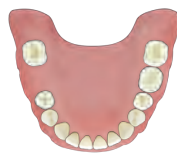Planning

Single Case.

Position 46 of the Mandible (FDI System).

Immediate Loading Protocol.

No Flap Access Technique..



Description of the procedure

A flap opening was made and drilling done to place a Grand Morse Helix implant of 3.75x 11.5. The drilling was done up to 13mm so that the final position would be subcrestal. Since the bone quality proved to be more medullar, the conical contour drill was not used.

Prosthetic Description

Once the implant was placed, a Universal Exact Click abutment of 4.5x4x3.5 was adapted. After application of torque (32Ncm), one coping was placed and the provisional crown made directly in the mouth, using a stock tooth.

The crown was cemented after using the technique of removing the excess cement in the analog. Suturing was done after the crown was cemented..

Result description and/or conclusion

The implant used for rehabilitation of the missing tooth proved highly efficient. The primary stability obtained was good, allowing immediate placement of the crown, which pleased the patient.



DR. IVETE A. DE MATTIAS SARTORI

ivetesartori@uol.com.br

BRASIL

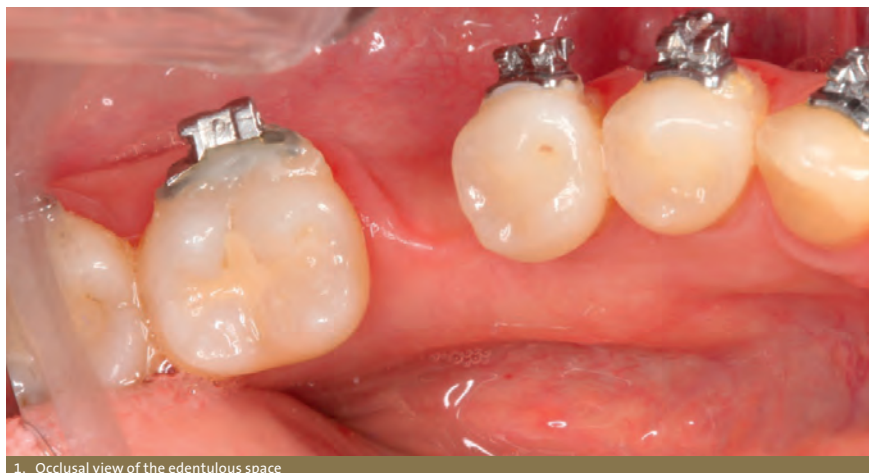Masters and PhD in Oral Rehabilitation- FORP-USP.
Professor of Specialization Courses (Fundect-USP-SP and Profis-Bauru) and Implantology Skills (Mollaris-Portugal and COESP-João Pessoa).

Other doctors that participated in the procedure:

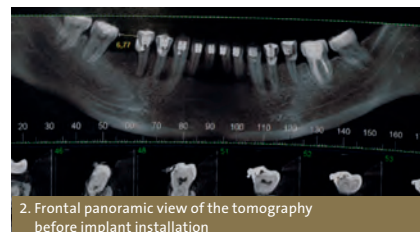DR. ELISA MATTIAS SARTORI

www.neodent.com.br/grandmorse

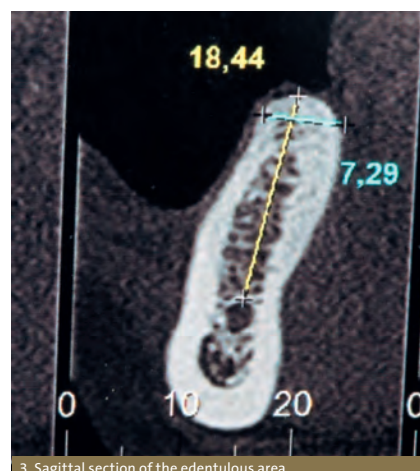
Single replacement with GM implant.



1. Occlusal view of the edentulous space



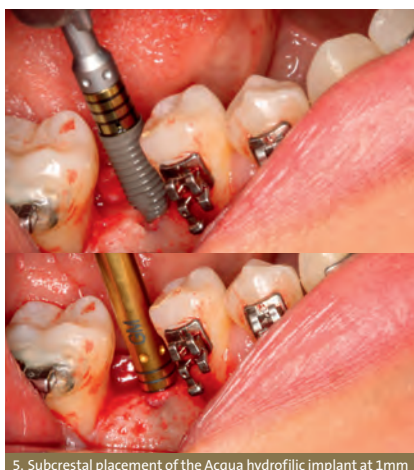2. Frontal panoramic view of the tomography before implant installation



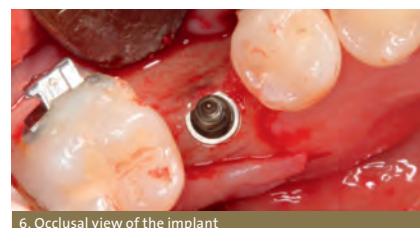
3. Sagittal section of the edentulous area.



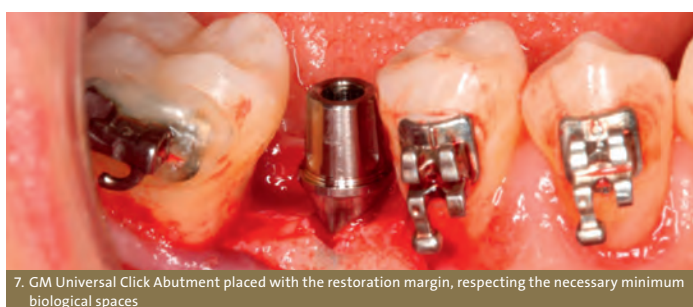4. Helix Acqua implant and Universal Click Abutment



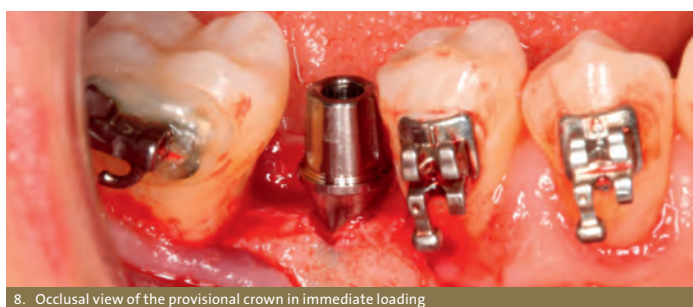5. Subcrestal placement of the Acqua hydrophilic implant at 1mm



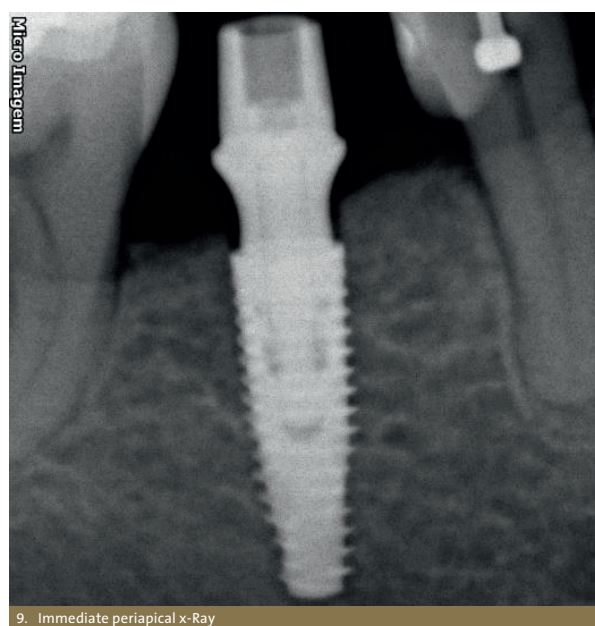
6. Occlusal view of the implant



7. GM Universal Click Abutment placed with the restoration margin, respecting the necessary minimum biological spaces



8. Occlusal view of the provisional crown in immediate loading



9. Immediate periapical x-Ray

— CLINICAL CASE

Grand Morse

Immediate implant with GM immediate loading.

Patient's Medical History

Patient ASA 1, with no prior history of systemic involvement. The patient showed prior oral rehabilitation with some implants and crowns on teeth and radicular fracture of tooth 15.

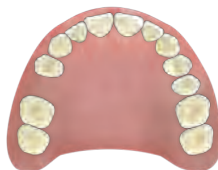
Planning

Single Case.

Position 15 of the Maxilla (FDI System).

Immediate Loading Protocol.

No Flap Access Technique..



©neodent

Description of the procedure

The surgical procedure was performed using virtual guided surgery (Neodent Guided Surgery) after removing a fractured root with the least possible trauma using the Neodent dental extractor. After extraction, vigorous curettage of the surgical socket was performed and placement of the GM Helix implant after guided osteotomy. After placement, the gap between the implant and buccal wall was filled with biomaterial (bovine origin) and then, since the implant achieved excellent initial torque, an universal abutment and provisional crown were placed.

Prosthetic Description

The provisional prosthetic solution was made in a conventional way with an acrylic resin crown rebased on the provisional coping of the selected universal abutment. After 30 days of healing the universal abutment was molded with the transfer impression coping of the universal abutment and a zirconia coping was used made of CAD/CAM technology.

Result description and/or conclusion

The final result was highly satisfactory with maintenance of bone volume and buccal contour around the implant. The peri-implant tissue reacted well with healthy appearance of gingival tissue. The definitive crown made in just over 30 days from implant placement, using the concept of “one abutment, one time”, was only possible thanks to the primary stability of the Helix implant and the bone healing potential of the Acqua surface, allowing predictability in the success of the implant submitted to full occlusal loading in a short time.



DR. GLAUCO VELLOSO

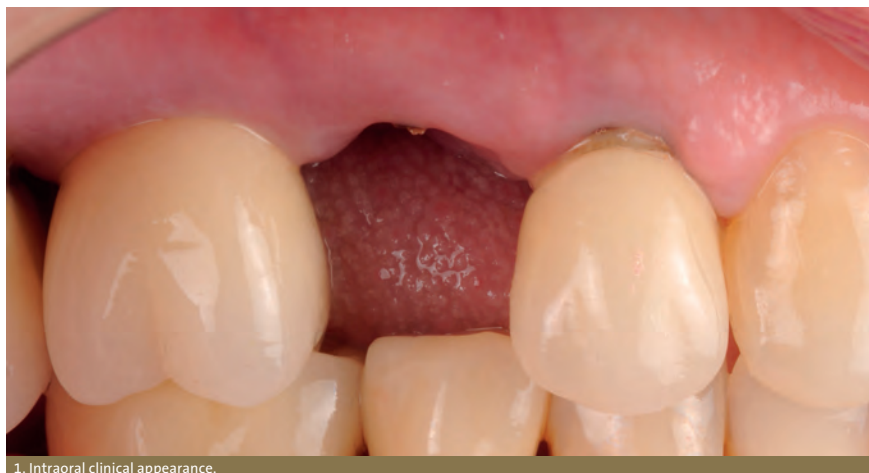glaucovelloso@uol.com.br

BRASIL

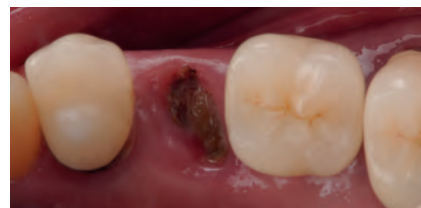Specialist in Periodontology; Specialist and Masters degree in Implantology; PhD in Dentistry; Professor of implantology at Universidade Federal Fluminense / RJ; Scientific Consultant for Neodent .

www.neodent.com.br/grandmorse

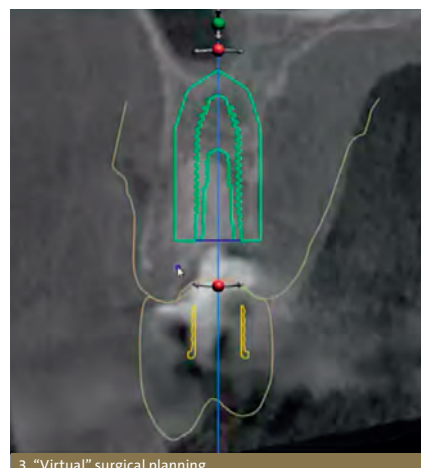
Immediate implant with GM immediate loading.



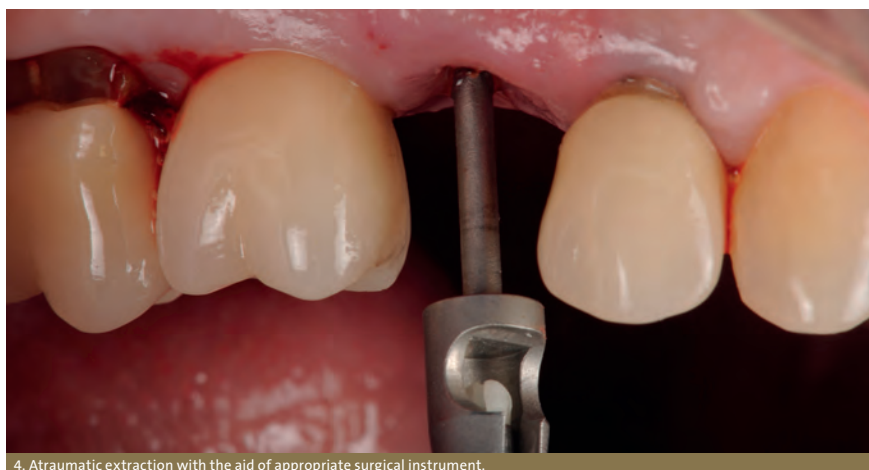1. Intraoral clinical appearance.



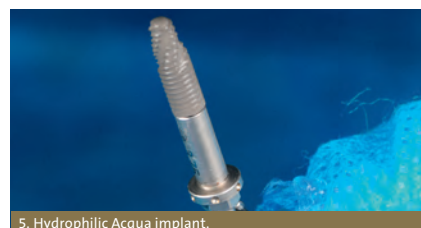
2. Intraoral clinical occlusal view.



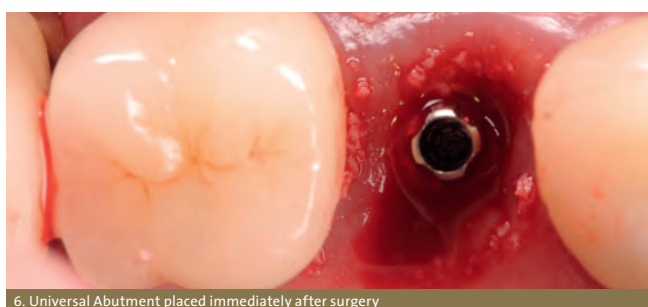
3. "Virtual" surgical planning.



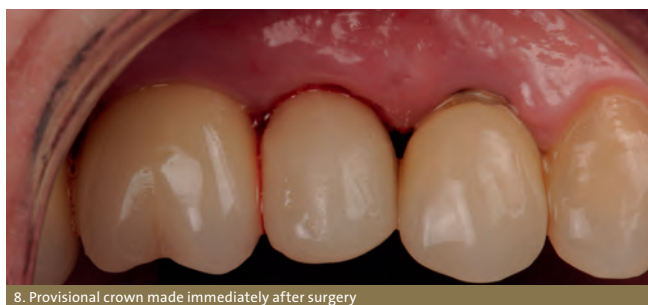4. Atraumatic extraction with the aid of appropriate surgical instrument.



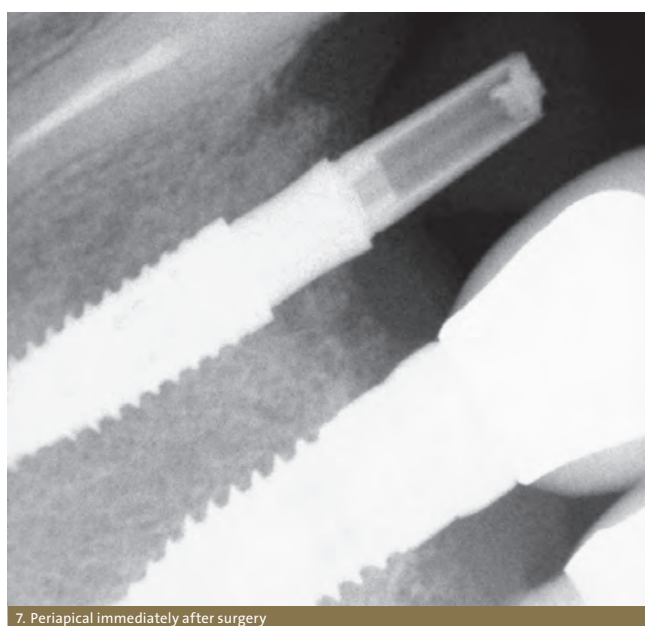
5. Hydrophilic Acqua implant.



6. Universal Abutment placed immediately after surgery



8. Provisional crown made immediately after surgery



7. Periapical immediately after surgery

— CLINICAL CASE

Grand Morse

Implant with Immediate Loading and Gingival Graft.

Patient's Medical History

Patient is aged between 18 and 30 years old, female gender. Reports good health, no allergies. Patient is non-smoker and has no infectious or contagious disease. Does not take any continuous medication. First appointment was scheduled in the 19th of June 2017.

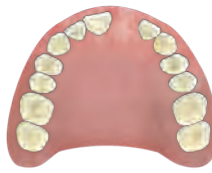
Planning

Single Case.

Position 21 of the Maxilla (FDI System).

Immediate Loading Protocol.

No Flap Access Technique.



©neodent

Description of the procedure

- 1 - Atraumatic extraction.
- 2 - Curettage and inspection of the socket.
- 3 - Start of drilling using Prototype Guide and Start Kit.
- 4 - Drilling up to drill 3.75.
- 5 - Placement of Implant 3.75 x 13mm.
- 6 - Placement and customization of the Abutment.
- 7 - Fabrication of the provisional crown.

Prosthetic Description

Provisional prosthesis made with stock tooth and rebased with acrylic resin. Screw-retained provisional technique with a Universal abutment torqued at 20 Ncm.

Result description and/or conclusion

Patient was clinically assessed at 15 days, x-rayed in the same period. Reported excellent post-operative condition and satisfaction with the result obtained.



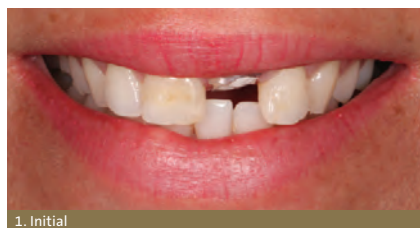**DR. ELCIO MARCANTONIO
JUNIOR**

junior.elcio@gmail.com
BRASIL

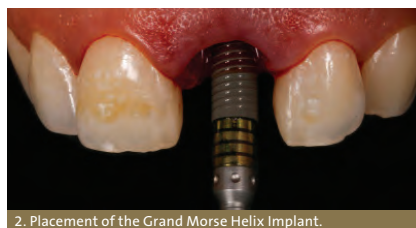
Professor of Periodontology and Implantology at the School of Dentistry of Araraquara - UNESP; Coordinator of the Specialization Course in Implantology Araraquara - UNESP; Professor at the Faculdade ILAPEO.

www.neodent.com.br/grandmorse

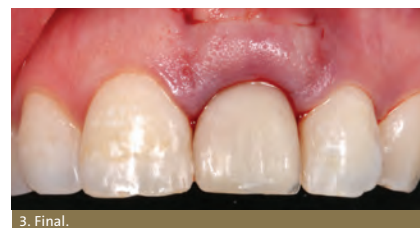Implant with Immediate Loading and Gingival Graft.



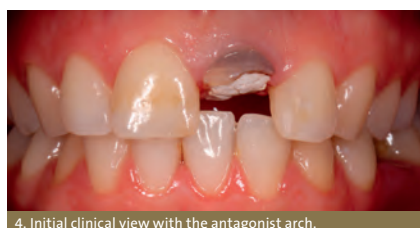1. Initial



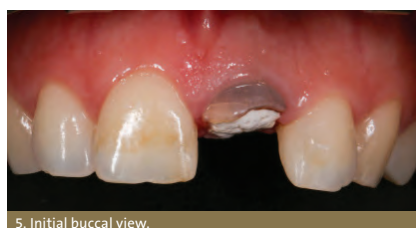2. Placement of the Grand Morse Helix Implant.



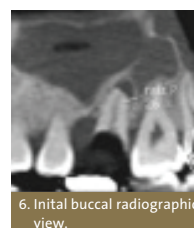3. Final.



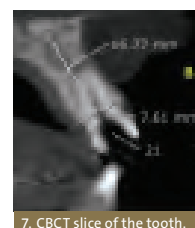4. Initial clinical view with the antagonist arch.



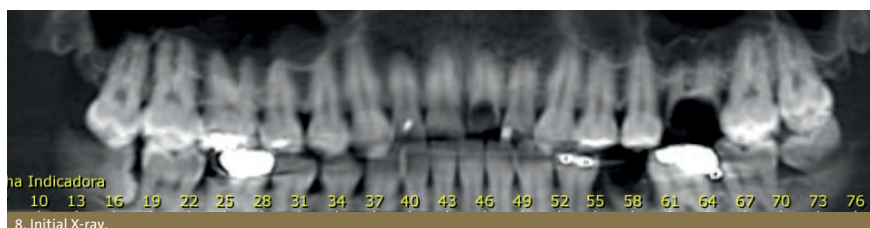
5. Initial buccal view.



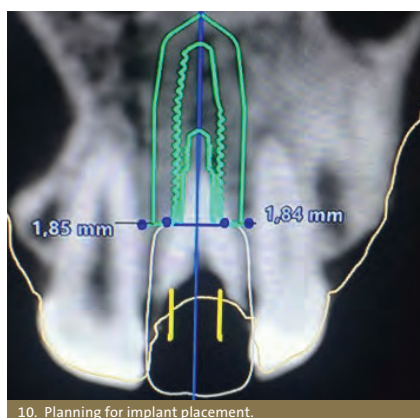
6. Initial buccal radiographic view.



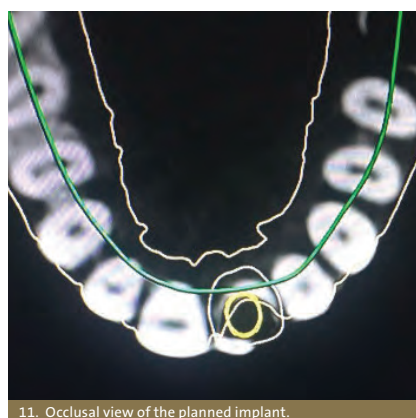
7. CBCT slice of the tooth.



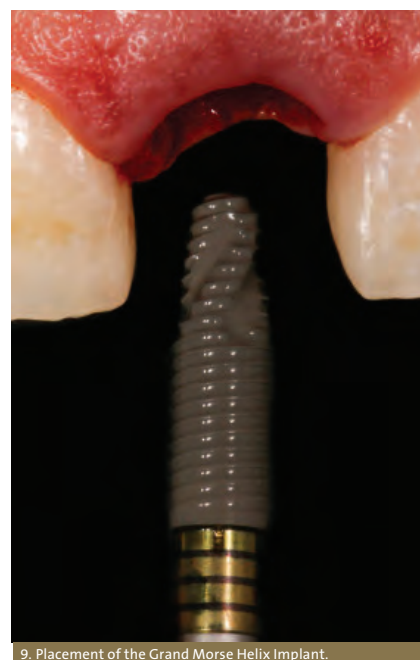
8. Initial X-ray.



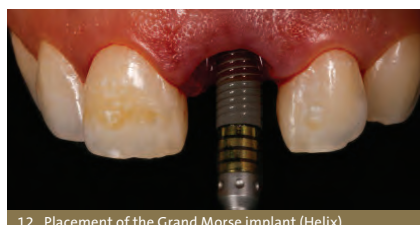
10. Planning for implant placement.



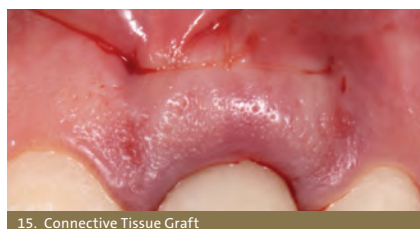11. Occlusal view of the planned implant.



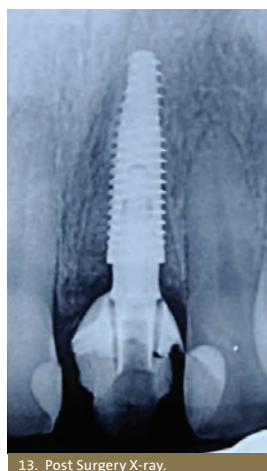9. Placement of the Grand Morse Helix Implant.



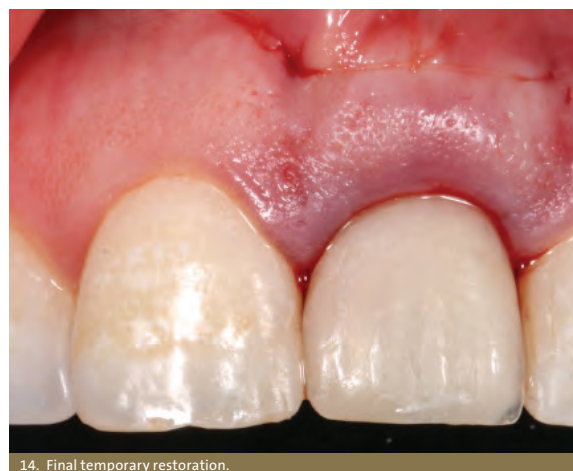12. Placement of the Grand Morse implant (Helix).



15. Connective Tissue Graft



13. Post Surgery X-ray.



14. Final temporary restoration.

— CLINICAL CASE

Grand Morse

Neodent Grand Morse

GM HELIX Implant with Immediate Loading in Upper Canine.

Patient's Medical History

Male patient, aged 18, leucoderma, ASA 1, without systemic complications for dental implant surgery, with tooth 23 included and impacted.

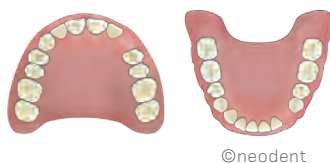
Planning

Single Case.

Position 23 of the Maxilla and 33 of the Mandible (FDI System).

Immediate Loading Protocol.

With Flap Access Technique.



Description of the procedure

After opening the flap, surgical instrumentation was initiated using the drills from the Grand Morse surgical kit to place the implants. Instrumentation was done until drill 3.75 without the use of the drills 3.75+ and pilot 3.75 due to low bone density found in the area during drilling for good primary stability of the implant, allowing immediate loading technique. Placement began with the surgical contra angle and finished with the torque wrench (final torque: 45Ncm).

Prosthetic Description

The GM Exact Universal Click abutment 3.3x6x3.5 was placed (torque: 20Ncm). The Click Provisional coping was positioned. A full provisional crown was milled in-house, filled with autopolymerizing acrylic resin and placed in the mouth over the provisional coping 3.3x6. After capture, the provisional crown was removed, with the Provisional coping inside it. After the final adjustments, the crown was cemented with Rely X Temp (3M) cement, remaining infraocclusion.

Result description and/or conclusion

The GM HELIX implant proved highly favorable for performing the immediate loading technique, offering great versatility in the instrumentation technique according to the available bone density, due to the various drills options in its Surgical Kit. The extremely easy capture is one of its great benefits, in addition to the range of similar prosthetic options to the Neodent Cone Morse implants. The provisional click coping is also a great improvement for the immediate loading technique since it facilitates intraoral capture of provisional crowns.



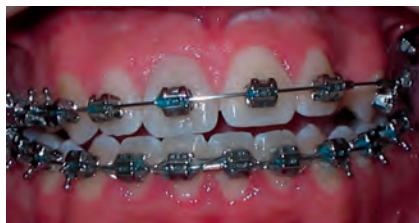MARCELO FONTES TEIXEIRA

mfontes@uol.com.br
BRASIL

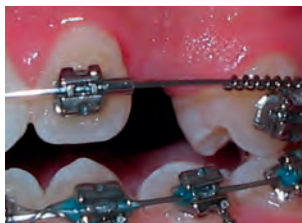Masters degree in Implantology;
Specialist in Periodontology,
Orthodontology and TMD;
Spec. Coord. Implantology (UniFOA -
VR / RJ - Brazil);
Scientific Reviewer, JOMI/EJOI - Brazil;
Scientific Consultant for NEODENT.

www.neodent.com.br/grandmorse

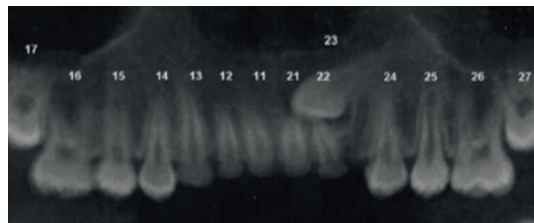
GM HELIX Implant with Immediate Loading in Upper Canine.



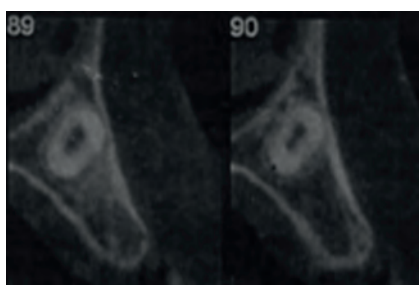
1. Frontal clinical photo.



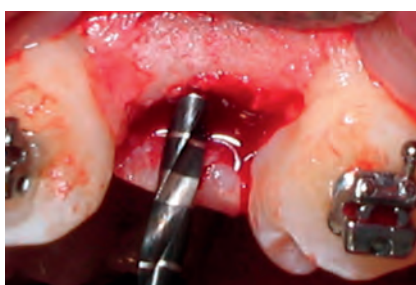2. Intraoral view of the edentulous space.



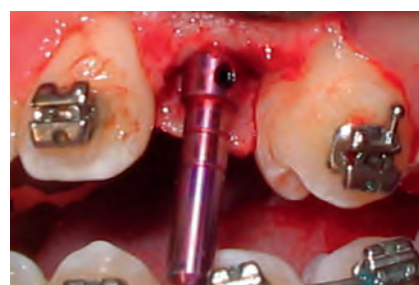3. Tomographic section of the edentulous space.



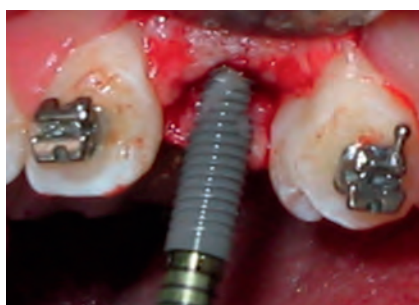4. Parasagittal section.



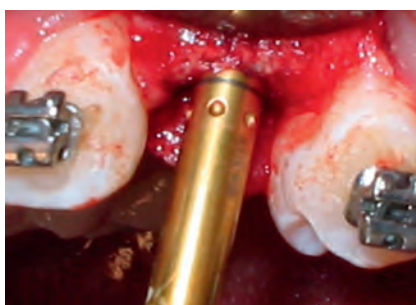5. Osteotomy with conical drills.



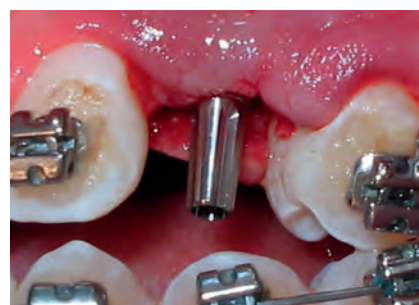6. Surgical direction indicator.



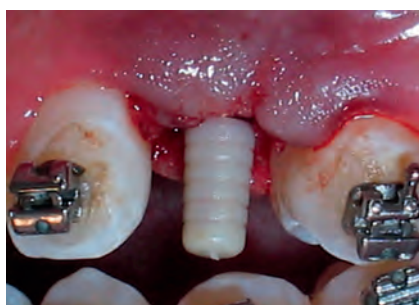7. Implant placement.



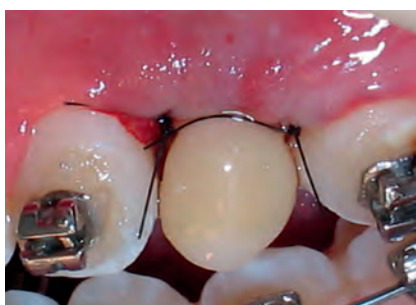8. Placement of the 2mm infra-bone implant.



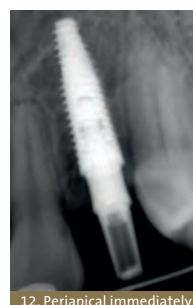9. Placement of the universal click abutment.



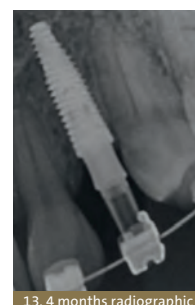10. Adjustment of the acrylic coping.



11. Provisional crown with immediate loading.



12. Periapical immediately after surgery.



13. 4 months radiographic follow up.

— CLINICAL CASE

Grand Morse

Single Immediate Loading with GM Helix Implant.

Patient's Medical History

Patient aged 34, with no systemic alterations and non-smoker. History of agenesis of the second lower left premolar with indication for implant-supported rehabilitation.

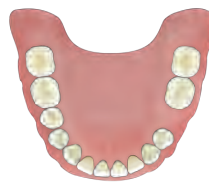Planning

Single Case.

Position 35 of the Mandible (FDI System).

Immediate Loading Protocol.

With Flap Access Technique.



Description of the procedure

Terminal infiltration anesthesia, buccal and lingual, incision over the ridge with sulcular extension on adjacent teeth and mucoperiosteal detachment. Instrumentation with drill sequence for GM Helix 4.3x10 implant. Sub-instrumentation performed due to bone quality (bone type III) with the conical 4.0 drill the last to be used. Placement of the implant with subcrestal placement and final torque of 45 Ncm. Selection of the transmucosal abutment height using the GM depth measurer. Temporary placement of the healing abutment and suture.

Prosthetic Description

Provisional prosthetic rehabilitation with immediate loading using GM Pro Peek Abutment. Placement of Transfer Exact closed-tray impression coping, transfer impression coping, placement of implant analog and obtaining of mock-up. Customization of the Pro Peek abutment and fabrication and placement of the provisional prosthesis without occlusal contact.

Result description and/or conclusion

GM Helix implant provides good stability even in bone type III, allowing rehabilitation with immediate loading.

The surgical kit of the GM implant facilitates sub-instrumentation for implants with 4.3 diameter due to option of conical drills 3.75 and 4.0.

Pro Peek Abutment is an excellent provisional crown for allowing customization.



DR. FRANCINE BALDIN ABLE

franable@gmail.com

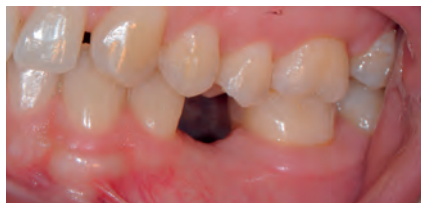BRASIL

Degree in Dentistry from UFPR (2008);
Specialist in Periodontology from
Profis (2013); Masters degree in
Implantology from ILAPEO (2015);
PhD student in Integrated Clinical
Practice at UEPG.

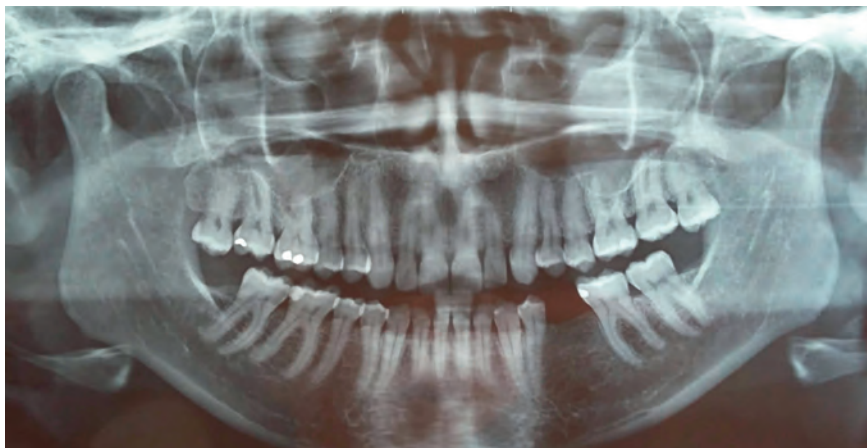
www.neodent.com.br/grandmorse

Neodent Grand Morse

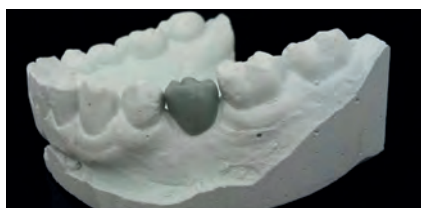
Single Immediate Loading with GM Helix Implant.



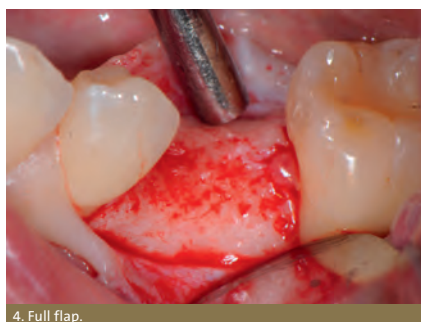1. Intraoral photo of the edentulous space.



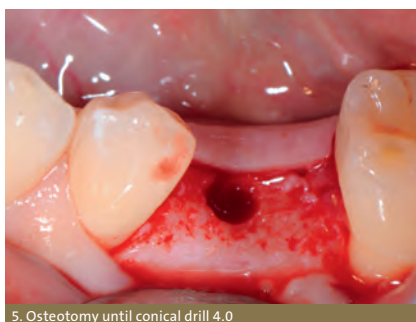2. Panoramic x-ray.



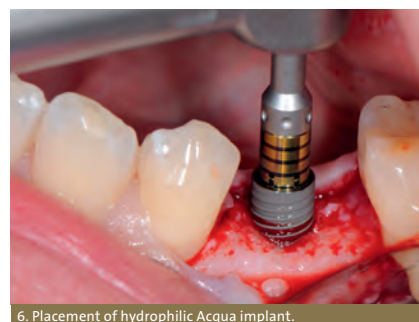3. Wax-up of the case.



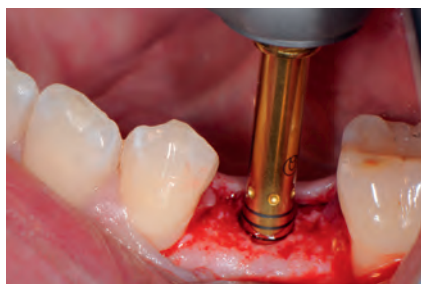4. Full flap.



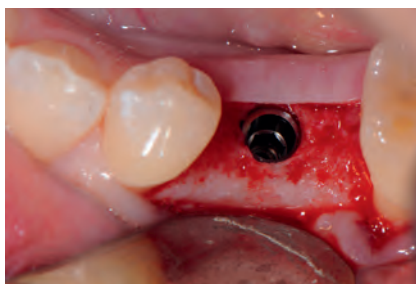5. Osteotomy until conical drill 4.0



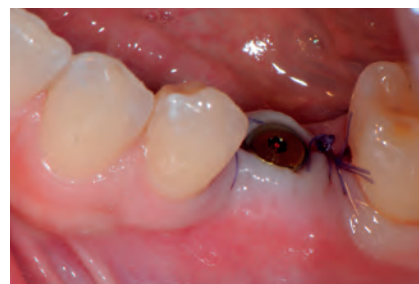6. Placement of hydrophilic Acqua implant.



7. Subcrestal placement of the implant (1mm).



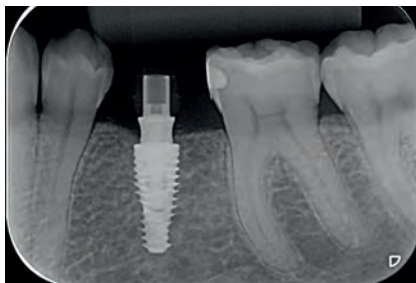
8. Subcrestal implant final position.



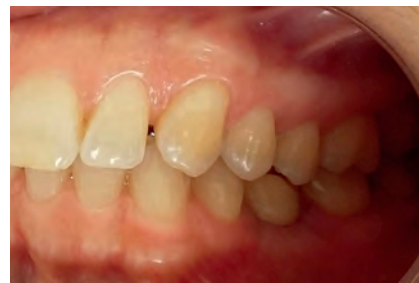9. Healing abutment immediately after surgery.



10. Pro peek abutment and Neo screwdriver.



11. Periapical X ray with the temporary crown and Pro peek abutment.



12. Final ceramic restoration.