



»» **Casebook** ««

**IPS**  
Implant Systems

**CLINICAL  
CASES**

# »» Clinical Case ««

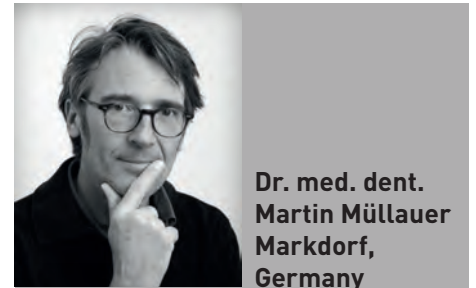## Late Implant Placement

Dr. Martin Müllauer	3
Dr. Lucky Tseng	11
Dr. Ching-Hsuan Yang	13
Dr. Shih pin Yang	15
Dr. Raimondas Savickas	17



**MICROCONE**

**Late Implant Placement with Microcone Implant**



**Dr. med. dent.  
Martin Müllauer  
Markdorf,  
Germany**

**Profile:** Male, 1960

- Clinical Situation:**
- Extraction 15 because of periodontal disease.
  - Late implantation after 14 months in combination with an intern Sinuselavation (Summertehnik).
  - Elevation with own bone harvested out of the implant-bearing and closed healing.
  - Gingivamanagement with conventional formers.
  - Prosthetics: conventional titanium abutment and cemented (Panavia) emax crown.

- Co-founder Zahnärztliche Partnerschaft Markdorf
- Certified by German Association of Implantology, DGI
- Board Member European Dental Association, EDA Germany

**Tooth Extraction**  
07/08

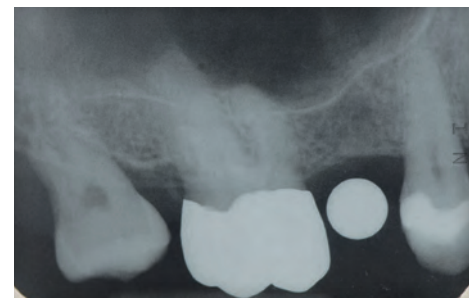
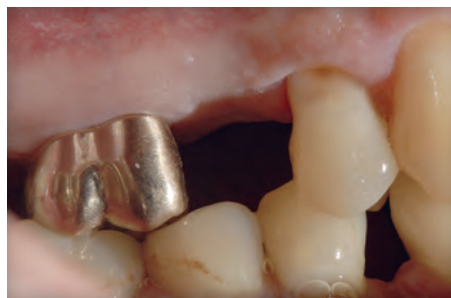

**Implant Placement**  
09/09



**Final Restoration**  
03/10

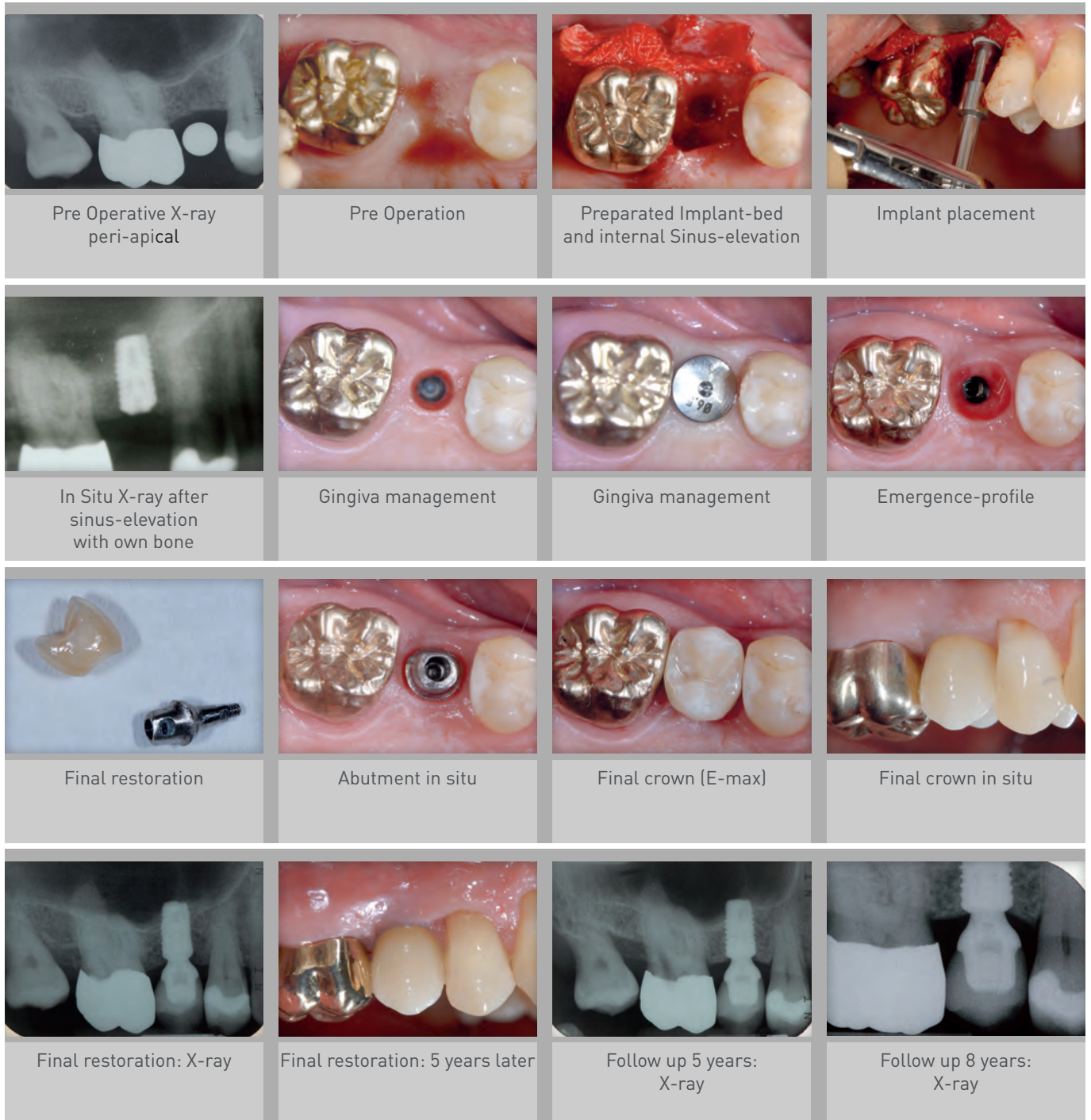
**Initial Situation**



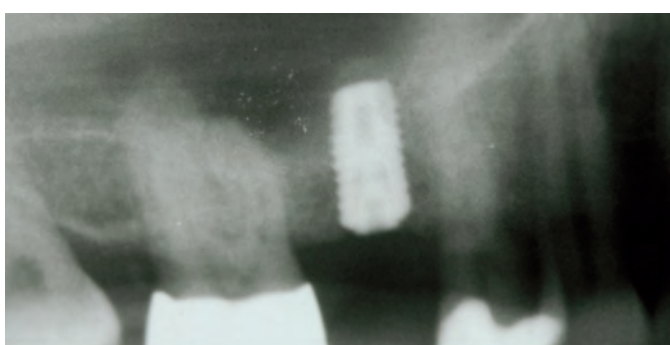
Summary	Loading Protocol (Delayed)		Surgical products	Prosthetic products
Surgical Description	Maxilla	Posterior	M-Implant D 4,0 x L 8 mm	Individualized Titanium Abutment
	1 Implant	Conventional		Emax Crown
Restorative Solution	Conventional	Emax		

# »» Clinical Case ««

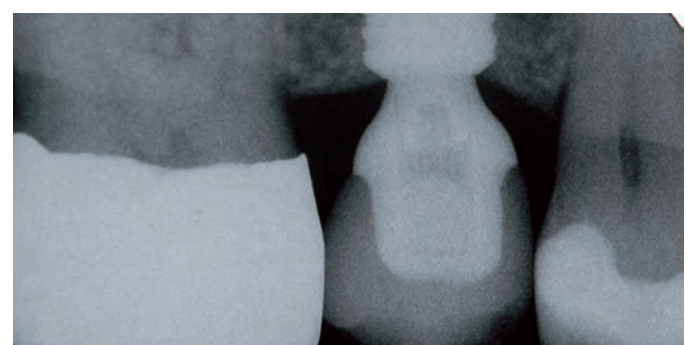
## Late Implant Placement with Microcone Implant



### Post Operative



### Follow up 8 years





**MICROCONE**

## » Clinical Case «

### Late Implant Placement with Microcone Implant

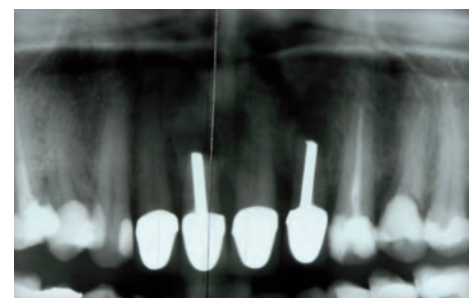
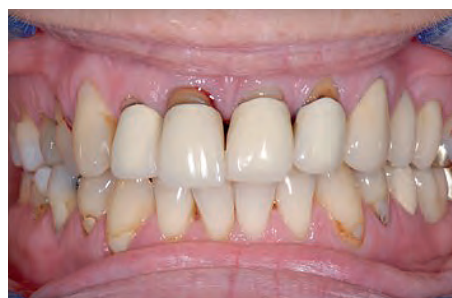
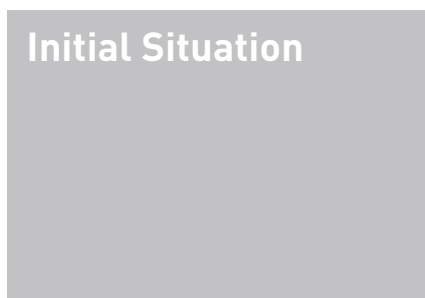
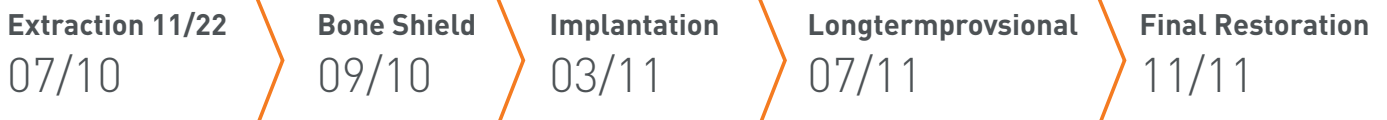**Dr. med. dent.  
Martin Müllauer  
Markdorf,  
Germany**

**Profile:** Female, 1961

- Clinical Situation:** unholdable 11 and 22 with periapical diseases. Vertical and horizontal bone loss.
- Extraction 2010.
  - Augmentation of an autologous bone-shield after 2 months.
  - Implantation and closed healing 5 months later.
  - Reentry with roll-flap-technique 4 months later.
  - Gingivamanagement with longtime-provisionals.
  - Final Emax-crowns on individual hybrid-abutments after 4 months.

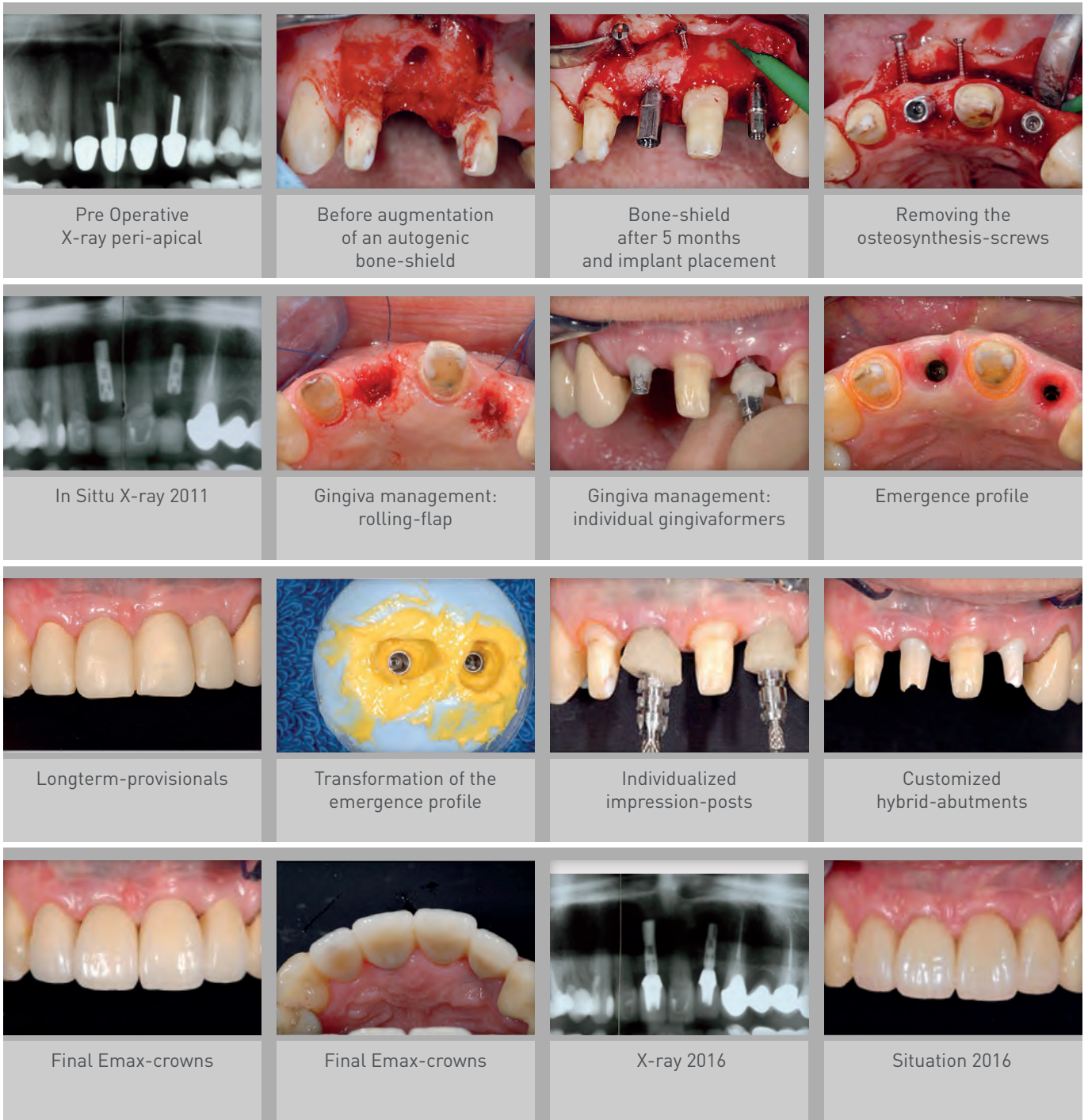
- Co-founder Zahnärztliche Partnerschaft Markdorf
- Certified by German Association of Implantology, DGI
- Board Member European Dental Association, EDA Germany



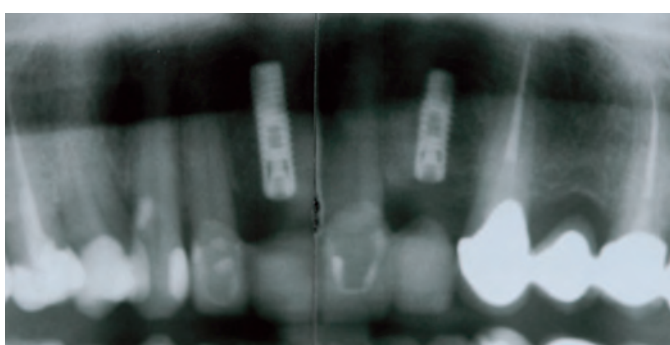
Summary	Loading Protocol (Delayed)		Surgical products	Prosthetic products
Surgical Description	Maxilla	Anterior	Osteosynthesis-screws Martin MC Implants D 4,0 x L 11 mm D 3,5 x L 11 mm	Individual hybrid Zirconium Abutments
	bone-shield, 2 Implants	Conventional		Emax Crown
Restorative Solution	individual hybrid abutments	Emax-crowns		

# »» Clinical Case ««

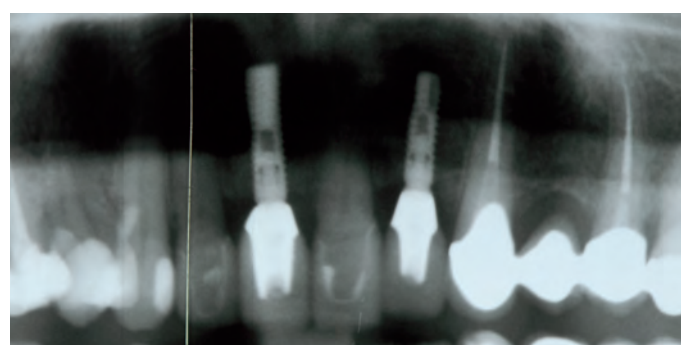
## Late Implant Placement with Microcone Implant



### Post Operative



### Follow up 6 years





**MICROCONE**  
**QUATTROCONE**



A Straumann Group Brand

## » Clinical Case «

### Late Implant Placement



**Dr. med. dent.  
Martin Müllauer  
Markdorf,  
Germany**

**Profile:** Male, 1953

**Clinical Situation:** insufficient maxillary teeth with interim prothesis, insufficient 46,48.

Max.: Interim prothesis in right plane, centric and vertical correlation, interim composite-bridge, definitivly circoniumbridge.

Mand.: Table-tops on the left side, circonium crowns on the right side.

- Co-founder Zahnärztliche Partnerschaft Markdorf
- Certified by German Association of Implantology, DGI
- Board Member European Dental Association, EDA Germany

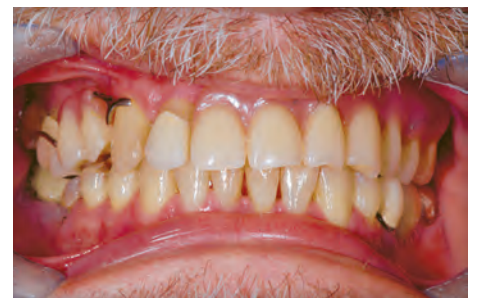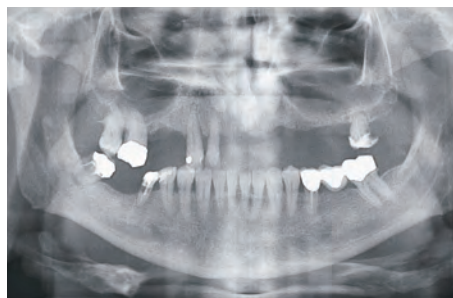**Tooth Extraction**  
03/14

**Implant Placement**  
06/14

**Provisional Restoration**  
12/14

**Final Restoration**  
02/17

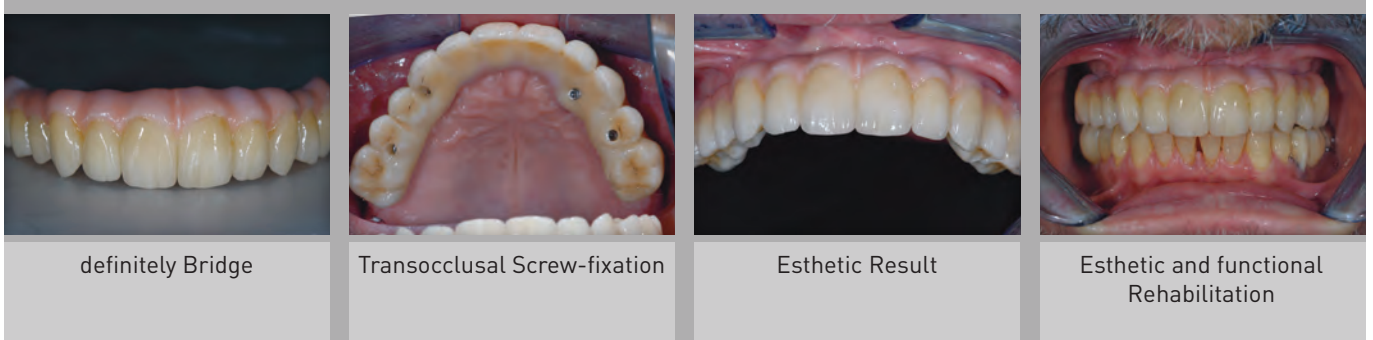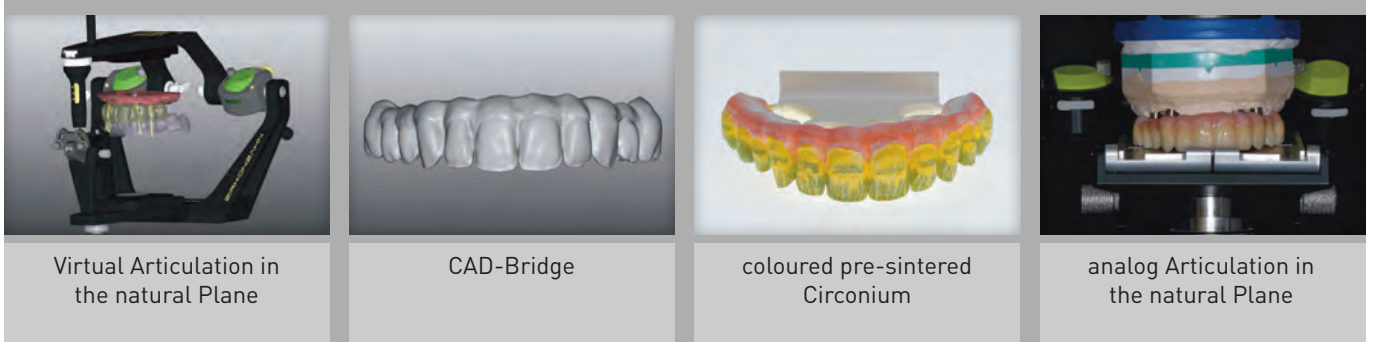
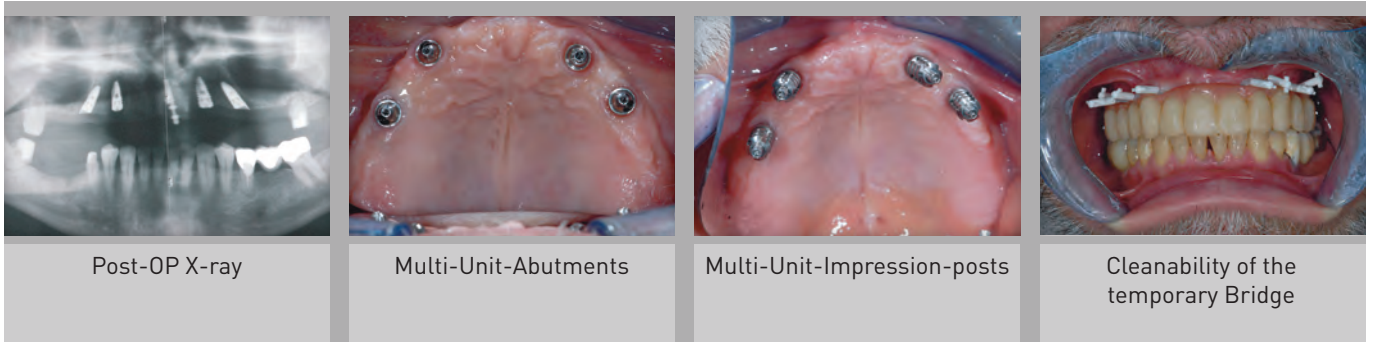
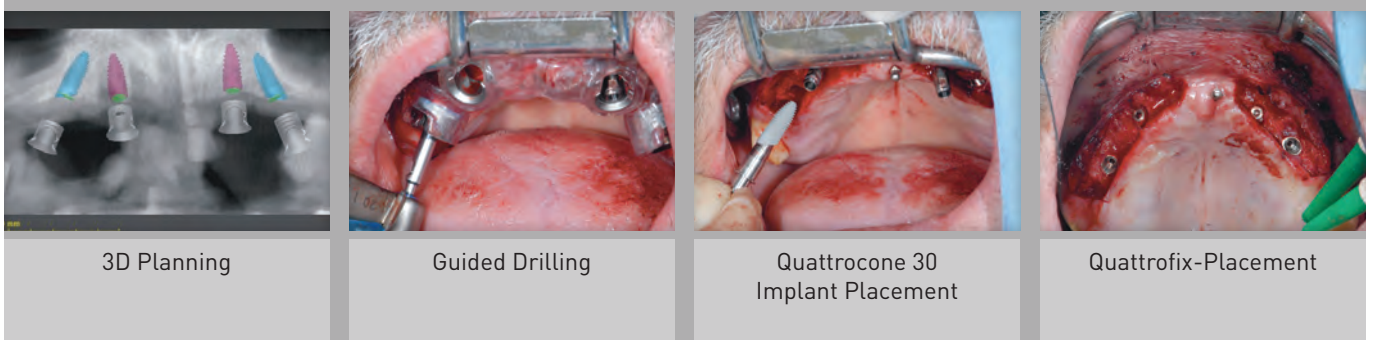
### Initial Situation



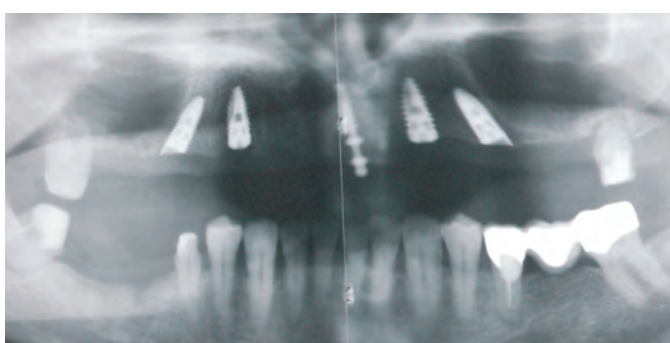
Summary	Loading Protocol (Delayed)		Surgical products	Prosthetic products
	Maxilla / Mandibular	Anterior & Posterior		
Surgery: Augmentation of own bone. Closed healing.	Maxilla / Mandibular	Anterior & Posterior	2 x QC30 Implants D 4,3 x L 11mm	Multi-units
	6 Implants	Guided & Conventional	2 x QC Implants D 3,5 x L 11mm	Multi-units
Restorative Solution	CAD/CAM	transocclusal screwed Circonium	Interimsimpl. Straumann D 2,0 x L 10mm	
			2 x MC Implants D 4,0 x L 11 mm	Ti-bases

# »» Clinical Case ««

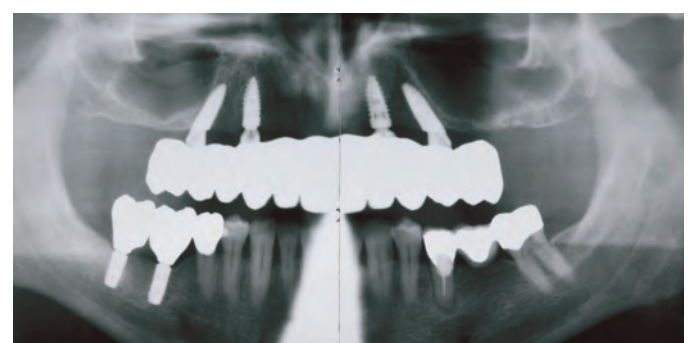
## Late Implant Placement with Microcone and Quattrocone Implants



### Post Operative



### Follow up 3,5 years







**MICROCONE**



A Straumann Group Brand

## »» Clinical Case ««

### Late Implant Placement with Microcone Implant



**Dr. med. dent.  
Martin Müllauer  
Markdorf,  
Germany**

**Profile:** Male, 1945

**Clinical Situation:** Broken Post and Root 24, Need for complete prosthetic Restoration in new centric and vertical Relation. Wish to change Bridges into single-tooth loading.

- Co-founder Zahnärztliche Partnerschaft Markdorf
- Certified by German Association of Implantology, DGI
- Board Member European Dental Association, EDA Germany

**Tooth Extraction**  
02/10

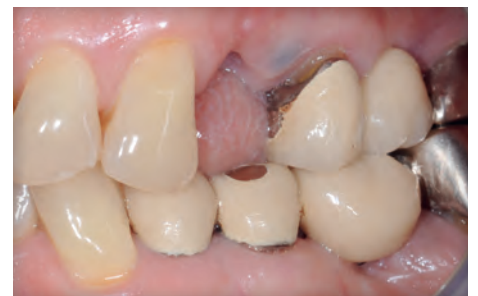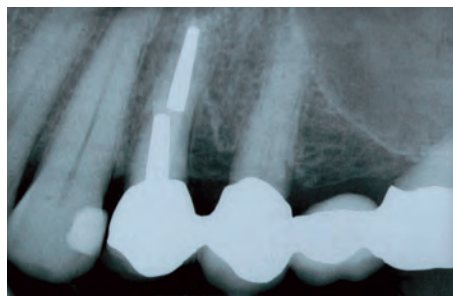


**Implant Placement**  
05/11



**Final Restoration**  
03/12

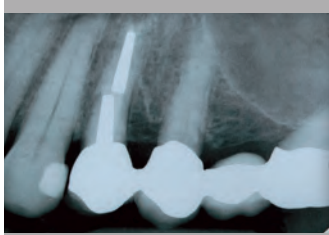**Initial Situation**



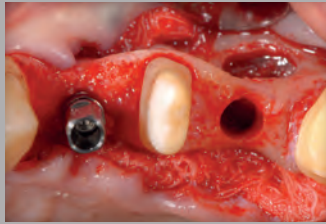
Summary	Implantation 14 Months after Extraction Loading Protocol: Delayed		Surgical products	Prosthetic products
Surgical Description	Maxilla/Mandibula	Posterior	MC Implant 26 D 4,5 x L 9 mm conical	Individualized POC Abutments
	1 Implant	Conventional/Sinnsfloor-elevation/Bonesplit	MC Implant 24 D 4,0 x L 11 mm	Emax Crown
Restorative Solution	POC-Abutments indiv.	Emax-crowns	MC Implant 36 D 4,0 x L 11 mm	

# »» Clinical Case ««

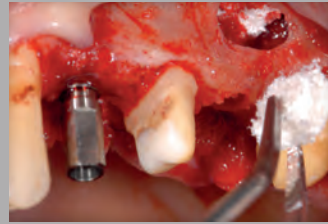
## Late Implant Placement with Microcone Implant



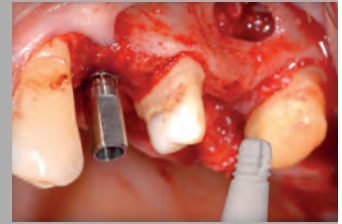24: Broken Post and Root with deep Pocket distal



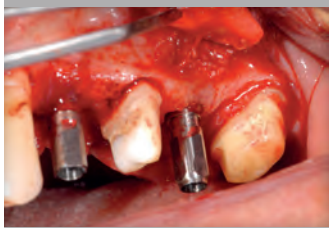Elevated Schneiderian Membrane



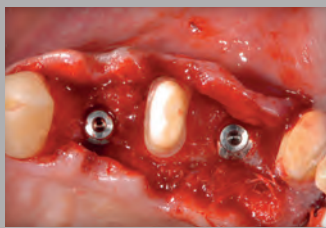Sinus-Augmentation with Bio-oss collagen



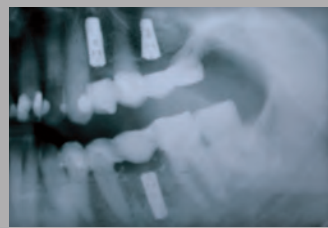Conical MC-Implant 9/4,5. Better primary-stability in thin bone-support



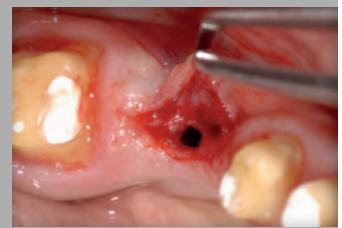Collagen-Membrane covering the Window/Augmentation



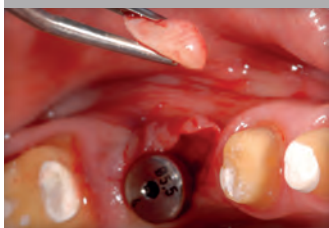Cover-screws



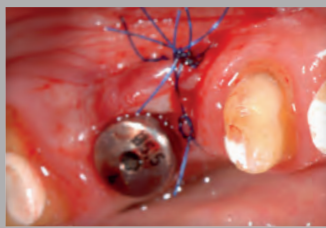Implant placement 24/26/36



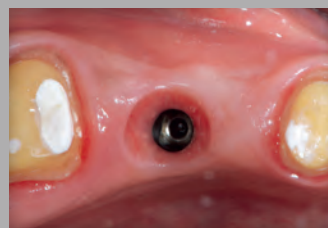Individual POC-Abutments 24/26



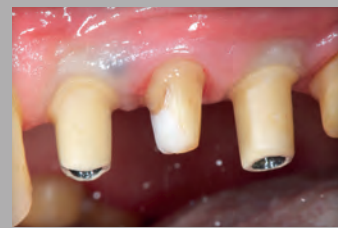Preparation of a Split-pocket 36 by Re-entry



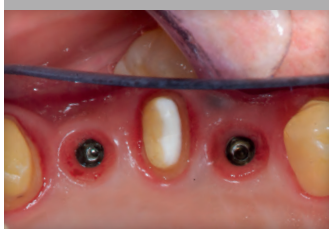Transforming a free Tissue-graft



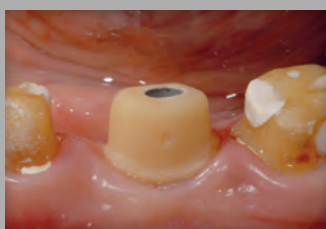Fixation for Gingiva management



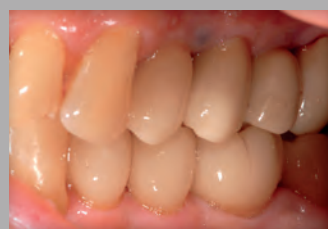Thicker Tissue for Emergence profile 36



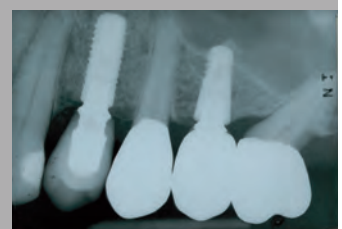Emergence profile 24/26



Individual POC-Abutment 36

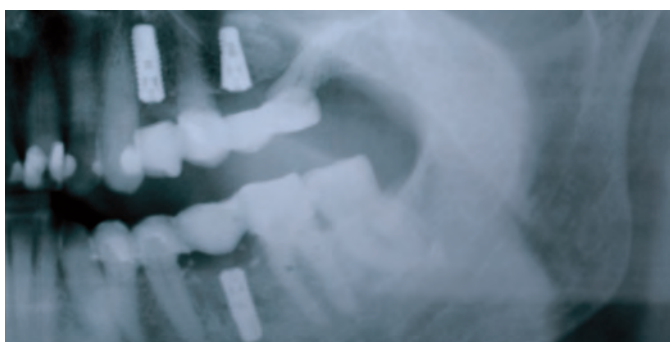

Clinical Situation after 5 Years

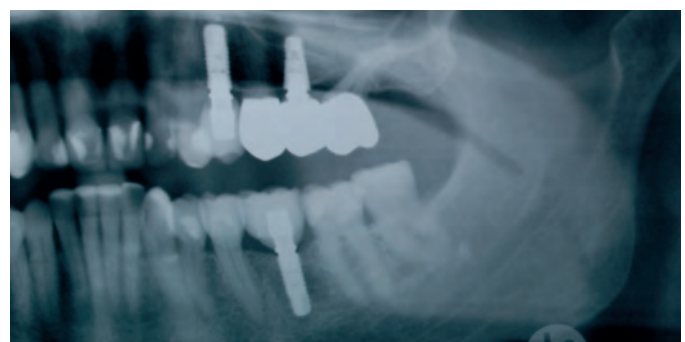

X-ray after 5 Years

### Post Operative



### Follow up 5 years





**MICROCONE**



A Straumann Group Brand

## » Clinical Case «

### Late Implant Placement with Microcone Implant



**Dr. med. dent.  
Lucky Tseng**

**Profile:** L.-Z., Female, 1943 | Taichung, Taiwan

**Clinical Situation:**

- Extraction of 46 and socket preservation with PRF in 08, 2015
- 46, 47 were performed implantation in 11, 2015
- GBR Regain non-mobile mucosa of 46, 47 area and reposition MGJ line using with the BPF technique and atelocollagen sheet in 03, 2016.
- Provisional crowns fabrication to adjust the subgingival contours and cervical lines in 10, 2016.
- Prosthetics: conventional abutment with Full-Zirconia crown restoration.  
(Use new friction-retention system without cement)

- Taichung, Taiwan
- Co-founder Grace Life dental clinic Taiwan
- Visiting staff Shanghai Renkang dental clinic China
- National Defense Medical Center bachelor
- Doctor of Dental Science, West China School of Stomatology, Sichuan University
- Clinical instructor of National Defense Medical Center
- Specialist of Oral and Maxillofacial Surgeons TFDA
- Senior instructor of Association of Asia Reconstructive Dentistry
- Diplomate of the International Congress of Oral Implantologists

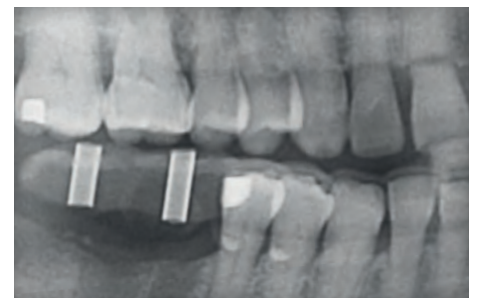
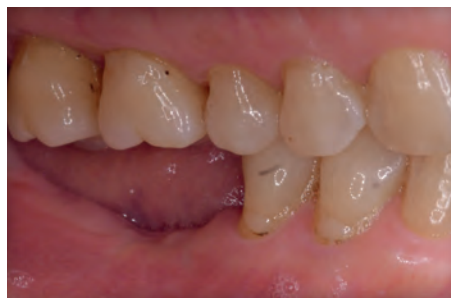**Tooth Extraction**  
08/15

**Implant Placement**  
11/15

**Provisional Restoration**  
03/16

**Final Restoration**  
10/16

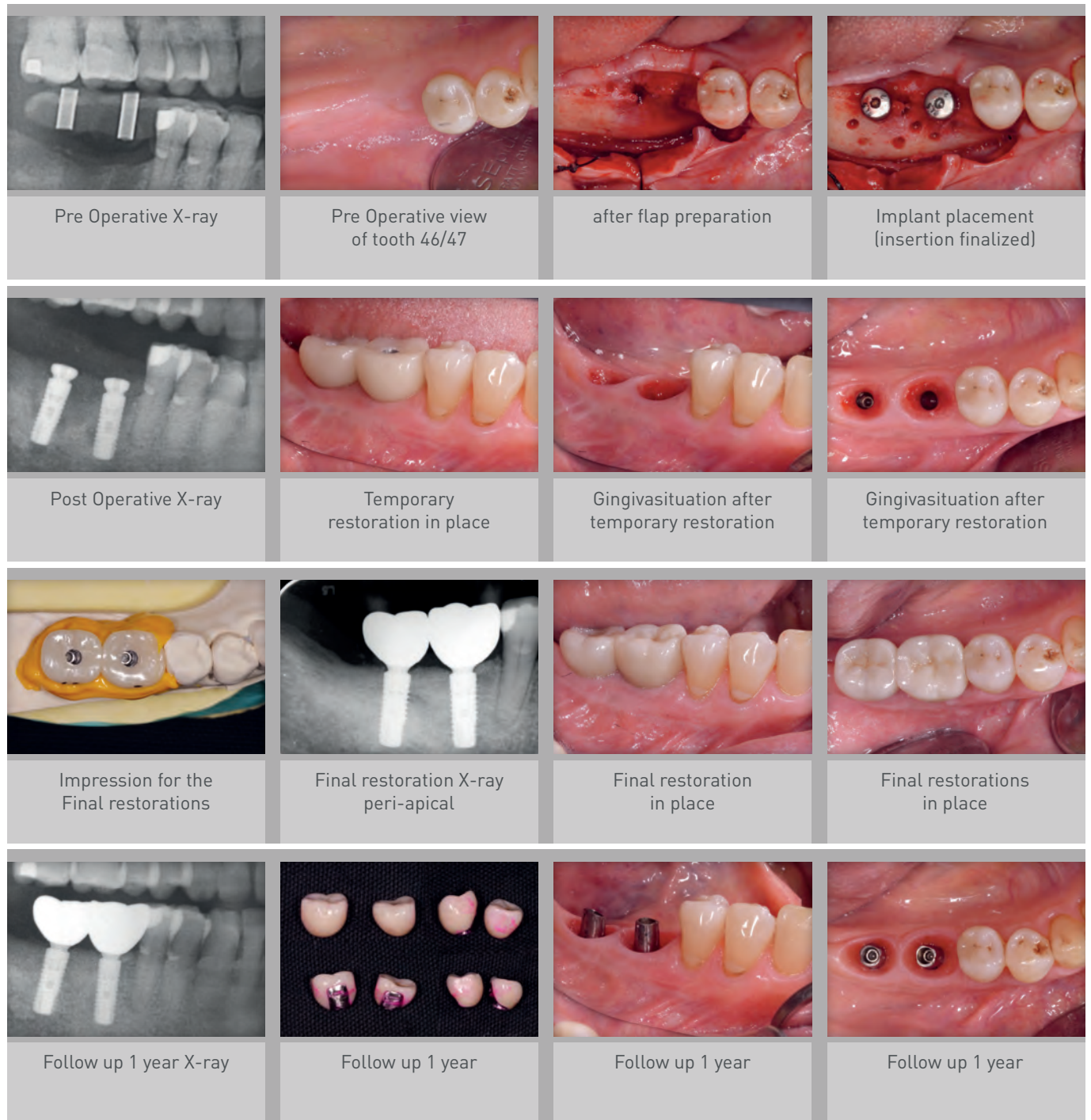
#### Initial Situation



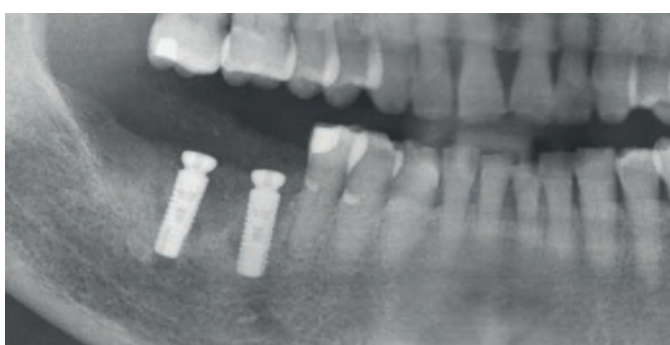
Summary	Loading Protocol (Delayed)		Surgical products	Prosthetic products
Surgical Description	Mandible	Posterior	M-Implant D 4,0 x L 11 mm	Standard abutment Titanium
	2 Implants	Conventional		Full-Zirconia crown
Restorative Solution	Friction retention	Full-Zirconia crown		

# » Clinical Case «

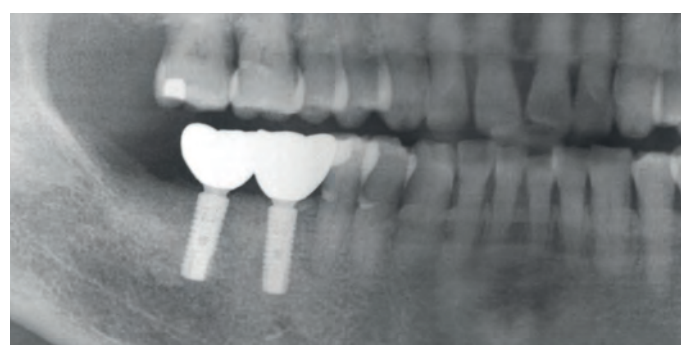
## Late Implant Placement with Microcone Implant



### Post Operative



### Follow up 1 year





**MICROCONE**

» Clinical Case «

**Late Implant Placement with Microcone Implant**



**Dr. Ching-Hsuan, Yang**

**Profile:** W.-q.T., 41 year-old Female | Taichung, Taiwan

**Clinical Situation:** A 41 year-old female asked for restoring the missing teeth of mandibular right first and second molars of 46, 47, where it represented class IV of the Cawood and Howell classification.

- Taipei, Taiwan
- Attending Physicians of Show Chwan Memorial Hospital
- Specialist of Division of Periodontics, Department of Dentistry, Taipei Medical
- China Medical University School of Dentistry bachelor
- Certified by The Association of Family Dentistry R.O.C.
- Member Academy of Oral Implantology Taiwan
- Member Association of Asia Reconstructive Dentistry

**Tooth Extraction**



**Implant Placement**

05/15



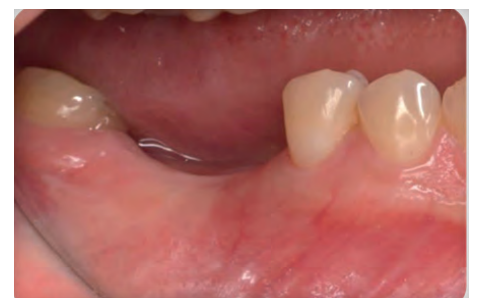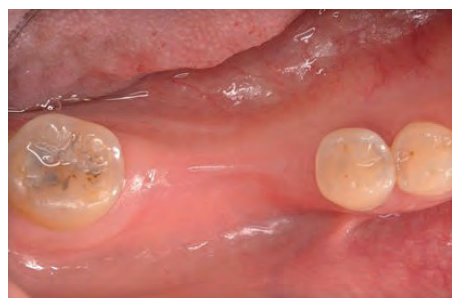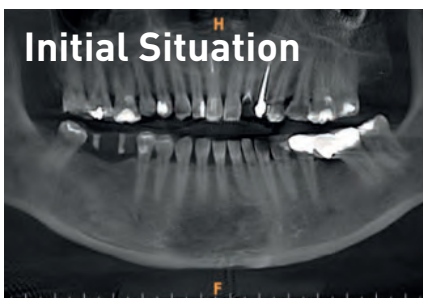**Provisional Restoration**

10/15



**Final Restoration**

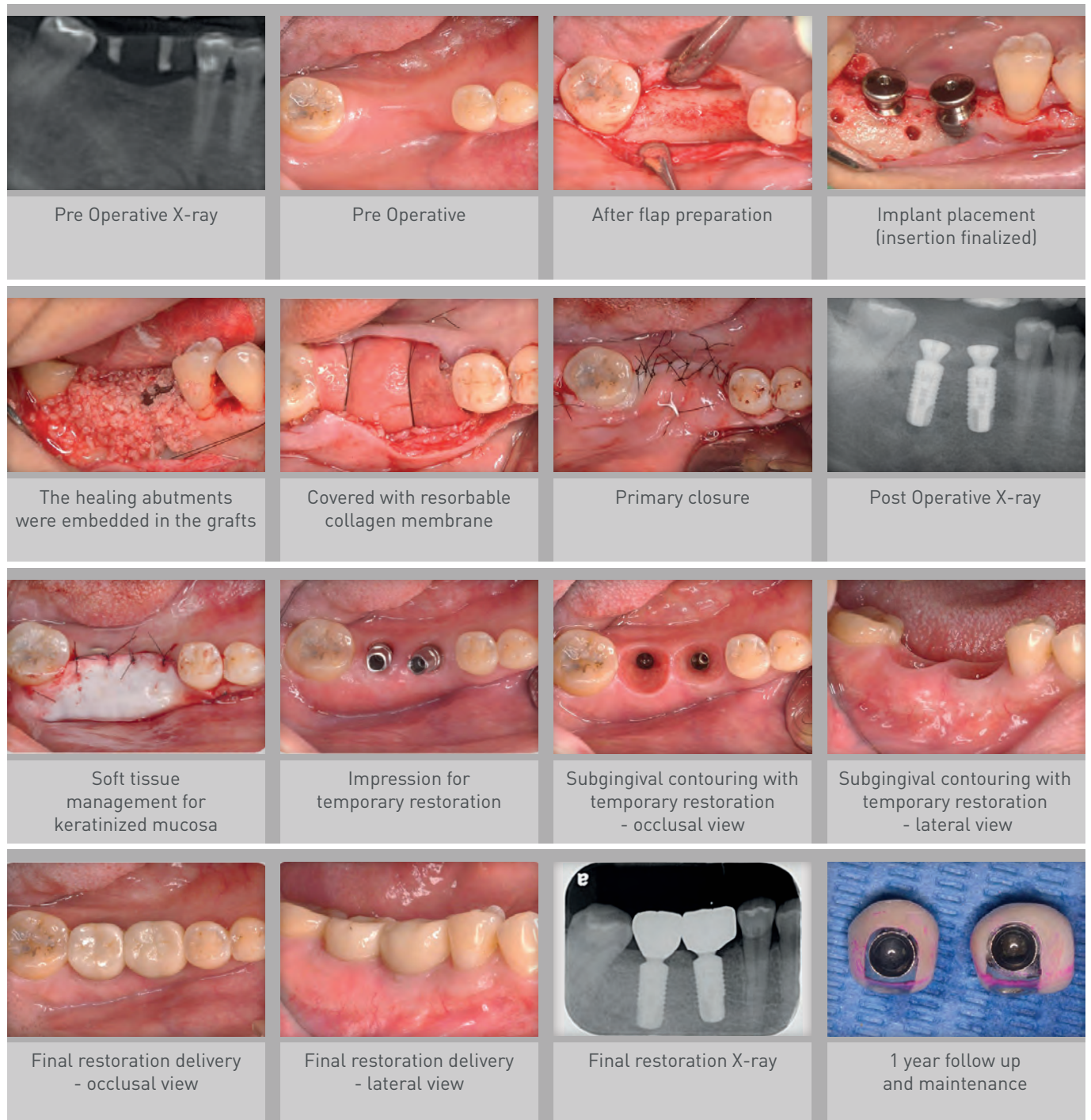
09/16



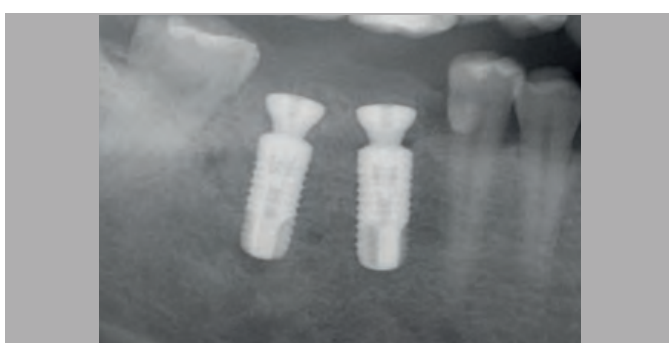Summary	Loading Protocol (Delayed)		Surgical products	Prosthetic products
Surgical Description	Mandibula	Posterior	D 5,0 x L 11 mm	Standard abutment Titanium D 5,5 x L 1,5 mm
	2 Implants	Conventional		
Restorative Solution	Conventional	Dental Material		

# »» Clinical Case ««

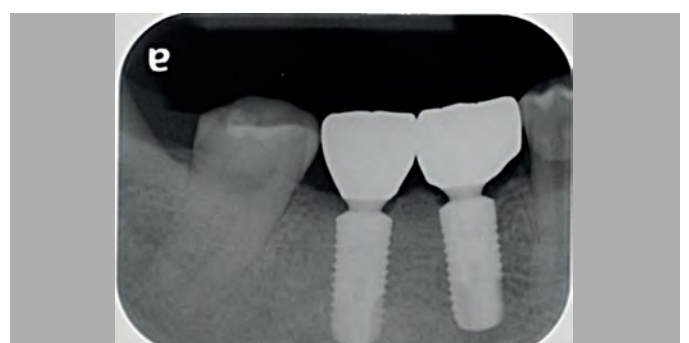
## Late Implant Placement with Microcone Implant



### Post Operative



### Follow up 3 years





**MICROCONE**



A Straumann Group Brand

## » Clinical Case «

### Late Implant Placement with Microcone Implant



**Dr. Shih pin Yang**

**Profile:** H.C., Female, 48 years | Tainan, Taiwan

**Clinical Situation:** 14 narrow alveolar ridge, 16 insufficient bone height for implant placement. Arrange 14 GBR and 16 sinus lift surgery.

- Restorative Solution: 13,17 crowns, 14-16 implant support fixed partial denture

- Tainan, Taiwan
- Kaohsiung Medical University bachelor
- Diploma of Taiwan Academy of Periodontology
- Attending Physicians of National Cheng Kung University Hospital
- Member of Association of Asia Reconstructive Dentistry

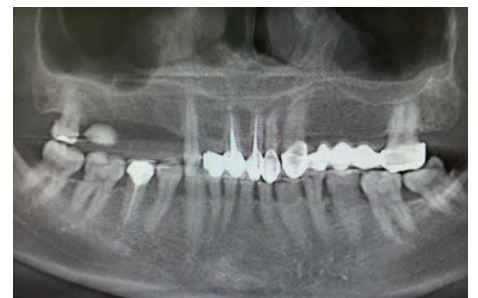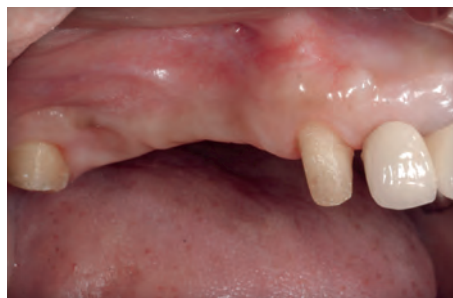**Tooth Extraction**  
03/15

**Implant Placement**  
03/16 11/16

**Provisional Restoration**  
04/17

**Final Restoration**  
09/17

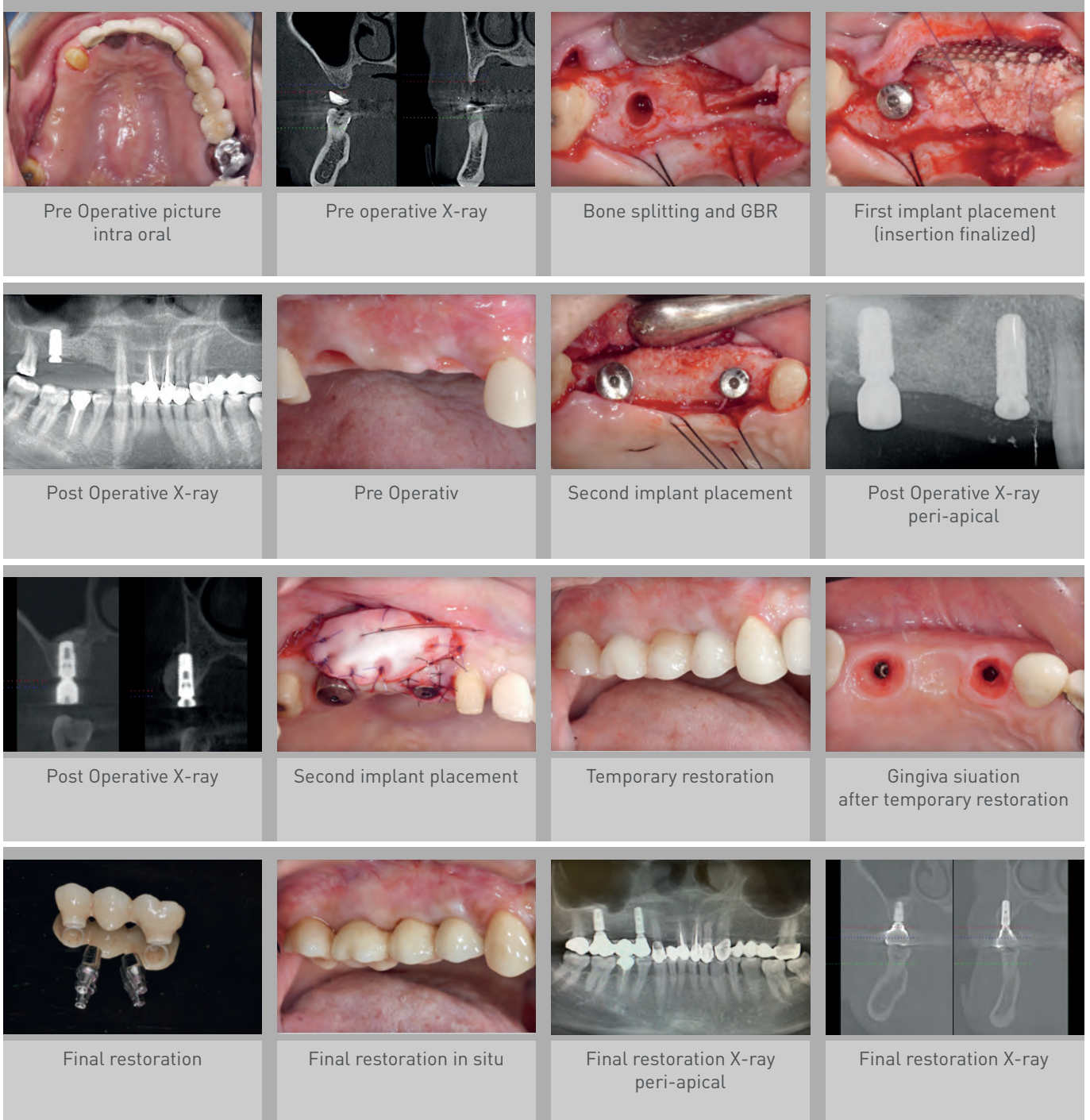
#### Initial Situation



Summary	Loading Protocol (Delayed)		Surgical products	Prosthetic products
Surgical Description	Maxilla	Posterior	D 4,5 x L 9 mm	Titanium abutment
	2 Implants	Guided	D 4,0 x L 11 mm	Full-Zirconia crown
Restorative Solution	CADCAM	Zirconia		

# » Clinical Case «

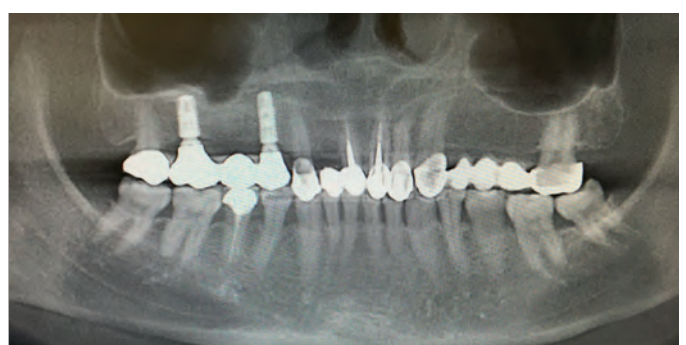## Late Implant Placement with Microcone Implant



### Post Operative



### Final Restoration







**MICROCONE**

## » Clinical Case «

### Late Implant Placement with Microcone Implant



**Dr. med. dent.,  
prosthodontist  
Raimondas  
Savickas**

**Profile:** M.R., Female, 53 years | Vilnius, Lithuania

**Clinical Situation:** Teeth 24, 23, 34, 43 were extracted because of caries and periodontal disease in another clinic 3 month ago.

- Implantation in the reg. of 14, 12, 22, 24, 34, 32, 42, 44 tooth.
- After 3 month closed healing, opening and fixation of MedentiBASE abutments.
- Extraction of 16, 11, 21, 33 tooth because of periodontal disease; same day fixation of CAD/CAM temporary bridge on implants.
- 2 month healing.
- Restorative Solution: CAD/CAM Zirconium oxide screw retained dentures.

- Vilnius, Lithuania
- Lecturer in prosthodontics since 2001
- Lecturer in dental implantology since 2006
- Co-founder Protezavimo – Implantavimo Klinika

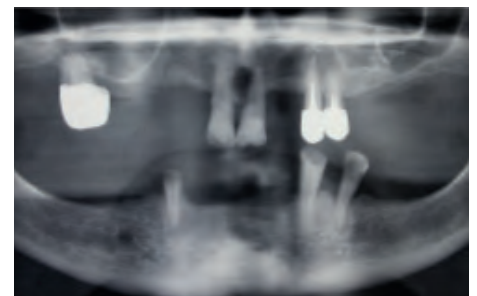
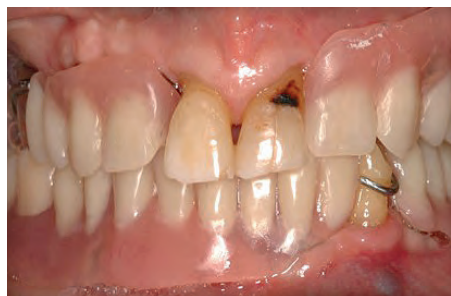**Tooth Extraction**  
02/15

**Implant Placement**  
05/15

**Provisional Restoration**  
09/15

**Final Restoration**  
11/15

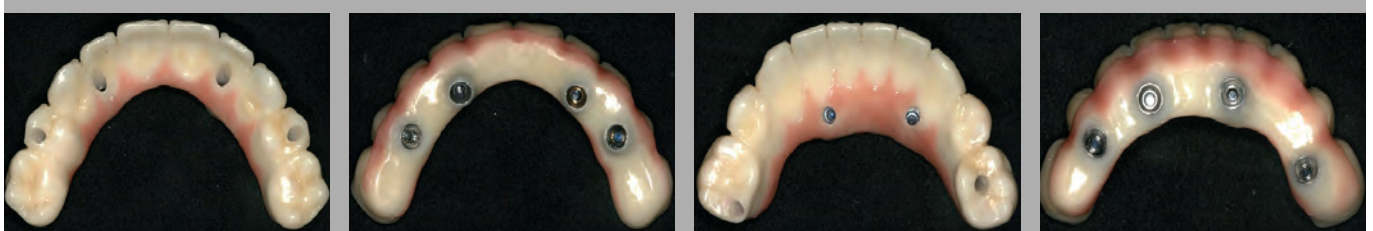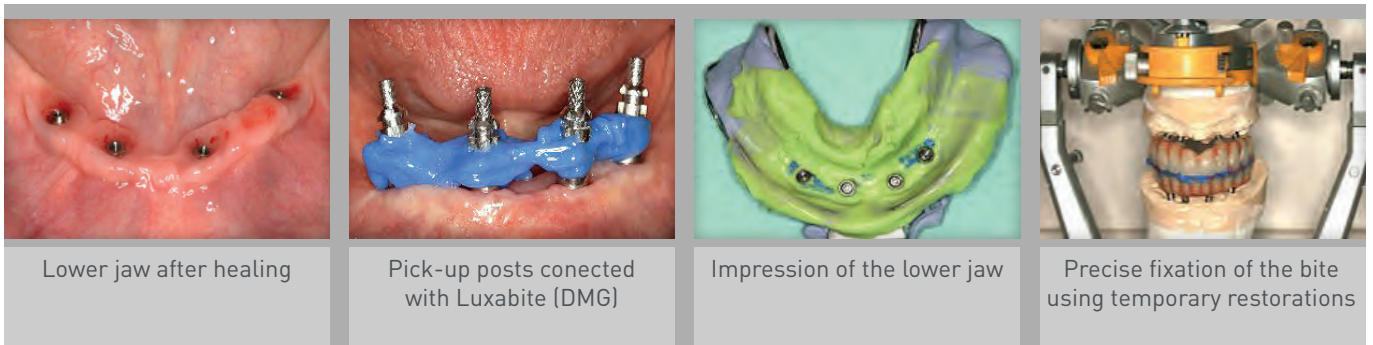
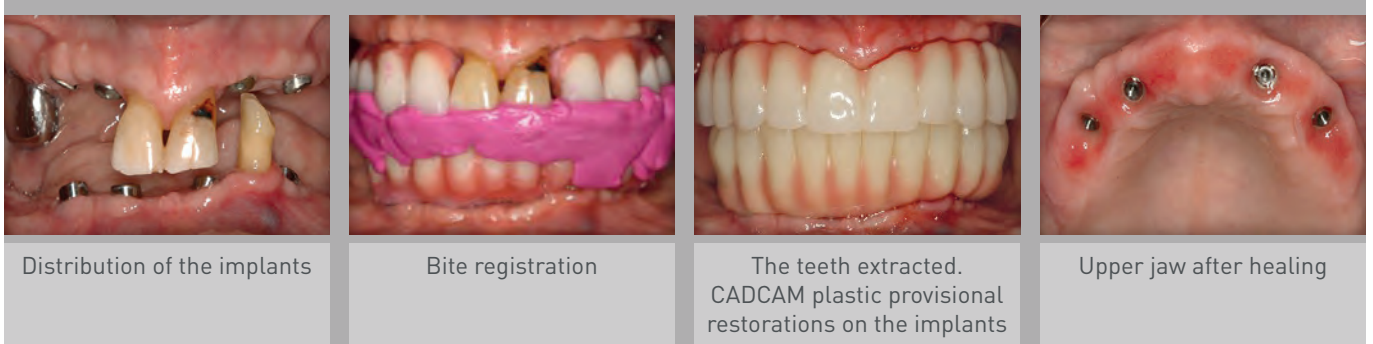#### Initial Situation



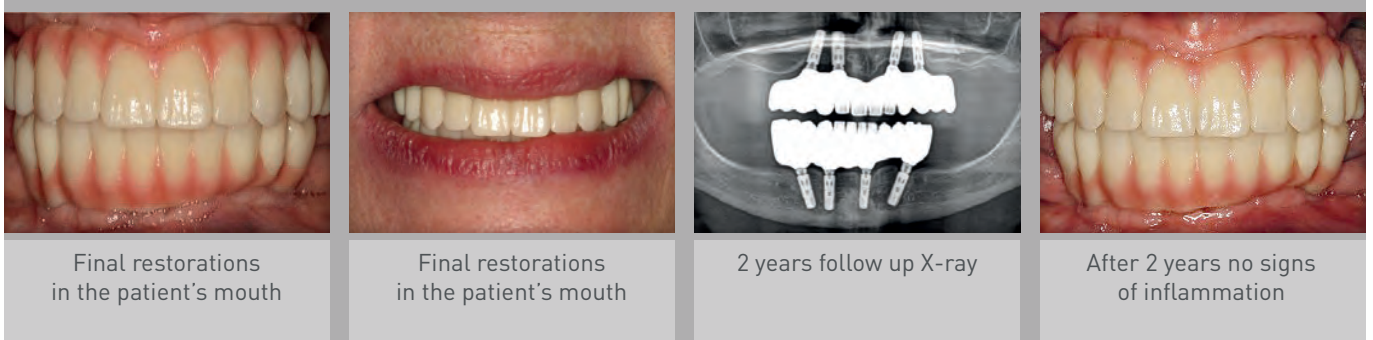
Summary	Loading Protocol (Delayed)		Surgical products	Prosthetic products
Surgical Description	Maxilla and Mandibula	Anterior and Posterior	MC Implants D 4,0 x L 11 mm	MedentiBASE abutments
	8 Implants	Conventional		MedentiBASE titanium caps
Restorative Solution	CAD/CAM	Zirconium oxide	Zirconium oxide FD	

# » Clinical Case «

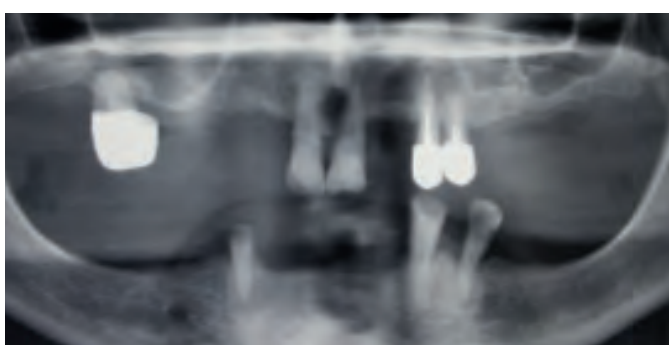## Late Implant Placement with Microcone Implant



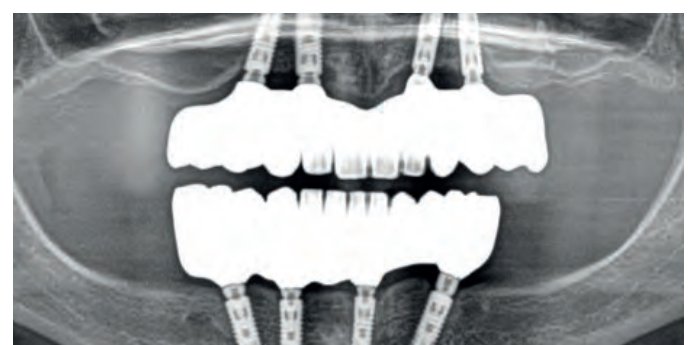Final restorations CAD/CAM  
Zirconium oxide screw retained FD



### Initial Situation



### Follow up 2 years





Herausgeber: MEDENTIKA® GmbH  
Hammweg 8-10  
76549 Hügelsheim  
Tel: +49 (0)7229 69912-10  
info@medentika.de  
www.medentika.com

Gestaltung: Der WeberFink GbR  
Büro für grafische Gestaltung  
www.weberfink.de

Stand: Oktober 2018

Wir sind zertifiziert nach:  
**DIN EN ISO 13485**  
**Medizinprodukterichtlinie 93/42/EEC,**  
**Anhang II**

**CE0483**

Technische Änderungen und Irrtümer vorbehalten.

Die Gebrauchsanweisungen und Garantiebedingungen finden Sie auf der Internetseite [www.medentika.com](http://www.medentika.com).

Mehr Informationen zur Garantie können auch direkt beim Hersteller angefordert werden.

MEDENTiKA® GmbH  
Hammweg 8-10  
76549 Hügelshheim  
info@medentika.de  
www.medentika.com

» **Passion** «  
for precision «